

# Essentials of MEDICAL PARASITOLOGY





# Essentials of MEDICAL PARASITOLOGY

**Apurba Sankar Sastry** MD (JIPMER), DNB, MNAMS, PDCR

Assistant Professor

Department of Microbiology

Jawaharlal Institute of Postgraduate Medical Education & Research (JIPMER)

Pondicherry, India

**Sandhya Bhat K** MD, DNB, MNAMS, PDCR

Assistant Professor

Department of Microbiology

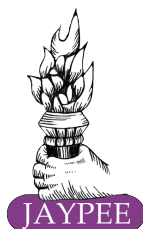Pondicherry Institute of Medical Sciences (PIMS)

(A Unit of Madras Medical Mission)

Pondicherry, India

## *Foreword*

Reba Kanungo



---

**JAYPEE BROTHERS MEDICAL PUBLISHERS (P) LTD**

**New Delhi • London • Philadelphia • Panama**



## Jaypee Brothers Medical Publishers (P) Ltd

### Headquarters

Jaypee Brothers Medical Publishers (P) Ltd  
4838/24, Ansari Road, Daryaganj  
New Delhi 110 002, India  
Phone: +91-11-43574357  
Fax: +91-11-43574314  
Email: [jaypee@jaypeebrothers.com](mailto:jaypee@jaypeebrothers.com)

### Overseas Offices

J.P. Medical Ltd  
83 Victoria Street, London  
SW1H 0HW (UK)  
Phone: +44-2031708910  
Fax: +02-03-0086180  
Email: [info@jpmedpub.com](mailto:info@jpmedpub.com)

Jaypee Medical Inc.  
The Bourse  
111 South Independence Mall East  
Suite 835, Philadelphia, PA 19106, USA  
Phone: +1 267-519-9789  
Email: [joe.rusko@jaypeebrothers.com](mailto:joe.rusko@jaypeebrothers.com)

Jaypee Brothers Medical Publishers (P) Ltd  
Bhotahity, Kathmandu, Nepal  
Phone: +977-9741283608  
Email: [kathmandu@jaypeebrothers.com](mailto:kathmandu@jaypeebrothers.com)

Website: [www.jaypeebrothers.com](http://www.jaypeebrothers.com)  
Website: [www.jaypeedigital.com](http://www.jaypeedigital.com)

© 2014, Jaypee Brothers Medical Publishers

The views and opinions expressed in this book are solely those of the original contributor(s)/author(s) and do not necessarily represent those of editor(s) of the book.

All rights reserved. No part of this publication may be reproduced, stored or transmitted in any form or by any means, electronic, mechanical, photocopying, recording or otherwise, without the prior permission in writing of the publishers.

All brand names and product names used in this book are trade names, service marks, trademarks or registered trademarks of their respective owners. The publisher is not associated with any product or vendor mentioned in this book.

Medical knowledge and practice change constantly. This book is designed to provide accurate, authoritative information about the subject matter in question. However, readers are advised to check the most current information available on procedures included and check information from the manufacturer of each product to be administered, to verify the recommended dose, formula, method and duration of administration, adverse effects and contraindications. It is the responsibility of the practitioner to take all appropriate safety precautions. Neither the publisher nor the author(s)/editor(s) assume any liability for any injury and/or damage to persons or property arising from or related to use of material in this book.

This book is sold on the understanding that the publisher is not engaged in providing professional medical services. If such advice or services are required, the services of a competent medical professional should be sought.

Every effort has been made where necessary to contact holders of copyright to obtain permission to reproduce copyright material. If any have been inadvertently overlooked, the publisher will be pleased to make the necessary arrangements at the first opportunity.

**Inquiries for bulk sales may be solicited at:** [jaypee@jaypeebrothers.com](mailto:jaypee@jaypeebrothers.com)

### *Essentials of Medical Parasitology*

*First Edition: 2014*

ISBN: 978-93-5152-329-1

*Printed at*

## **Dedicated to**

*Our Beloved Parents, Family members*

*And above all the Almighty*

*“Life is the most difficult exam. Many fail because they tend to copy others  
Not realizing that everyone has different question paper.”*



# Foreword

---

Our understanding of human diseases has been greatly benefited from the rapid strides made in Medical Science. It is necessary to compile and document these advances in textbooks for students who are pursuing medical and allied courses. To add the existing resources of information on parasitic diseases, Dr Apurba Sankar Sastry and Dr Sandhya Bhat k have conceptualized and compiled this book entitled “Essentials of Medical Parasitology.” They have addressed details of information required by a medical graduate to help him to understand the subject and also keep abreast with latest developments in the field of Medical Parasitology.



The book is divided into four sections that deal with Protozoa, Helminths, etc that are of importance to human health and disease. Each section deals with general concepts including commonly used terminologies and their definitions which will help the reader to understand their implications when used later in the text. Every chapter is designed in a thematic manner with a brief classification including classification based on the habitat and site of infection. This is followed by description of the parasite's morphology, epidemiology of the disease and pathogenesis. Clinical spectrum of the disease is described with emphasis on pathology, clinical features and stages of the parasite that are encountered in the human host. Life cycle outside the human host and natural habitat in the environment or animals have been explained in detail in the respective chapter.

These chapters are interspersed with relevant illustrations. Photomicrographs are clear emphasizing the natural appearance in clinical material. Diagrams and flow charts of life cycles are clear and well represented. The authors have collected original images from several sources to highlight the actual microscopic images seen in the laboratory and in situ appearance in tissue sections.

Laboratory methods to detect the agents in relevant clinical material have been described in detail in easy procedural steps. Several additional and supportive tests to diagnose the infections have been mentioned in each chapter. Recent techniques and current tests including specific antigen and antibody detection methods used in the laboratories have been described. This will help a fresh graduate in clinical practice to use the information in day to day practice.

An interesting feature in each chapter is the preventive aspect of commonly encountered parasitic diseases, with a note on vaccination. An additional feature of the book is an up-to-date information on the parasitic diseases of public health importance in India including national programs for prevention and control. Opportunistic parasitic infections in the immunocompromised patients including HIV infected individuals have been described along with the specific indicators for detection.

Each chapter ends with a set of self assessment questions which will help a student to prepare for the examination. This is a well planned and executed parasitology book which both MBBS undergraduate students and postgraduates pursuing a course in Medical Microbiology will find useful. I congratulate the authors for bringing out this comprehensive textbook on parasitology.

**Reba Kanungo MD PhD**

Dean Research and Professor and Head  
Department of Clinical Microbiology  
Pondicherry Institute of Medical Sciences  
Puducherry

*Past President, Indian Association of Medical Microbiologists  
Former Editor-in-Chief, Indian Journal of Medical Microbiology  
E-mail: reba.kanungo@gmail.com*



# Preface

---

Medical parasitology is an interdisciplinary science that deals with the study of animal parasites which infect and produce diseases in human beings. This book is designed specifically for undergraduate medical and paramedical students as well as for postgraduate students.

Medical students always complain that there is no standard Indian textbook on parasitology at present which can fulfil the need of the examination and for the management of the parasitic diseases.

Currently available Indian medical parasitology books are neither updated with recent advances nor presented in a student-friendly manner. Day-to-day developments in the field of parasitology and the unavailability of a standard textbook fulfilling the needs and expectation of the students, motivated us to write a book in an updated format with recent epidemiological data, laboratory techniques, treatment strategies, etc in such a way that student can grasp it easily.

The whole content of the book has been arranged in a bulleted format and use of sub heads has increased the readability. Entire book is divided into four sections—General introduction, Protozoology, Helminthology and Miscellaneous. At the end, six appendices have been incorporated which will be of immense use and initiate interest among the students. Expected questions including MCQs have been added at the end of each chapter which will help to reinforce and understand the related topic in a better way. Life cycles are drawn in lucid and easy-to-grasp manner, exactly according to the text. Real microscopic images of parasites and specimens from various sources are being incorporated to correlate their impressions with the related parasitic diseases. Laboratory diagnosis and treatment boxes are introduced as a different entity for a quick review for students as well as for physicians. Our endeavor will be successful, if the book is found to be useful for student as well as for the faculty.

**Apurba Sankar Sastry**  
(drapurbasastry@gmail.com)

**Sandhya Bhat K**  
(sandhyabhatk@gmail.com)





# Acknowledgments

---

## **ACKNOWLEDGEMENT FOR CONTRIBUTING THE FIGURES**

At the very outset, we express our deepest sense of gratitude to all who have given consent to provide their valuable photographs.

## **SINCERE ACKNOWLEDGEMENTS FOR HELPING IN MANUSCRIPT PREPARATION:**

This book would have never seen the light without the immeasurable generosity of the following people who guided, supported and stood by us throughout the journey of manuscript preparation.

- Dr Anand Janagond, Associate Professor, Dept. of Microbiology, Velammal Medical College, Madurai, for his valuable suggestions during the manuscript preparation.
- Dr Sharadadevi Mannur, Associate Professor, Dept. of Microbiology, Sri Siddhartha Medical College, Tumkur, karnataka for helping in the correction of the manuscript.
- Dr Rudresh Shoorashetty Manohar, Assistant Professor, Dept. of Microbiology, ESIC Medical College, Bangalore in helping the preparation of Trematode chapter manuscript.
- Dr Pranay Panigrahi, Post graduate student (Surgery), MkCG Medical college, Berhampur, Orissa, for helping in the correction of the manuscript
- Dr S. Sujatha, Professor, Dept. of Microbiology, JIPMER for her valuable suggestions during the initial manuscript preparation.
- Dr Rahul Dhodapkar, Associate Professor, Dept. of Microbiology, JIPMER for his valuable suggestions during the initial manuscript preparation.
- Mr kaviyaran and Ms Rajeswari, Meenakshi Medical College, Chennai for their help in drawing few schematic diagrams.

## **SPECIAL ACKNOWLEDGEMENTS TO OUR PUBLISHERS:**

### **(Jaypee Brothers Medical Publishers (P) Ltd)**

- Shri Jitendar P Vij (Group Chairman)
- Mr Ankit Vij (Group President)
- Mr Bhupesh Arora (Associate Director Marketing and GM Publishing)
- Dr Sakshi Arora (Chief Development Editor)
- Mrs Nitasha Arora and Dr Mrinalini Bakshi (Editors)
- Mrs Seema Dogra (Senior Designer)
- Mr Phool kumar, Mr Sachin Dhawan, Mr Shekhar Bhatt and Mr Neeraj Choudhary (Operators and Designer)

## **HEARTY ACKNOWLEDGEMENTS TO DEPARTMENT STAFFS AND RELATIVES FOR THEIR BLESSING AND SUPPORT**

- Dr. Reba kanungo, Dean Research, Professor and Head, Department of Clinical Microbiology, Pondicherry Institute of Medical Sciences (PIMS) for giving the foreword.
- Dr TS Ravikumar, Director, JIPMER
- Dr John Abraham, Director-Principal, Pondicherry Institute of Medical Sciences (PIMS)
- JIPMER, Department of Microbiology Faculty:
  - Dr S Badrinath, Project consultant, Ex Professor and Head
  - Dr SC Parija, Dean Research, Ex Professor and Head

- Dr BN Harish, Professor and Head
  - Dr S Sujatha, Professor
  - Dr Jharna Mandal, Associate Professor
  - Dr Rakesh Singh, Associate Professor
  - Dr Rahul Dhodapkar, Associate Professor
  - Dr Rakhi Biswas, Assistant Professor
  - Dr Noyal M Joseph, Assistant Professor
  - Dr Hitender Gautam, Assistant Professor
- Pondicherry Institute of Medical Sciences (PIMS), Department of Microbiology Faculty:
  - Dr Reba kanungo, Dean Research and Professor & Head
  - Dr Shashikala, Professor
  - Dr Sheela Devi, Professor
  - Dr Esther Paul, Associate Professor
  - Dr Jhony Asir, Assistant Professor
  - Dr P Vivian Joseph, Assistant Professor
  - Dr Sujitha V, Assistant Professor
  - Dr Anandhalakshmi, Assistant Professor
  - Ms SM Shanthi, Tutor
  - Mrs Desdemona Rasitha, Tutor
- JIPMER, Department of Microbiology: Residents, PhD scholars, technicians and non teaching staff.
- Pondicherry Institute of Medical Sciences (PIMS), Department of Clinical Microbiology — PG students, technicians and non teaching staff
- Meenakshi Medical College, Chennai, Department of Microbiology staffs — Dr Amshavathani (Professor and HOD), Dr Senthamarai (Associate Professor), Dr Sivasankari (Associate Professor), Dr kumudavathi (Tutor) and Dr Anitha (Assistant Professor)
- ESIC Medical College and PGIMSR, Chennai, Department of Microbiology staffs and residents
- Sri Siddhartha Medical College, Tumkur, karnataka, Department of Microbiology staffs-
  - Dr ER Nagaraj, Professor and Head
  - Dr Sharadadevi Mannur, Associate Professor
  - Dr Renushree, Associate Professor
- Our friends: Dr Godfred, Mr Sisir, Dr Sadia, Dr Srinivas, Dr Chaya, Dr Manisa, Dr Ira
- All maternal and paternal relatives and cousins

Last, but not the least, we want to thank the Almighty for bestowing all his blessings.

# Contents

---

## Section 1: Introduction

### Chapter 1: General Introduction To Parasitology

3–15

- Taxonomy of parasites 3
- Parasite 3
- Host 4
- Host-parasite relationship 4
- Transmission of parasites 5
- Life cycle of the parasites 6
- Pathogenesis of parasitic diseases 6
- Immunology of parasitic diseases 8
- Laboratory diagnosis of parasitic diseases 9
- Treatment of parasitic diseases 10

## Section 2: Protozoology

### Chapter 2: Introduction to Protozoa

19–23

- General features of protozoa 19
- Classification of protozoa 19

### Chapter 3: Amoeba

24–48

- Classification of amoeba 24
- Intestinal amoeba 24
  - Pathogenic intestinal amoeba 24
    - Entamoeba histolytica 24
  - Nonpathogenic intestinal amoeba 35
    - Entamoeba dispar 35
    - Entamoeba moshkovskii 36
    - Entamoeba coli 36
    - Entamoeba hartmanni 38
- Entamoeba gingivalis 38
- Entamoeba polecki 39
- Endolimax nana 39
- Iodamoeba butschlii 39
- Free-living (opportunistic) amoeba 40
  - Naegleria fowleri 40
  - Acanthamoeba species 43
  - Balamuthia mandrillaris 46
  - Sappinia diploidea 47

### Chapter 4: Flagellates—I (Intestinal and Genital)

49–62

- Classification of flagellates 49
- Giardia lamblia 50
- Trichomonas vaginalis 55
- Pentatrichomonas hominis 58
- Trichomonas tenax 58
- Chilomastix mesnili 58
- Enteromonas hominis 59
- Retortamonas intestinalis 60
- Dientamoeba fragilis 60

## Chapter 5: Flagellates—II (Hemoflagellates)

63–89

- Introduction 63
- Morphology of hemoflagellates 63
- Leishmania 64
  - Old World Leishmaniasis 64
    - Leishmania donovani 64
    - Leishmania tropica complex 74
  - New World Leishmaniasis 76
    - Leishmania mexicana complex 77
    - Leishmania viannia braziliensis complex 77
    - Leishmania leishmania chagasi 78
- Trypanosoma 79
  - Trypanosoma cruzi 79
  - Trypanosoma brucei complex 85

## Chapter 6: Sporozoa—I (Malaria and Babesiosis)

90–117

- Classification 90
- Malaria parasite 90
- Babesia 114

## Chapter 7: Sporozoa—II (Opportunistic Coccidian Parasites)

118–139

- Introduction 118
- Toxoplasma gondii 118
- Cryptosporidium parvum 126
- Cyclospora cayetanensis 131
- Isospora belli 133
- Sarcocystis species 135

## Chapter 8: Miscellaneous Protozoa

140–150

- Microsporidium species 140
- Balantidium coli 146
- Blastocystis hominis 149

## Section 3: Helminthology

### Chapter 9: Introduction to Helminths

153–155

- General characteristics 153
- Morphology 154
- Life cycle 155

### Chapter 10: Cestodes

156–189

- General characteristics of cestodes 156
  - Classification of cestodes 156
  - Morphology of cestodes 157
- Pseudophyllidean cestodes 160
  - Diphylobothrium species 160
  - Spirometra species 163
- Cyclophyllidean cestodes 165
  - Taenia species 165, 175
  - Echinococcus species 176
  - Hymenolepis nana 184, 186
  - Dipylidium caninum 187

**Chapter 11: Trematodes or Flukes****190–219**

- Classification of trematodes 190
- General characteristics of trematodes 191
- Blood flukes 193
  - *Schistosoma* species 194, 201, 202
- Liver fluke 202
  - *Fasciola* species 202, 206
  - *Clonorchis* species 206
  - *Opisthorchis* species 208, 210
- Intestinal fluke 210
  - *Fasciolopsis* species 210
  - *Gastrodiscoides* species 213
  - *Watsonius* species 213
  - *Heterophyes* species 214
  - *Metagonimus* species 214
  - *Echinostoma* species 214
  - Lung fluke 215
  - *Paragonimus* species 215

**Chapter 12: Nematodes—I (Intestinal Nematodes)****220–247**

- General properties of nematodes 220
- Classification 220
- General description 221
- Large intestinal nematodes 224
  - *Trichuris trichiura* 224
  - *Enterobius vermicularis* 227
- Small intestinal nematodes 230
  - Hookworm 230
  - *Strongyloides* species 237, 242
  - *Ascaris* species 242, 246

**Chapter 13: Nematodes—II Nematodes of Lower Animals that Rarely Infect Man****248–261**

- Classification 248
- Larva migrans 248
- Toxocariasis 250
- *Angiostrongylus* species 252
- *Baylisascaris procyonis* 253
- *Lagochilascaris minor* 253
- Anisakiasis 253
- *Gnathostoma* species 254
- *Capillaria* species 255, 256, 257
- *Trichostrongylus* species 257
- *Diectophyme renale* 258
- *Oesophagostomum* species 259
- *Ternidens deminutus* 259
- *Mammomonogamus laryngeus* 260
- *Thelazia* species 260

**Chapter 14: Nematodes—III (Somatic Nematodes)****262–289**

- Classification 262
- Filarial nematode 262
- Lymphatic filarial nematodes 265
  - *Wuchereria bancrofti* 265
  - *Brugia speices* 274, 275
- Other filarial nematodes 276
  - *Loa loa* 276
  - *Onchocerca volvulus* 277
  - *Mansonella* species 280, 281
  - *Dirofilaria* species 282
- Other Somatic nematodes 282
  - *Dracunculus medinensis* 282
  - *Trichinella spiralis* 285

## Section 4: Miscellaneous

### Chapter 15: Laboratory Diagnosis of Parasitic Diseases

293–313

- Introduction 293
- Morphological identification techniques 293
- Culture techniques in parasitology 303
- Immunodiagnostic methods 307
- Molecular methods 309
- Intradermal skin tests 310
- Xenodiagnostic techniques 311
- Animal inoculation methods 311
- Imaging techniques 311

### Chapter 16: Medical Entomology

314–321

- Medical entomology 314
- Vector 314
- Class insecta 314
- Class arachnida 319
- Class crustacea 320
- Control of Arthropods 320

## Appendices

325–333

- **Appendix I**  
Clinical syndromes in parasitology 325
- **Appendix II**  
Common tropical parasitic diseases 327
- **Appendix III**  
Romanowsky stains, composition and staining procedures 327
- **Appendix IV**  
Laboratory-acquired parasitic infections 329
- **Appendix V**  
Biomedical waste management in parasitology 330
- **Appendix VI**  
Morphological forms of parasites seen in the fecal sample 331

## Index

335–341

# Section 1

---

## Introduction

**Chapter 1** General Introduction: Parasitology





# 1

# General Introduction: Parasitology

## Chapter Outline

- Taxonomy of parasites
- Parasite
- Host
- Host-parasite relationship
- Transmission of parasites
- Life cycle of the parasites
- Pathogenesis of parasitic diseases
- Immunology of parasitic diseases
- Laboratory diagnosis of parasitic diseases
- Treatment of parasitic diseases
- Expected questions

**Medical Parasitology** deals with the study of animal parasites, which infect and produce diseases in human beings.

## TAXONOMY OF PARASITES

According to the binomial nomenclature as suggested by Linnaeus, each parasite has two names: a genus and a species name.

These names are either derived from: names of their discoverers, Greek or Latin words of the geographical area where they are found, habitat of the parasite, or hosts in which parasites are found and its size and shape.

All parasites are classified under the following taxonomic units—the kingdom, subkingdom, phylum, subphylum, super class, class, subclass, order, suborder, super family, family, genus and species.

The generic name of the parasite always begins with an initial capital letter and

species name with an initial small letter, e.g., *Entamoeba histolytica*.

## PARASITE

Parasite is a living organism, which lives in or upon another organism (host) and derives nutrients directly from it, without giving any benefit to the host.

Protozoa and helminths (animal parasites) are studied in Medical Parasitology.

Parasites may be classified as:

- **Ectoparasite:** They inhabit the surface of the body of the host without penetrating into the tissues. They are important vectors transmitting the pathogenic microbes. The infection by these parasites is called as **infestation**, e.g., fleas or ticks
- **Endoparasite:** They live within the body of the host (e.g., *Leishmania*). Invasion by the endoparasite is called as **infection**.

The endoparasites are of following types:

- **Obligate parasite:** They cannot exist without a parasitic life in the host (e.g., *Plasmodium* species)
- **Facultative parasite:** They can live a parasitic life or free-living life, when the opportunity arises (e.g., *Acanthamoeba*)
- **Accidental parasite:** They infect an unusual host (e.g., *Echinococcus granulosus* infect humans accidentally)
- **Aberrant parasite or wandering parasite:** They infect a host where they cannot live or develop further (e.g., *Toxocara* in humans).

## ■ HOST

Host is defined as an organism, which harbors the parasite and provides nourishment and shelter.

Hosts may be of the following types:

- **Definitive host:** The host in which the adult parasites replicate sexually (e.g., anophelid species), is called as definitive host. The definitive hosts may be human or nonhuman living things
- **Intermediate host:** The host in which the parasite undergoes asexual multiplication is called as intermediate host. (e.g., in malaria parasite life cycle, humans are the intermediate hosts)
  - Intermediate hosts are essential for the completion of the life cycle for some parasites
  - Some parasites require two intermediate hosts to complete their different larval stages. These are known as the first and second intermediate hosts respectively (e.g., Amphibian snails are the first intermediate host and aquatic plants are the second intermediate host for *Fasciola hepatica*)

Hosts can also be:

- **Reservoir host:** It is a host, which harbours the parasites and serves as an important

source of infection to other susceptible hosts. (e.g., dog is the reservoir host for cystic echinococcosis)

- **Paratenic host:** It is the host, in which the parasite lives but it cannot develop further and not essential for its life cycle is known as paratenic host (e.g., fresh water prawn for *Angiostrongylus cantonensis*, big suitable fish for plerocercoid larva of *Diphyllbothrium latum* and freshwater fishes for *Gnathostoma spinigerum*). It functions as a transport or carrier host
- **Amplifier host:** It is the host, in which the parasite lives and multiplies exponentially.

## ■ HOST-PARASITE RELATIONSHIP

The relationship between the parasite and the host, may be divided into the following types:

- **Symbiosis:** It is the close association between the host and the parasite. Both are interdependent upon each other that one cannot live without the help of the other. None of them suffer any harm from each other
- **Commensalism:** It is an association in which the parasite only derives the benefit without causing any injury to the host. A commensal is capable of living an independent life
- **Parasitism:** It is an association in which the parasite derives benefit from the host and always causes some injury to the host. The host gets no benefit in return.

**Disease:** The disease is the clinical manifestation of the infection, which shows the active presence, and replication of the parasite causing damage to the host. It may be mild, severe and fulminant and in some cases may even cause death of the host.

**Carrier:** The person who is infected with the parasite without any clinical or sub clinical disease is referred to as a **carrier**. He can transmit the parasites to others.

## ■ TRANSMISSION OF PARASITES

It depends upon:

- Source or reservoir of infection
- Mode of transmission.

### Sources of Infection

- **Man:** Man is the source or reservoir for a majority of parasitic infections (e.g., amoebiasis, enterobiasis, etc.) The infection transmitted from one infected man to another man is called as **anthroponoses**
- **Animal:** The infection which is transmitted from infected animals to humans is called as **zoonoses**. The infection can be transmitted to humans either directly or indirectly via vectors. (e.g., cystic echinococcosis from dogs and toxoplasmosis from cats)
- **Vectors:** Vector is an agent, usually an arthropod that transmits the infection from one infected human being to another. Vector can be biological or mechanical. An infected blood sucking insect can transmit the parasite directly into the blood during its blood meal.

**Note:** Vectors have been dealt in detail in Medical Entomology (Chapter 16).

- **Contaminated soil and water:** Soil polluted with human excreta containing eggs of the parasites can act as an important source of infection, e.g., hookworm, *Ascaris* species, *Strongyloides* species and *Trichuris* species.  
Water contaminated with human excreta containing cysts of *E. histolytica* or *Giardia lamblia*, can act as source of infection
- **Raw or under cooked meat:** Raw beef containing the larvae of *Cysticercus bovis* and pork containing *Cysticercus cellulosae* are some of the examples where undercooked meat acts as source of infection
- **Other sources of infection:** Fish, crab or aquatic plants, etc.

### Modes of Transmission

The infective stages of various parasites may be transmitted from one host to another in the following ways:

- **Oral or feco-oral route:** It is the most common mode of transmission of the parasites. Infection is transmitted orally by ingestion of food, water or vegetables contaminated with feces containing the infective stages of the parasite. (e.g., cysts of *E. histolytica*, and ova of *Ascaris lumbricoides*)
- **Penetration of the skin and mucous membranes:** Infection is transmitted by the penetration of the larval forms of the parasite through unbroken skin (e.g., filariform larva of *Strongyloides stercoralis* and hookworm can penetrate through the skin of an individual walking bare-footed over fecally contaminated soil), or by introduction of the parasites through blood-sucking insect vectors. (e.g., *Plasmodium* species, *Leishmania* species and *Wuchereria bancrofti*)
- **Sexual contact:** *Trichomonas vaginalis* is the most frequent parasite to be transmitted by sexual contact. However, *Entamoeba*, *Giardia* and *Enterobius* are also transmitted rarely by sexual contact among homosexuals
- **Bite of vectors:** Many parasitic diseases are transmitted by insect bite (Table 16.2 in Chapter 16) such as: malaria (female anopheles mosquito), filariasis (*Culex*), leishmaniasis (sandfly), Chagas' disease (reduviid bug) and African sleeping sickness (tsetse fly)
- **Vertical transmission:** Mother to fetus transmission is important for few parasitic infections like *Toxoplasma gondii*, *Plasmodium* spp. and *Trypanosoma cruzi*.
- **Blood transfusion:** Certain parasites like *Plasmodium* species, *Babesia* species, *Toxoplasma* species, *Leishmania* species and *Trypanosoma* species can be transmitted through transfusion of blood or blood products
- **Autoinfection:** Few intestinal parasites may be transmitted to the same person by contaminated hand (external auto-infection) or by reverse peristalsis (inter-

nal autoinfection). It is observed in *Cryptosporidium parvum*, *Taenia solium*, *Enterobius vermicularis*, *Strongyloides stercoralis* and *Hymenolepis nana*.

**LIFE CYCLE OF THE PARASITES**

The life cycle of the parasite may be direct (simple) or indirect (complex).

- **Direct/simple life cycle:** When a parasite requires only one host to complete its development, it is referred as direct/simple life cycle (Table 1.1)
- **Indirect/complex life cycle:** When a parasite requires two hosts (one definitive host and another intermediate host) to complete its development, it is referred as indirect/complex life cycle (Table 1.2). Some of the helminths require three hosts (one definitive host and two intermediate hosts) (Table 1.3).

**Table 1.1:** Direct/simple life cycle—parasites that need only one host (man)

Protozoa	Helminths
<ul style="list-style-type: none"><li>• <i>Entamoeba histolytica</i></li><li>• <i>Giardia lamblia</i></li><li>• <i>Trichomonas vaginalis</i></li><li>• <i>Balantidium coli</i></li><li>• <i>Cryptosporidium parvum</i></li><li>• <i>Cyclospora cayetanensis</i></li><li>• <i>Isospora belli</i></li><li>• <i>Microsporidia</i></li></ul>	<b>Cestodes</b> <ul style="list-style-type: none"><li>• <i>Hymenolepis nana</i></li></ul> <b>Nematodes</b> <ul style="list-style-type: none"><li>• <i>Ascaris lumbricoides</i></li><li>• Hookworm</li><li>• <i>Enterobius</i> spp.</li><li>• <i>Trichuris trichiura</i></li><li>• <i>Strongyloides</i> spp.</li></ul>

**PATHOGENESIS OF PARASITIC DISEASES**

The parasites can cause damage to humans in various ways.

- **Mechanical trauma:**
  - **Eggs:** Trematode eggs being large in size, can be deposited inside the

**Table 1.2:** Indirect/complex life cycle: parasites requiring one definitive host and one intermediate host

Man acts as definitive host		
Parasites	Definitive host (man)	Intermediate host
<i>Leishmania</i> spp.	Man	Sandfly
<i>Trypanosoma cruzi</i>	Man	Reduviid bugs
<i>Trypanosoma brucei</i>	Man	Tsetse fly
<i>Taenia solium</i> (intestinal taeniasis)	Man	Pig
<i>Taenia saginata</i>	Man	Cattle
<i>Hymenolepis diminuta</i>	Man	Rat flea
<i>Schistosoma</i> spp.	Man	Snail
<i>Trichinella spiralis</i>	Man	Pig
Filarial worms	Man	Mosquito ( <i>Culex</i> , <i>Aedes</i> , <i>Anopheles</i> ) and flies (blackflies and deerflies)
<i>Dracunculus medinensis</i>	Man	Cyclops
Man acts as intermediate host		
Parasites	Definitive host	Intermediate host
<i>Plasmodium</i> spp.	Female <i>Anopheles</i> mosquito	Man
<i>Babesia</i> spp.	Tick	Man
<i>Sarcocystis lindemanni</i>	Cat and dog	Man
<i>Toxoplasma gondii</i>	Cat	Man
<i>Echinococcus granulosus</i>	Dog	Man
<i>Taenia solium</i> (Cysticercosis)	Man	Man

**Table 1.3:** Indirect/complex life cycle: parasites requiring one definitive host and two intermediate hosts

Parasites	Definitive host	First intermediate host	Second intermediate host
<i>Diphyllbothrium</i> spp.	Man	Cyclops	Fish
<i>Fasciola hepatica</i>	Man	Snail	Aquatic plant
<i>Fasciolopsis buski</i>	Man	Snail	Aquatic plant
<i>Paragonimus</i> spp.	Man	Snail	Crab and fish
<i>Clonorchis</i> spp.	Man	Snail	Fish
<i>Opisthorchis</i> spp.	Man	Snail	Fish
<i>Gnathostoma spinigerum</i>	Cat, dog and man	Cyclops	Fish

intestinal mucosa (*Schistosoma mansoni*), bladder (*Schistosoma haematobium*), lungs (*Paragonimus*), liver (*Fasciola hepatica*) and can cause mechanical irritation

- **Larvae:** Migration of several helminthic larvae (hookworms, *Strongyloides* or *Ascaris*) in the lungs produce traumatic damage of the pulmonary capillaries leading to pneumonitis
- **Adult worms:** Adult worms of hookworm, *Strongyloides*, *Ascaris* or *Taenia* get adhere to the intestinal wall and cause mechanical trauma
- **Space occupying lesions:** Certain parasites produce characteristic cystic lesion that may compress the surrounding tissues or organs, e.g., hydatid cysts and neurocysticercosis
- **Inflammatory reactions:** Most of the parasites induce cellular proliferation and infiltration at the site of their multiplication, e.g., *E. histolytica* provokes inflammation of the large intestine leading to the formation of amoebic granuloma. Adult worm of *W. bancrofti* causes mechanical blockage and chronic inflammation of the lymphatics and lymph vessels. Trematode eggs can induce inflammatory changes (granuloma formation) surrounding the area of egg deposition
- **Enzyme production and lytic necrosis:** Obligate intracellular parasites of man (*Plasmodium*, *Leishmania* and *Trypanosoma*), produce several enzymes, which cause digestion and necrosis of host cells. *E. histolytica* produces various enzymes like cysteine proteinases, hydrolytic enzymes and amoebic pore forming protein that lead to destruction of the target tissue
- **Toxins:** Some of the parasites produce toxins, which may be responsible for pathogenesis of the disease, e.g., *E. histolytica*. However, in contrast to bacterial toxin, parasitic toxins have minimal role in pathogenesis
- **Allergic manifestations:** Many metabolic and excretory products of the parasites get absorbed in the circulation and produce a variety of allergic manifestations in the sensitized hosts  
Examples include schistosomes causing cercarial dermatitis, rupture of hydatid cyst producing anaphylactic reactions and occult filariasis (tropical pulmonary eosinophilia)
- **Neoplasia:** Some of the parasitic infections can contribute to the development of neoplasia (e.g., *S. haematobium* causes bladder carcinoma, *Clonorchis* and *Opisthorchis* cause cholangiocarcinoma)
- **Secondary bacterial infections:** Seen in some helminthic diseases (schistosomiasis and strongyloidiasis).

## IMMUNOLOGY OF PARASITIC DISEASES

The immune response against the parasitic infections depends on two factors:

- **Host factors:** Immune status, age, underlying disease, nutritional status, genetic constitution and various defense mechanisms of the host
- **Parasitic factors:** Size, route of entry, frequency of infection, parasitic load and various immune evasion mechanisms of the parasites.

Broadly, the host immunity against the parasitic diseases may be of two types:

1. Protective immune response
  - i. Innate immunity
  - ii. Adaptive/acquired immunity
2. Unwanted or harmful immune response (hypersensitive reactions).

### Protective Immune Response

Both innate and acquired immunity play an important role in protecting the hosts against parasites. Some of the parasitic infections can be eliminated completely by the host immune responses (complete immunity) while few are difficult to eliminate. In some infections, the immune defense of the host is sufficient to resist further infection but insufficient to destroy the parasite. Immunity lasts till the original infection remains active and prevents further infection. This is called as *infection immunity* or *premunition* or *concomitant immunity* or *incomplete immunity*. This is observed in malaria, schistosomiasis, trichinellosis, toxoplasmosis and Chagas' disease.

#### (i) Innate Immunity

Innate immunity is the resistance which an individual possesses by birth, due to genetic and constitutional make-up.

#### Factors influencing innate immunity

- **Age of the host:** Both the extremes of age are more vulnerable to parasitic infections.

Certain diseases are common in children like giardiasis and enterobiasis while certain infections occur more commonly in adults like hookworm infection. Congenital infection occurs commonly with *Toxoplasma gondii*; whereas newborns are protected from falciparum malaria because of high concentration of fetal hemoglobin

- **Sex:** Certain diseases are more common in males like amoebiasis where as females are more vulnerable to develop anemia due to hookworm infection
- **Nutritional status:** Both humoral and cellular mediated immunity are lowered and neutrophil activity is reduced in malnutrition
- **Genetic constitution of the individuals:** People with hemoglobin S (sickle cell disease), fetal hemoglobin and thalassemia hemoglobin are resistant to falciparum malaria where as Duffy blood group negative red blood cells (RBCs) are resistant to vivax malaria.

#### Components of innate immunity

- **Anatomic barriers (skin and mucosa):** Skin is an important barrier for the parasites that enter by cutaneous routes like *Schistosomes*, hookworm and *Strongyloides*
- **Physiologic barriers:** It includes temperature, pH, and various soluble molecules like lysozyme, interferon and complement. Gastric acidity acts as a physiologic barrier to *Giardia* and *Dracunculus*
- **Phagocytosis:** Phagocytes like macrophages and microphages (neutrophils, basophils and eosinophils) act as first line of defense against the parasites
- **Complements:** They play an important role for killing the extracellular parasites by forming membrane attack complexes; that leads to the formation of holes in the parasite membrane
- **Natural killer cells:** Natural killer cells (NKs) are another important mediator of innate immunity. They play a central role in killing few of the helminthic parasites.



## (ii) Acquired/Adaptive Immunity

This is the resistance acquired by an individual during life following exposure to an agent. It is mediated by antibody produced by B lymphocytes (humoral immune response) or by T cells (cell mediated immune response).

### Cell mediated immune response

- When a parasite enters, the parasitic antigens are processed by the antigen presenting cells, (e.g., macrophages) which present the antigenic peptides to T helper cells. The antigen presenting cells also secrete interleukin-1 (IL-1) that activates the resting T helper cells. Activated T helper cells differentiate into Th-1 and Th-2 cells
- T helper cell-1 secrete interleukin-2 (IL-2) and interferon gamma (IFN- $\gamma$ )
  - Interleukin-2 activates the cytotoxic T cells and NKs, which are cytotoxic to the target parasitic cells. They produce perforin and granzyme that form pores and lyse the target cells
  - IFN- $\gamma$  activates the resting macrophages which in turn become more phagocytic and release free radicals like reactive oxygen intermediate (ROI) and nitric oxide (NO) that kill the intracellular parasites
- T helper cells-2 release IL-4, IL-5, IL-6 and IL-10 which are involved in activation of B cells to produce antibodies [immunoglobulin E (IgE) by IL-4]. IL-5 also acts as chemo-attractant for the eosinophils. Eosinophilia is common finding in various helminthic infections.

### Humoral immune response

Th-2 response activates the B cells to produce antibodies which in turn have various roles against the parasitic infections. They are:

- **Neutralization** of parasitic toxins (mediated by IgA and IgG)
- **Preventing** attachment to the gastrointestinal tract (GIT) mucosa (mediated by secretory IgA)

- **Agglutinating** the parasitic antigens thus preventing invasion (mediated by IgM)
- **Complement activation (by IgM and IgG):** Complements bind to the Fc portion of the antibody coated to the parasitic cells. Activation of the complements leads to membrane damage and cell lysis
- **Antibody dependent cell-mediated cytotoxicity (ADCC)** is important for killing of the helminths. NKs bind to the Fc portion of the IgG antibody coated to the helminths. Activation of NKs leads to release of perforin and granzyme that in turn cause membrane damage and cell lysis
- **Mast cell degranulation:** IgE antibodies coated on mast cells when get bound to parasitic antigens, the mast cells become activated and release a number of mediators like serotonin and histamine.

## The Unwanted or Harmful Immune Responses

Sometimes immune responses may be exaggerated or inappropriate in the sensitized individuals on re-exposure to the same antigen. Such type of immunopathologic reactions are called as hypersensitivity reactions that may be harmful to the hosts causing tissue damage. These are of four types (Table 1.4).

## Parasitic Factors that Evade the Host Immune Response

Sometimes the hosts find it difficult to contain the parasitic infections mainly because of the following reasons:

- Large size of the parasites
- Complicated life cycles
- Antigenic complexity.

There are a number of mechanisms by which the parasites evade the host immune responses (Table 1.5).

## LABORATORY DIAGNOSIS OF PARASITIC DISEASES

It plays an important role in establishing

**Table 1.4:** Hypersensitivity reactions seen in parasitic diseases

Hypersensitive reactions	Parasitic diseases
<b>Type I hypersensitivity reactions</b> These are allergic or anaphylactic reactions, occurring within minutes of exposure to parasitic antigens due to IgE mediated degranulation of mast cells	<ul style="list-style-type: none"><li>• Cercarial dermatitis (Swimmer’s Itch) in schistosomiasis</li><li>• Loeffler’s syndrome in ascariasis</li><li>• Ground itch (Hookworm infection)</li><li>• Anaphylaxis due to leakage of hydatid fluid (<i>Echinococcus granulosus</i>)</li><li>• Casoni’s test (done in the diagnosis of hydatid disease).</li><li>• Tropical pulmonary eosinophilia (occult filariasis)</li></ul>
<b>Type II hypersensitivity reactions</b> These are mediated by IgG or rarely IgM antibodies produced against the antigens on surfaces of the parasitic cells causing antibody mediated destruction of the cells by i) the complement activation or ii) by the NK cell activation (ADCC -antibody dependent cell mediated cytotoxicity)	<ul style="list-style-type: none"><li>• Anemia in malaria</li><li>• Black water fever in malaria following quinine therapy</li><li>• Myocarditis in Chagas’ disease</li><li>• Killing of the helminths by NK cells</li></ul>
<b>Type III hypersensitivity reactions</b> Immune complexes are formed by the combination of parasitic antigens with the circulating antibodies (IgG) which get deposited in various tissues	<ul style="list-style-type: none"><li>• Nephrotic syndrome in <i>Plasmodium malariae</i></li><li>• Katayama fever in schistosomiasis</li><li>• African trypanosomiasis</li><li>• Onchocerciasis</li></ul>
<b>Type IV hypersensitivity reactions</b> This is T-cell mediated delayed type of hypersensitivity reaction. Previously sensitized T helper cells secrete a variety of cytokines, on subsequent exposure to the parasitic antigens. Usually, the pathogen is cleared rapidly with little tissue damage. However, in some cases, it may be destructive to the host resulting in granulomatous reaction	<ul style="list-style-type: none"><li>• Elephantiasis (in filariasis)</li><li>• Granulomatous disease in schistosomiasis and other helminthic infections</li><li>• Leishmaniasis</li></ul>

Abbreviations: IgE, immunoglobulin E; IgG, immunoglobulin G; IgM, immunoglobulin M; NKs, natural killer cells.

the specific diagnosis of various parasitic infections. Following techniques are used in diagnosis of parasitic infections (has been discussed in detail in Chapter 15):

- Parasitic diagnosis—either microscopically or macroscopically
- Culture methods
- Immunodiagnostic methods (antigen and antibody detection)
- Intradermal skin tests
- Molecular methods
- Xenodiagnostic techniques
- Animal inoculation
- Imaging techniques.

**TREATMENT OF PARASITIC DISEASES**

Treatment of parasitic disease is primarily based on chemotherapy and in some cases by surgery.

**Antiparasitic Drugs**

Various chemotherapeutic agents are used for the treatment and prophylaxis of parasitic infections (Table 1.6).

**Surgical Management**

For management of parasitic diseases like cystic echinococcosis and neurocysticercosis surgery is indicated.



**Table 1.5:** Immune evasion mechanisms of the parasites

<b>Immune evasion mechanisms</b>	<b>Parasites involved</b>
By intracellular location	<i>Plasmodium</i> spp, <i>Babesia</i> spp., <i>Trypanosoma</i> spp., <i>Toxoplasma</i> spp., <i>Leishmania</i> spp. and <i>Microsporidia</i>
Enters an immunologically protected site soon after infection	<i>Plasmodium</i> spp. entering into hepatocytes
Leave the site where the immune response is already established	<i>Ascaris</i> undergoes intestinal phase and migratory lung phase during its life cycle
Survives in macrophages by preventing phago-lysosome fusion	<i>Leishmania</i> , <i>Trypanosoma</i> and <i>Toxoplasma</i>
<b>Antigenic shedding (capping):</b> Surface membrane antigens of the parasites bound to the antibodies undergo redistribution so that the parasite is covered by a folded membrane that later extrude as a cap containing most of the antibodies that were originally bound to the membrane	<i>Entamoeba histolytica</i> , <i>Trypanosoma brucei</i> and <i>Acylostoma caninum</i>
<b>Antigenic variation:</b> By change of antigenic composition, the parasites can be protected from the antibodies which are formed against the original antigens	<i>P. falciparum</i> ( pf-EMP protein), <i>Giardia</i> and <i>Trypanosoma brucei</i>
<b>Antigenic mimicry:</b> The adult flukes of <i>Schistosoma</i> get coated with the host red cell antigens and histocompatibility antigens, so that they are not recognized as foreign and live free from host attack	<i>Schistosoma</i> spp.
Inhibit antibody binding	<i>Schistosoma mansoni</i>
Lymphocyte suppression	<i>Schistosoma mansoni</i>
Polyclonal stimulation of lymphocytes	<i>P. falciparum</i> , <i>Trypanosoma brucei</i> , <i>Babesia</i> , <i>Trichinella</i> and <i>E. histolytica</i> .
Suppression of immune system	<i>Trypanosoma</i> , <i>Plasmodium</i> and <i>Leishmania</i>

**Table 1.6:** Common antiparasitic drugs, their mechanism of action and clinical indications

<b>Antiparasitic Drugs</b>		
<b>Drugs for amoebiasis</b>	<b>Mechanism of action</b>	<b>Clinical indications</b>
Metronidazole, tinidazole and ornidazole (nitroimidazole compound)	Bioactivated to form reduced cytotoxic products which damage DNA	DOC for the amoebic colitis, amoebic liver abscess, and other extraintestinal amoebiasis
Dehydroemetine	Inhibits protein synthesis	Parenterally used for severe hepatic amoebiasis.
Chloroquine	Probably by concentrating in parasite food vacuoles.	Used for extra intestinal amoebiasis.
Paromomycin (Aminoglycoside)	Inhibits protein synthesis by binding to 16S ribosomal RNA	Effective luminal agent
Diloxanide furoate (Acetanilide compound)	Unknown; it is thought to interfere with protein synthesis	Effective luminal agent
Iodoquinol (8-hydroxyquinoline compound)	Unknown	Luminal agent
Amphotericin B	Complex and multifaceted.	DOC for <i>Naegleria fowleri</i>

Contd...

Contd...

<b>Drugs for flagellates</b>	<b>Mechanism of action</b>	<b>Clinical indications</b>
<b>Intestinal/Genital Flagellates</b>		
<b>Giardiasis</b>		
Metronidazole and tinidazole	Bioactivated to form reduced cyto-toxic products which damage DNA.	DOC for Giardiasis
Nitazoxanide	Interference with the PFOR enzyme dependent electron transfer reaction which is essential for anaerobic energy metabolism.	
Furazolidone	Cross linking of DNA	Given to children
Paromomycin	Protein synthesis inhibitor in non-resistant cells by binding to 16S ribosomal RNA.	Can be given in pregnancy
<b>Trichomoniasis</b>		
Metronidazole or tinidazole	Bioactivated to form reduced cyto-toxic products having nitro groups which damage DNA.	DOC for trichomoniasis, given to both the partners
<b>Hemoflagellates</b>		
<b>Trypanosomiasis</b>		
<b>Chagas' disease</b>		
Nifurtimox	Forms nitro-anion radical metabolite, which reacts with the nucleic acids of the parasite, causing a significant breakage in the DNA	Chagas' disease
Benznidazole	Production of free radicals, to which <i>Trypanosoma cruzi</i> is particularly sensitive	Effective in the treatment of reactivated <i>T. cruzi</i> infections caused by immunosuppression (AIDS patients or patients of organ transplants)
<b>Sleeping sickness</b>		
Pentamidine	Accumulates to micromolar concentrations within the parasite to kill it by inhibiting enzymes and interacting with DNA	DOC for East African sleeping sickness
Suramin	Trypanocidal activity; inhibits enzymes involved with the oxidation of reduced NADH	DOC for West African sleeping sickness
<b>Leishmaniasis</b>		
Sodium stibogluconate Meglumine antimoniate	Inhibition of the parasite's glycolytic and fatty acid oxidative activity resulting in decreased reducing equivalents for antioxidant defense and decreased synthesis of ATP	Leishmaniasis
Amphotericin B	Complex and multifaceted	Leishmaniasis
Paromomycin	Protein synthesis inhibitor in non-resistant cells by binding to 16S	Leishmaniasis

Contd...

Contd...

Miltefosine	Can trigger programmed cell death (apoptosis)	Leishmaniasis
<b>Drugs for malaria</b>	<b>Mechanism of action</b>	<b>Clinical indications</b>
Chloroquine	Probably, concentrating in parasite food vacuoles, preventing the polymerization of the hemoglobin into the toxic product hemozoin	DOC for uncomplicated benign malaria
Artemisinin derivative (Artemisinin or artemether or arte-ether)	Generate highly active free radicals that damage parasite membrane	DOC for complicated or falciparum malaria
Quinine	Probably similar to chloroquine; still not clear	DOC for complicated or falciparum malaria
Mefloquine	Same as chloroquine	DOC for complicated or falciparum malaria
Primaquine	Generating reactive oxygen species	DOC for relapse of vivax malaria
Sulfadoxine-pyrimethamine	Inhibits the production of enzymes involved in the synthesis of folic acid within the parasites	DOC for complicated or falciparum malaria
Lumefantrine	Accumulation of heme and free radicals	Complicated or falciparum malaria
<b>Drugs for babesiosis</b>	<b>Mechanism of action</b>	<b>Clinical indication</b>
Clindamycin plus quinine		DOC for severe babesiosis
Atovaquone plus azithromycin		DOC for mild babesiosis
<b>Drugs for toxoplasmosis</b>	<b>Mechanism of action</b>	<b>Clinical indications</b>
Cotrimoxazole (Trimethoprim-sulfamethoxazole)	Inhibiting folate synthesis from PABA (para aminobenzoic acid), thus inhibiting purine metabolism	DOC for prophylaxis in HIV infected people
Spiramycin	Inhibition of protein synthesis in the cell during translocation	DOC in pregnancy
<b>Drugs for Cryptosporidium</b>	<b>Mechanism of action</b>	<b>Clinical indications</b>
Nitazoxanide	Interferes with the PFOR enzyme-dependent electron-transfer reaction, which is essential to anaerobic metabolism in protozoan and bacterial species	DOC for <i>Cryptosporidium</i> infection
<b>Drugs for Isospora and Cyclospora</b>	<b>Mechanism of action</b>	<b>Clinical indications</b>
Cotrimoxazole (Trimethoprim-sulfamethoxazole)	Inhibiting folate synthesis from PABA (Para aminobenzoic acid), thus inhibiting purine metabolism	DOC for <i>Isospora</i> and <i>Cyclospora</i> infection
<b>Drugs for cestodes</b>	<b>Mechanism of action</b>	<b>Clinical indication</b>
Praziquantel	Increases the permeability of the membranes of parasite cells toward calcium ions which induces contraction of the parasites, resulting in paralysis in the contracted state	DOC for all cestode infections

Contd...

Contd...

Niclosamide	Niclosamide uncouples oxidative phosphorylation	Alternative drug for cestode infections
Albendazole	Causes loss of the cytoplasmic microtubules leading to impaired uptake of glucose by the larval and adult stages of the susceptible parasites, and depleting their glycogen stores	Given for cysticercosis and hydatid disease
<b>Drugs for trematodes</b>		
	<b>Mechanism of action</b>	<b>Clinical indication</b>
Praziquantel	Increases the permeability of the membranes of parasite cells toward calcium ions which induces contraction of the parasites, resulting in paralysis in the contracted state	DOC for most of the trematode infections
Triclabendazole	Binds to beta-tubulin and prevent the polymerization of the microtubules	DOC for <i>Fasciola hepatica</i> and <i>F. gigantica</i>
<b>Drugs for nematodes</b>		
	<b>Mechanism of action</b>	<b>Clinical indication</b>
<b>Intestinal nematodes</b>		
Mebendazole or albendazole	Causes loss of the cytoplasmic microtubules leading to impaired uptake of glucose by the larval and the adult stages of the susceptible parasites, and depleting their glycogen stores	DOC for most of the intestinal nematodes
Pyrantel pamoate	Acts as a depolarizing neuromuscular blocking agent, thereby causing sudden contraction, followed by spastic paralysis of the helminths	Alternative drug for intestinal nematodes
Ivermectin	Kills by interfering with nervous system and muscle function, in particular by enhancing inhibitory neurotransmission resulting in flaccid paralysis	More effective for disseminated strongyloidiasis. Alternative drug for <i>Trichuris</i> infections
<b>Filarial nematodes</b>		
Diethylcarbamazine (DEC)	An inhibitor of arachidonic acid metabolism in microfilaria. This makes the microfilaria more susceptible to phagocytosis	DOC for lymphatic filariasis, <i>Loa loa</i> and <i>Mansonella</i> infections
Albendazole	Causes loss of the cytoplasmic microtubules leading to impaired uptake of glucose by the larval and the adult stages of the susceptible parasites, and depleting their glycogen stores	Alternative drug for lymphatic filariasis, <i>Loa loa</i> and <i>Mansonella</i> infections

Contd...

Contd...

Ivermectin	Kills by interfering with nervous system and muscle function, in particular by enhancing inhibitory neurotransmission	Used for lymphatic filariasis in Africa DOC for onchocerciasis Alternative drug for <i>Loa loa</i> and <i>Mansonella</i> infections
Doxycycline	Targets the intracellular <i>Wolbachia</i> present inside the <i>Microfilaria</i>	Alternative drug for lymphatic filariasis

Abbreviations: DNA, deoxyribonucleic acid; DOC, drug of choice; RNA, ribonucleic acid; PFOR, pyruvate ferredoxin oxidoreductase enzyme; ATP, adenosine triphosphate; NADH, nicotinamide adenine dinucleotide.

### EXPECTED QUESTIONS

#### I. Write short notes on:

- (a) Paratenic host
- (b) Reservoir host
- (c) Indirect/complex life cycle
- (d) Immune evasion mechanisms of the parasites
- (e) Antiparasitic drugs

#### II. Differentiate between:

- (a) Definitive host and intermediate host
- (b) Direct and indirect life cycle

#### III. Multiple choice questions (MCQs):

##### 1. A host harboring adult or sexual stage of a parasite is called:

- (a) Definitive host
- (b) Intermediate host
- (c) Reservoir host
- (d) None of the above

##### 2. Parasite which may be transmitted by sexual contact is:

- (a) *Trypanosoma cruzi*

- (b) *Trichomonas vaginalis*

- (c) *Trypanosoma brucei*

- (d) *Ascaris*

##### 3. Cholangiocarcinoma is associated with chronic infection of:

- (a) *Paragonimus westermani*
- (b) *Fasciola hepatica*
- (c) *Clonorchis sinensis*
- (d) *Schistosoma haematobium*

##### 4. Which of the following parasite is transmitted by dog:

- (a) *Taenia saginata*
- (b) *Hymenolepis nana*
- (c) *Echinococcus granulosus*
- (d) *Diphyllobothrium latum*

##### 5. Blood-sucking vector may transmit:

- (a) *Ascaris lumbricoides*
- (b) *Ancylostoma duodenale*
- (c) *Strongyloides stercoralis*
- (d) *Plasmodium*

### Answers

1. (a)    2. (b)    3. (c)    4. (c)    5. (d)



# Section 2

---

## Protozoology

- Chapter 2** Introduction to Protozoa
- Chapter 3** Amoeba
- Chapter 4** Flagellates—I (Intestinal and Genital)
- Chapter 5** Flagellates—II (Hemoflagellates)
- Chapter 6** Sporozoa—I (Malaria Parasite and Babesia)
- Chapter 7** Sporozoa—II (Opportunistic Coccidian Parasites)
- Chapter 8** Miscellaneous Protozoa





# 2 Introduction to Protozoa

## Chapter Outline

- General features of protozoa
- Classification of protozoa
- Expected questions

### GENERAL FEATURES OF PROTOZOA

The protozoa are unicellular eukaryotic cells that perform all the physiological function.

- More than two lakhs protozoa are named but only about 70 species belonging to nearly 30 genera infect human beings
- Many of these protozoa are relatively harmless but few may cause some of the important diseases of tropical countries like malaria, kala azar, sleeping sickness and Chaga's disease, etc which together threaten one quarter of the population of the World
- With the advent of HIV/AIDS, some of them are increasingly being recognized as opportunistic pathogens like toxoplasmosis, cryptosporidiosis, etc
- In general, protozoa are placed between prokaryotes and higher eukaryotes
  - Like bacteria, they are small, single celled, 1–150  $\mu\text{m}$  size, short generation time, higher reproduction rates and have a tendency to induce immunity to reinfection in those who survive

- On other hand, the protozoa are undoubtedly lower eukaryotes as they possess cellular organelles and have similar metabolic pathways.

### CLASSIFICATION OF PROTOZOA

#### The Traditional 1980s Classification

Based on the recommendation of the committee on Systematics and Evolution of the Society of Protozoologists conducted by Levine et al (1980), the protozoan parasites were classified (Table 2.1)

Though it satisfied the requirements of the protozoologists but couldn't meet some of the requirements of medical parasitologists.

#### Corliss's Interim User Friendly Classification (1994)

Corliss proposed a user-friendly classification trying to meet the requirements of both protozoologists and medical parasitologists.

He divided the living creatures into six kingdoms. Unicellular parasites (generally accepted as protozoa) are categorized into two phylum—Archezoa and Protozoa.

**Table 2.1:** The traditional 1980s classification of protozoa (Levine et al., 1980)

Phylum	Subphylum	Super class	Class	Subclass	Order	Suborder	Genus
Sarcomastigophora (Amoeba and flagellates)	Mastigophora		Zoomastigophorea		Kinetoplastida	Trypanosomatina	<i>Leishmania</i> <i>Trypanosoma</i>
							<i>Retortamonas</i> <i>Chilomastix</i>
							<i>Giardia</i>
							<i>Enteromonas</i>
							<i>Trichomonas</i> <i>Pentatrichomonas</i> <i>Dientamoeba</i>
Apicomplexa (sporozoans)	Sarcodina	Rhizopoda	Lobosea	Gymnamoebia	Amoebida	Tubulina	<i>Entamoeba</i> <i>Endolimax</i> <i>Iodamoeba</i>
							<i>Acanthamoeba</i>
							<i>Naegleria</i>
							<i>Eimeria</i> <i>Toxoplasma</i> <i>Cryptosporidium</i> <i>Cyclospora</i> <i>Isospora</i> <i>Sarcocystis</i>
							<i>Plasmodium</i>
Microspora			Microsporea	Piroplasmia	Piroplasmida Microsporida	Apansporoblastina	<i>Babesia</i> <i>Enterocytozoon</i> <i>Encephalitozoon</i> <i>Pleistophora</i> <i>Trachipleistophora</i> <i>Brachiola</i> <i>Nosema</i> <i>Vittiforma</i> <i>Microsporium</i> <i>Balantidium</i>
Ciliophora			Kinetofragmino-phorea	Vestibuliferia	Trichostomatida	Trichostomatina	

Adapted from: Topley and Wilson’s Microbiology and Microbial Infections (Parasitology volume), 10th edition.

### Molecular Classification (2000)

The hierarchical system can be accurately represented by the ribonucleic acid (RNA) and protein sequences of the organisms. With advance of molecular techniques, the ribosomal RNA and protein sequences are studied, and a new classification has been devised.

- Cavalier and Smith's six kingdoms classification—molecular classification is based on the six kingdom theory proposed by Cavalier and Smith (1998). They are bacteria, protozoa, animalia, fungi, plantae and chromista
- The unicellular protozoan parasites constitute thirteen phyla of which the human parasites belong to seven phyla which are distributed in three kingdoms—Protozoa, Fungi and Chromista (Table 2.2)
- The description in this book will be according to this classification.

### Kingdom Protozoa

Unicellular eukaryotic, phagotrophic, non-photosynthetic organism without a cell wall.

#### Subkingdom Archezoa

Unicellular eukaryotic organisms exhibiting various prokaryotic features in ribosomes and transfer ribonucleic acid (tRNA) and lacking mitochondria and other organelles.

- **Phylum Metamonada:** Unicellular intestinal flagellates (2–8 numbers)
- **Phylum Parabasalia:** Unicellular flagellates with one or more nuclei and numerous flagella and parabasal body.

#### Subkingdom Neozoa

Unicellular eukaryotic organisms typically possessing mitochondria and other organelles.

- **Phylum Amoebozoa:** Unicellular eukaryotic organisms with pseudopodia used for locomotion and feeding
  - **Class Amoebaea:** free living amoeba with and mitochondria
  - **Class Entamoebidea:** Obligate amoeba with secondary loss of mitochondria
- **Phylum Percolozoa:** Unicellular organisms having 1–4 temporary flagella and mitochondria but lacking Golgi bodies
- **Phylum Euglenozoa:** Unicellular organisms having 1–4 flagella, mitochondria and Golgi bodies
- **Phylum Sporozoa:** Unicellular eukaryotic organisms possessing apical complex made up of polar rings, rhoptries, micronemes and conoid
- **Phylum Ciliophora:** Unicellular organisms having cilia as loco motor organ and two nuclei of different size and ploidy—(1) macronucleus and (2) micronucleus.

### Kingdom Fungi

Eukaryotic heterotrophic organisms lacking plastids but possessing cell wall containing chitin and  $\beta$ -glucan.

### Kingdom Chromista

Unicellular eukaryotic, photosynthetic filamentous or colonial, organisms (in part “algae”); some with secondary loss of plastids.

**Table 2.2:** Molecular classification (2000)

Kingdom	Subkingdom	Phylum	Class	Order	Genus
Protozoa	Archezoa	Metamonada	Trepomonadea	Diplomonadida	<i>Giardia</i>
				Enteromonadida	<i>Enteromonas</i>
			Retortamonadea	Retortamonadida	<i>Retortamonas</i> <i>Chilomastix</i>
					<i>Trichomonas</i> <i>Pentatrichomonas</i> <i>Dientamoeba</i>
	Neozoa	Amoebozoa	Entamoebidea	Euamoebida	<i>Entamoeba</i> <i>Endolimax</i> <i>Iodamoeba</i>
					<i>Acanthamoeba</i>
		Percolozoa	Heterolobosea (flagellated amoeba)	Schizopyrenida	<i>Naegleria</i>
		Euglenozoa	Kinetoplastea	Trypanosomatida	<i>Leishmania</i> <i>Trypanosoma</i>
		Sporozoa	Coccidea	Eimeriida	<i>Eimeria</i> <i>Toxoplasma</i> <i>Cryptosporidium</i> <i>Cyclospora</i> <i>Isospora</i> <i>Sarcocystis</i>
					<i>Plasmodium</i>
					<i>Babesia</i>
		Ciliophora	Litostomatea	Vestibuliferida	<i>Balantidium</i>
Fungi		Microspora	Microsporea	Microsporida	<i>Enterocytozoon</i> <i>Encephalitozoon</i> <i>Pleistophora</i> <i>Trachipleistophora</i> <i>Brachiola</i> <i>Nosema</i> <i>Vittaforma</i> <i>Microsporum</i>
					<i>Blastocystis</i>
Chromista	Chromobiota	Bigyra	Blastocystea		<i>Blastocystis</i>

Adapted from: Topley and Wilson's Microbiology and Microbial Infections (Parasitology volume), 10th edition.

## EXPECTED QUESTIONS

### I. Write short notes on:

- (a) The traditional 1980s classification of parasites
- (b) Molecular classification (2000) of parasites
- (c) Subkingdom Neozoa

### II. Multiple choice questions (MCQs):

#### 1. Which of the following protozoa belongs to phylum Euglenozoa?

- (a) *Leishmania* species
- (b) *Entamoeba* species
- (c) *Cryptosporidium* species
- (d) *Plasmodium* species

#### 2. Which of the following protozoa belongs to kingdom Chromista?

- (a) *Isospora* species
- (b) *Babesia* species
- (c) *Giardia* species
- (d) *Blastocystis* species

#### 3. Which of the following protozoa belongs to order Schizopyrenida?

- (a) *Plasmodium* species
- (b) *Naegleria* species
- (c) *Acanthamoeba* species
- (d) *Entamoeba* species

#### 4. Which of the following protozoa belongs to phylum Sporozoa?

- (a) *Giardia* species
- (b) *Toxoplasma* species
- (c) *Plasmodium* species
- (d) *Entamoeba* species

### Answers

1. (a)    2. (d)    3. (b)    4. (c)

# 3 Amoeba

## Chapter Outline

- Classification of amoeba
- Intestinal amoeba
  - Pathogenic intestinal amoeba
  - Nonpathogenic intestinal amoeba
- Free-living amoeba
- Expected questions

## ■ CLASSIFICATION OF AMOEBAS

Amoeba is a single-celled protozoa that constantly changes its shape. The word “**amoeba**” is derived from the Greek word “**amoibe**” meaning “**change**”. They constantly change their shape due to presence of an organ of locomotion called as “pseudopodium”

### Classification Based On Habitat

Amoebae are classified as intestinal amoebae and free living amoebae.

- **Intestinal amoebae:** They inhabit in the large intestine of humans and animals. *Entamoeba histolytica* is the only pathogenic species. Others are nonpathogenic such as—*E. dispar*, *E. moshkovskii*, *E. coli*, *E. polecki*, *E. hartmanni*, *E. gingivalis*, *Endolimax nana*, and *Iodamoeba butschlii*
- **Free-living amoebae:** They are small free living and opportunistic pathogens. Examples are *Acanthamoeba* species, *Naegleria fowleri*, *Balamuthia mandrillaris* and *Sappinia diploidea*

## Taxonomical Classification

According to the traditional 1980s classification—amoeba belongs to the Phylum Sarcomastigophora, Subphylum Sarcodina, Superclass Rhizopoda, Class Lobosea, Subclass Gymnamoebia, Order Amoebida and Family Endamoebidae.

However, in last 30 years, with the advent of molecular technique, the taxonomy is changed and currently the new molecular classification is followed (Table 3.1).

## ■ PATHOGENIC INTESTINAL AMOEBAS

### Entamoeba histolytica

#### Introduction

*E. histolytica* is worldwide in distribution but more common in tropical and subtropical countries.

- *E. histolytica* has three subspecies—*E. histolytica* subspecies *histolytica*, *dispar* and *moshkovskii*

**Table 3.1:** Taxonomy of Amoeba

Kingdom	Subkingdom	Phylum	Class	Order	Genus
Protozoa	Neozoa	Amoebozoa	Entamoebidea	Euamoebida	<i>Entamoeba</i> <i>Endolimax</i> <i>Iodamoeba</i>
			Amoebaea	Acanthopodida	<i>Acanthamoeba</i>
		Percolozoa	Heterolobosea (flagellated amoeba)	Schizopyrenida	<i>Naegleria</i>

- Cysts and trophozoites of all the three subspecies are morphologically indistinguishable
- However, on the basis of extensive genetic, immunological, and biochemical analysis, currently all the three subspecies are formally accepted as different yet closely related species
- *E. histolytica* is the pathogenic species causing amoebic dysentery and a wide range of other invasive diseases, including amoebic liver abscess, where as other two are considered as nonpathogens that colonize the large intestine.

### History

*E. histolytica* was first described by Fedor Losch (1875) from Russia.

- The species name was first coined by Fritz Schaudinn in 1903
- Brumpt had described and designated the nonpathogenic form of *E. histolytica* as *E. dispar* in 1993.

### Epidemiology

Amoebiasis is a major health problem worldwide.

- The largest burden of the disease occurs in tropics of China, Central and South America, and Indian subcontinents affecting 10% of the world's population. (500 million)
- It is the third most common parasitic cause of death in the world (after malaria and schistosomiasis). Approximately 50 million cases and 110, 000 deaths are

reported annually by WHO (World health Organization)

- In India, the prevalence rate is around 15% (ranges from 3.6% to 47.4%) with a higher prevalence reported from Maharashtra, Tamilnadu and Chandigarh.

### Morphology

*E. histolytica* has three stages—(1) trophozoite, (2) precyst and (3) cyst (immature and mature).

#### Trophozoite

It is the invasive form as well as the feeding and replicating form of the parasite found in the feces of patients with active disease.

- It measures 12–60  $\mu\text{m}$  (average 15–20  $\mu\text{m}$ ) in diameter
- Cytoplasm of trophozoite is divided into a clear ectoplasm and a granular endoplasm
- Granular endoplasm looks as ground glass appearance and contains red blood cells (RBCs), white blood cells (WBCs) and food vacuoles containing tissue debris and bacteria. RBCs are found only in the stage of invasion
- **Pseudopodia:** Ectoplasm has long finger like projections called as pseudopodia (organ of locomotion); which exhibits active, unidirectional rapid progressive and purposeful movement
- Nucleus is single, spherical, 4–6  $\mu\text{m}$  size, contains central dot like compact karyosome surrounded by a clear halo. Nuclear membrane is thin and delicate and is lined by a layer of fine chromatin granules. The number of chromosomes varies between 30 and 50

- The space between the karyosome and the nuclear membrane is traversed by spoke like radial arrangement of achromatic fibrils (cart wheel appearance)
- Amoebic trophozoites are anaerobic parasites. They lack mitochondria, endoplasmic reticulum and Golgi apparatus. (Fig. 3.1A).

### Precyst

It is the intermediate stage between trophozoite and cyst.

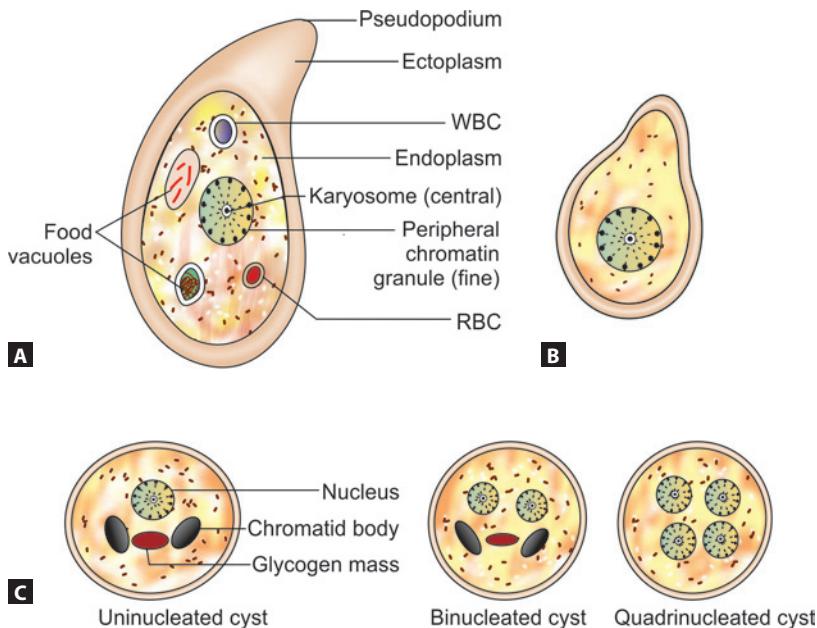
- It is smaller to trophozoite but larger to cyst (10–20  $\mu\text{m}$ )
- It is oval with a blunt pseudopodia. Food vacuoles and RBCs disappear. Nuclear structures are same as that of trophozoite (Fig. 3.1B).

### Cyst

It is the infective form as well as the diagnostic form of the parasite found in the feces of carriers as well as patients with active disease.

- It measures 10–20  $\mu\text{m}$  (average 12–15  $\mu\text{m}$ ) in diameter (Fig. 3.1C)
- Nuclear structures are same as in trophozoites. First, the cyst is uninucleated; later the nucleus divides to form binucleated and finally becomes quadrinucleated cyst
- Cytoplasm of uninucleated cyst contains 1–4 numbers refractile bars with rounded ends called as **chromatoid bodies** (aggregation of ribosome) and a large **glycogen mass** (stains brown with iodine)
- Both chromatoid body and glycogen mass gradually disappear, and they are not found in mature quadrinucleated cyst
- Cysts are present only in the gut lumen; they never invade the intestinal wall.

**“Minuta” form of *Entamoeba histolytica*:** They are the commensal phase of *E. histolytica*, living in the lumen of gut. They are usually smaller in size (trophozoite 12–14  $\mu\text{m}$  and cyst < 10  $\mu\text{m}$ ) and often mistaken as *E. hartmanni*.



**Figs 3.1A to C:** *Entamoeba histolytica* (schematic diagram) (A) trophozoite; (B) precyst; (C) cysts



### Life Cycle (Fig. 3.2)

**Host:** *E. histolytica* completes its life cycle in single host, i.e. man.

**Infective form:** Mature quadrinucleated cyst is the infective form. It can resist chlorination, gastric acidity and desiccation and can survive in a moist environment for several weeks.

**Note:** Trophozoites and immature cysts can be passed in stool of amoebic patients, but they can't serve as infective form as they are disintegrated in the environment or by gastric juice when ingested.

**Mode of transmission:**

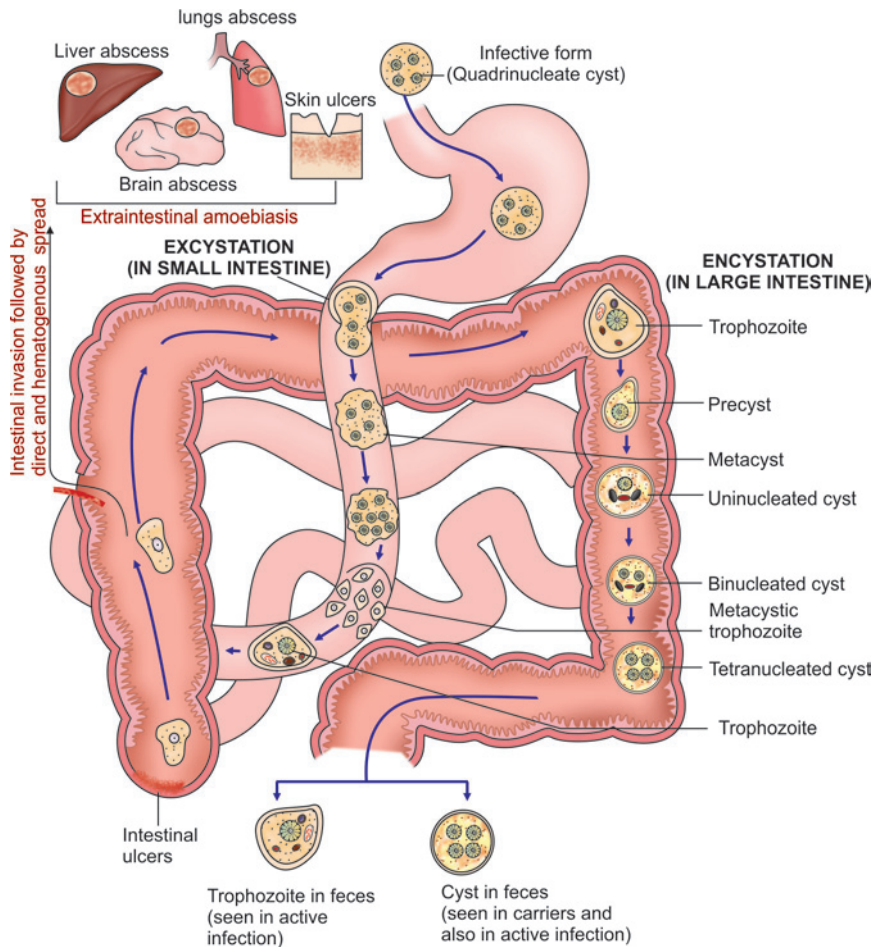
- **Feco-oral route (most common):** By inges-

tion of contaminated food or water with mature quadrinucleated cysts

- **Sexual contact:** Rare, either by anogenital or orogenital contact. (especially in developed countries among homosexual males)
- **Vector:** Very rarely, flies and cockroaches may mechanically transmit the cysts from feces, and contaminate food and water.

### Development in man (small intestine)

- **Excystation:** In small intestine, the cyst wall gets lysed by trypsin and a single tetranucleated trophozoite (metacyst) is liberated which eventually undergoes a



**Fig. 3.2:** Life cycle of *Entamoeba histolytica*

series of nuclear and cytoplasmic divisions to produce eight small **metacystic trophozoites**

- Metacystic trophozoites are carried by the peristalsis to ileocecal region of large intestine and multiply by binary fission, and then colonize on the mucosal surfaces and crypts of the large intestine
- After colonization, trophozoites show different courses depending on various factors like host susceptibility, age, sex, nutritional status, host immunity, intestinal motility, transit time and intestinal flora
- **Asymptomatic cyst passers:** In majority of individuals, trophozoites don't cause any lesion, transform into cysts and are excreted in feces
- **Amoebic dysentery:** Trophozoites of *E. histolytica* secrete proteolytic enzymes that cause destruction and necrosis of tissue, and produces flask shaped ulcers on the intestinal mucosa. At this stage, large numbers of trophozoites are liberated along with blood and mucus in stool producing amoebic dysentery. Trophozoites usually degenerate within minutes
- **Amoebic liver abscess:** In few cases, erosion and necrosis of small intestine are so extensive that the trophozoites gain entrance into the radicals of portal veins and are carried away to the liver where they multiply causing amoebic liver abscess.

#### **Development in man (large intestine)**

- **Encystation:** After some days, when the intestinal lesion starts healing and patient improves, the trophozoites transform into precysts then into quadrinucleated cysts which are liberated in feces
- Encystation occurs only in the large gut. Cysts are never formed once the trophozoites are excreted in stool
- Factors that induce cyst formation include food deprivation, overcrowding, desiccation, accumulation of waste products, and cold temperatures

- Mature quadrinucleated cysts released in feces can survive in the environment and become the infective form. Immature cysts and trophozoites are some times excreted, but get disintegrated in the environment. (Fig. 3.2).

#### **Pathogenesis**

Trophozoite of *E. histolytica* is the major invasive form and possesses many virulence factors that play role in the pathogenesis of intestinal as well as extraintestinal amoebiasis (Table 3.2).

#### **Pathogenesis of Intestinal Amoebiasis**

Trophozoites invade the colonic mucosa producing characteristic ulcerative lesions and profuse bloody diarrhea (amoebic dysentery). Males and females are affected equally with a ratio of 1:1.

#### **Amoebic ulcer**

The classical ulcer is **flask-shaped** (broad base with a narrow neck).

- It may be localized to ileocecal region (most common site) or sigmoidorectal region or may be generalized involving the whole length of the large intestine
- Ulcers are usually scattered with intervening normal mucosa
- It may be superficial (confined to muscularis mucosa and heal without scar) or deep ulcer (beyond muscularis mucosa and heals with scar formation)
- Size ranging from pin head to inches
- Shape round to oval
- Margin ragged and undermined
- Base is formed on muscle coat.

#### **Complications of intestinal amoebiasis (Fig. 3.3)**

There are following types of complications:

- **Fulminant amoebic colitis:** Resulting from generalized necrotic involvement of entire large intestine, occurs more commonly

**Table 3.2:** Virulence factors of *Entamoeba histolytica***Amoebic lectin antigen**

- It is a 260 kDa galactose and N-acetylgalactosamine inhabitable surface protein (Gal/NAG lectin)
- It has two subunits—heavy (170 kDa) and—light (35 kDa) subunits linked by disulfide bridge. The 170 kDa subunit has a cytoplasmic and toxic membrane domain
- Lectin antigen is the principle virulence factor, present on the surface of trophozoites of pathogenic *E. histolytica* but not on nonpathogenic *E. dispar*. Its various pathogenic mechanisms are:
  - **Adhesion:** By binding to glycoprotein receptors on intestinal and hepatic surfaces
  - **Cytotoxicity:** By contact dependent cytolysis of the target cells by increasing the calcium level
  - **Complement resistance:** 170kDa subunit resembles CD59 (a human complement blocker) that prevent C5b-9 complex formation

**Amoebapore**

(5 kDa Amoebic pore forming protein): It inserts ion channels in the target cell membrane causing leakage of ions. Its equivalent found in *E. dispar* is called as *dispar* pores

**Cysteine proteases**

They degrade extracellular matrix, responsible for invasion, secreted only by trophozoites of pathogenic *E. histolytica*. Examples include histolysin, amoebapain and cathepsin B like proteases

**Hydrolytic enzymes**

Such as RNase, neutral protease and phosphatases—help in the destruction of the target tissue

**Neuraminidase and metallocollagenase**

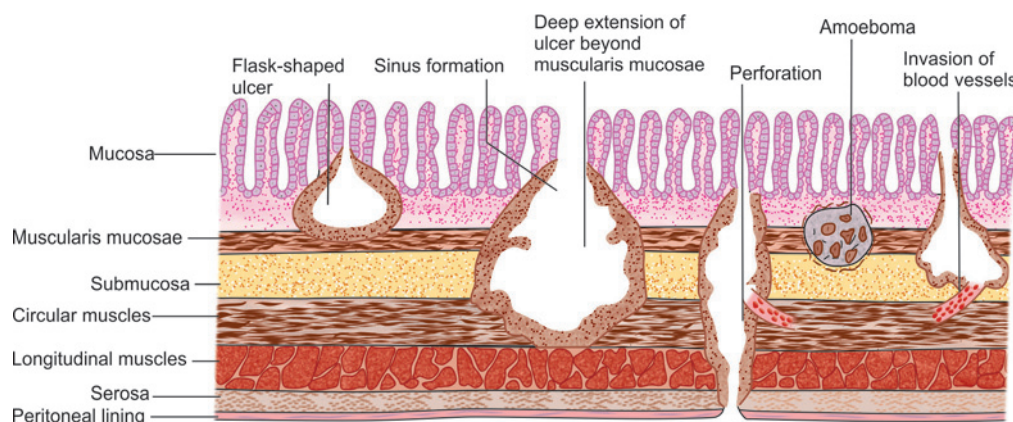
Help in invasion

in immunocompromised patients and in pregnancy

- **Amoebic appendicitis:** Results when the infection involves appendix
- **Intestinal perforation and amoebic peritonitis:** Occurs when the ulcer progresses beyond the serosa
- **Toxic megacolon and intussusception**

(segment of intestine invaginates into the adjoining intestinal lumen, causing bowel obstruction)

- **Perianal skin ulcers:** By direct extension of ulcers to perianal skin
- **Amoeboma (amoebic granuloma):** A diffuse pseudotumor like mass of granulomatous tissue found in rectosigmoid region

**Fig. 3.3:** Complications of intestinal amoebiasis (cross section of intestinal wall)

- **Chronic amoebiasis:** It is characterized by thickening, fibrosis, stricture formation with scarring and amoeboma formation.

### Pathogenesis of Extraintestinal Amoebiasis

Following 1–3 months of intestinal amoebiasis, about 5–10% of patients develop extraintestinal amoebiasis. Liver is the most common site (because of the carriage of trophozoites through the portal vein) followed by lungs, brain, genitourinary tract and spleen.

#### Amoebic liver abscess

The most common group affected: Adult males (male and female ratio is 9:1).

The most common affected site is the posterior-superior surface of the right lobe of liver. Abscess is usually single or rarely multiple (Fig. 3.4).

- Amoebic trophozoites occlude the hepatic venules; which leads to anoxic necrosis of the hepatocytes. Inflammatory response surrounding the hepatocytes leads to the formation of abscesses
- Microscopically the abscess wall is comprised of:
  - Inner central zone of necrotic hepatocytes without amoeba
  - Middle zone of degenerative hepatocytes, RBC, few leucocytes and occasionally amoebic trophozoites

- Outer zone: comprised of healthy hepatocytes invaded with amoebic trophozoites

- **Anchovy sauce pus:** Liver abscess pus is thick chocolate brown in color. The fluid is acidic and pH 5.2–6.7 and is comprised of necrotic hepatocytes without any pus cells and occasional amoebic trophozoites (mainly found in last few drops of pus as amoebae multiply in the wall of abscess).

#### Complications of amoebic liver abscess

With continuous hepatic necrosis, abscess may grow in various direction of liver discharging the contents into the neighboring organs (Fig. 3.4).

- Right sided liver abscess may rupture externally to skin causing **granuloma cutis** or rupture into lungs (pulmonary amoebiasis with trophozoites in sputum) or into the right pleura (**amoebic pleuritis**)
- Rupture of liver abscess below the diaphragm leads to subphrenic abscess and generalized peritonitis
- Left sided liver abscess may rupture into stomach or left pleura or pericardial cavity (**amoebic pericarditis**)
- Hematogenous spread can occur from liver affecting brain, lungs, spleen and genitourinary organs.

### Clinical Manifestations of Amoebiasis

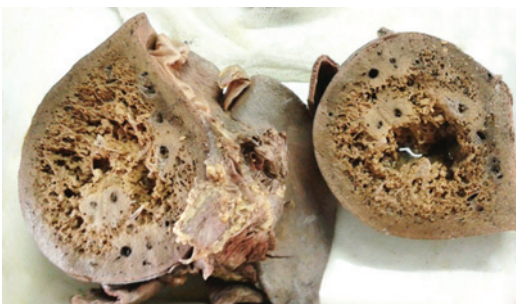
#### Asymptomatic amoebiasis

About 90% of infected persons are asymptomatic carriers and excrete cysts in their feces. Now it is confirmed that many of these carriers harbor *E. dispar*.

The remaining 10% of people (who are truly infected by pathogenic *E. histolytica*) produces a spectrum of diseases varying from intestinal amoebiasis to amoebic liver abscess.

#### Intestinal amoebiasis

Incubation period varies from one to four weeks. Intestinal amoebiasis is characterized



**Fig. 3.4:** Cross section of liver showing amoebic liver abscess (right side)  
Courtesy: HOD, Department of Pathology,  
Meenakshi medical college, Chennai

by four clinical forms:

1. **Amoebic dysentery:** Symptoms include bloody diarrhea with mucus and pus cells, colicky abdominal pain, fever, prostration, and weight loss. Amoebic dysentery should be differentiated from bacillary dysentery (Table 3.3)
2. **Amoebic appendicitis:** Presented with acute right lower abdominal pain
3. **Amoeboma:** It present as palpable abdominal mass
4. **Fulminant colitis:** Presents as intense colicky pain, rectal tenesmus, more than 20 motions/day, fever, nausea, anorexia and hypotension.

#### Laboratory Diagnosis

#### Intestinal amoebiasis

- Stool microscopy by wet mount, permanent stains, etc—detects cysts and trophozoites
- Stool culture
  - Polyxenic and axenic culture
- Stool antigen detection (copro-antigen)—CIEP, ELISA, ICT
- Serology
  - Amoebic antigen—ELISA
  - Amoebic antibody—IHA, ELISA and IFA
- Isoenzyme (zymodene) analysis
- Molecular diagnosis
  - Nested multiplex PCR and real time PCR

**Table 3.3:** Differences in stool characters between amoebic dysentery and bacillary dysentery

Character	Amoebic dysentery	Bacillary dysentery
<b>Pathology</b>		
Ulcer	Deep	Shallow
Margin	Ragged and undermined	Uniform
Intervening mucosa	Normal	Inflamed
Necrosis type	Pyknosis (pyknotic bodies)	Karyolysis (ghost cells)
Cellular response	Mononuclear cells	Polymorphonuclear cells
<b>Stool macroscopic feature</b>		
Number of motion	6–8/day	> 10/day
Amount	Copious amount	Small quantity
Color	Dark red	Bright red
Odor	Offensive	Odorless
Reaction	Acidic	Alkaline
Consistency	Not adherent to the container	Adherent to the container
<b>Stool microscopic feature</b>		
Red blood cells (RBCs)	In clumps	Discrete or in rouleaux
Pus cells	Few	Numerous
Macrophages	Few	Numerous, may contain RBCs, so can be mistaken as <i>E. histolytica</i>
Eosinophils	Present	Absent or rare
Charcot Leyden crystal	Present	Absent
Pyknotic body (nuclear remains of tissue cells and leukocytes)	Present	Absent
Ghost cell	Absent	Present
Organism detected	<i>E. histolytica</i> cyst or trophozoite	Bacteria ( <i>Shigella</i> )



**Amoebic liver abscess**

Presents with tender hepatomegaly, fever with weight loss, sweating and weakness, rarely jaundice, and cough.

**Laboratory Diagnosis of Intestinal Amoebiasis****Sample collection**

Stool is the specimen of choice. Minimum of three stool samples should be collected on consecutive days as amoebae are shed intermittently.

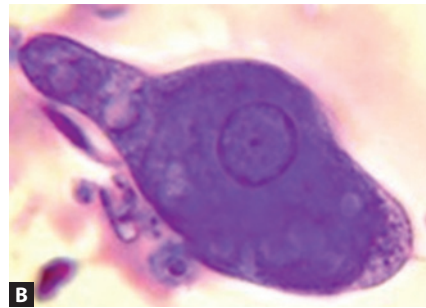
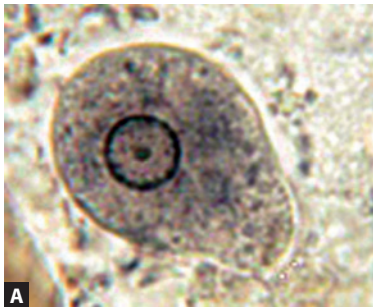
- Other samples include rectal exudates and rectal ulcer tissues collected by colonoscopy
- Stool specimen should be collected in wide mouthed clean container before administration of interfering substances like kaolin, bismuth, barium sulfate, anti-amoebic drugs

- It should be examined immediately within 1–2 hours of collection or can be preserved in polyvinyl alcohol or merthiolate iodine or formalin. However, refrigeration is not recommended.

**Stool microscopy**

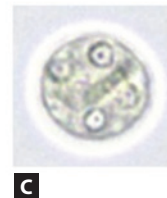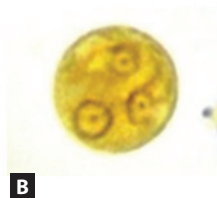
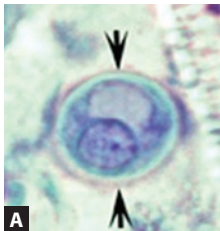
Direct examination of stool by saline and iodine mount is done to demonstrate:

- Trophozoites (Fig. 3.5)
  - Quadrinucleated cysts (Fig. 3.6)
- With saline mount, motility of the trophozoites can be appreciated while iodine mount clearly demonstrates the internal structures of the cyst
- Microscopy is poorly sensitive (25–60% with single sample) but the sensitivity increases to 85–95% when three stool samples are examined
  - When the amoeba load in stool is less (as in chronic amoebiasis or convalescent



**Figs 3.5 A and B:** Trophozoite of *Entamoeba histolytica* shows finger like pseudopodia and visible fine chromatin granule lining the nuclear membrane (A) hematoxylin stain; (B) trichrome stain

Source: Giovanni Swierczynski, Bruno Milanese. "Atlas of human intestinal protozoa Microscopic diagnosis" (with permission)



**Figs 3.6 A to C:** Cyst of *Entamoeba histolytica* (A) Giemsa stain shows uninucleated cyst (with glycogen vacuole); (B) iodine mount shows immature cyst (three nuclei); (C) saline mount shows mature cyst (with four nuclei)

Source: Giovanni Swierczynski, Bruno Milanese. "Atlas of human intestinal protozoa Microscopic diagnosis" (with permission)

stage), stool samples can be examined after concentration by formalin ether sedimentation method

- Stool or colonoscopy guided biopsy samples can also be examined by staining with permanent stains like trichrome, periodic acid Schiff (PAS), and hematoxylin and eosin (H & E) stains. Internal structures of cysts and trophozoites are well demonstrated by permanent stains (Figs 3.5 and 3.6 A)
- Cyst and trophozoites of *E. histolytica* are indistinguishable from that of *E. dispar* or *E. moshkovskii* except the presence of RBCs in trophozoites of *E. histolytica* (which might not be there after dysentery episode is over). So, the report should always be sent as “cyst or trophozoite of *E. histolytica*/*dispar*/*moshkovskii* found in the stool microscopy.”

### Stool culture

Culture methods are not routinely used for diagnosis. They are useful in research and teaching purpose. Culture methods are discussed in detail in Chapter 15.

**Polyxenic culture:** Culture media contains bacterial supplement, starch and serum providing nourishment to amoeba.

- Polyxenic medias are used for cultivation of amoeba from stool samples of chronic and asymptomatic carriers passing less number of cysts
- Stool culture shows 50–70% sensitivity and 100% specificity (gold standard)
- Various culture medias used are:
  - National Institute of Health (NIH) media
  - Boeck and Drbohlav egg serum medium containing Locke's solution
  - Balamuth's medium
  - Nelson's medium
  - Robinson's medium.

**Axenic culture:** It lacks bacterial supplement, e.g., diamond's medium. Axenic culture is useful when the bacterial flora interferes with the test results such as:

- Studying pathogenicity of amoeba
- Testing antiamoebic drug susceptibility
- Preparation of amoebic antigen in mass for serological tests
- For harvesting the parasite to determine the zymodeme pattern.

### Stool antigen detection (coproantigen)

Various tests used to demonstrate amoebic coproantigen in stool are:

- Counter current immune electrophoresis (CIEP)
- Enzyme-linked immunosorbent assay (ELISA)
- Immunochromatographic test (ICT)

Since, the antigens get denatured by stool preservatives, only fresh or frozen stool sample should be used.

- **ELISA detecting 170 kDa of lectin antigen** in stool shows more than 95% sensitivity and specificity. It can also differentiate pathogenic *E. histolytica* (lectin antigen positive) and nonpathogenic *E. dispar* (lectin antigen negative)
- **Immunochromatographic test** is available for the simultaneous detection of antigens specific for *Giardia lamblia*, *E. histolytica*/*E. dispar*, and *Cryptosporidium parvum* from stool, (commercially available as the triage parasite panel). It shows sensitivity (83–96%) and specificity (99–100%).

### Serology

**Amoebic antigen:** Amoebic antigen in serum is found only in patients with active infection and disappears after clinical cure, so its presence in serum indicates recent and active infection.

- ELISA is done using monoclonal antibody specific for lectin antigen—usually positive in early stage of the disease (sensitivity of 65%)
- ELISA is also available using monoclonal antibody specific for various other antigens like—serine rich *E. histolytica* protein like—serine rich *E. histolytica* protein (SREHP), lysine rich surface antigen and lipophosphoglycan (LPG)

- Other older methods for antigen detection include:
  - CIEP
  - Coagglutination test
  - Slide agglutination test.

**Amoebic antibody:** Serum antibodies appear only in the later stages of intestinal amoebiasis

- Various tests include:
  - ELISA
  - Indirect fluorescent antibody (IFA) test
  - Indirect hemagglutination (IHA) test
- IHA using crude antigens shows 10% sensitivity in asymptomatic cysts passers and 50–60% sensitivity in acute infection
- ELISA detecting antibody against lectin antigen shows 90% sensitivity in convalescent stage and 75–85% in early stage.

**Isoenzyme (zymodeme) analysis**

*E. histolytica* possesses several isoenzymes like malic enzyme, hexokinase, isomerase, and phosphoglucomutase.

- When these isoenzymes are subjected to electrophoresis, based on the electrophoretic pattern (zymodeme pattern) and mobility of the isoenzymes, *Entamoeba* can be speciated
- It can also be used to differentiate *E. histolytica* and *E. dispar*
- However, zymodeme analysis has a number of disadvantages such as: difficulty of performing the test, time-consuming and difficulty in preparing the antigens by culture.

**Molecular diagnosis**

Nested multiplex polymerase chain reaction (PCR) is available targeting small subunit ribosomal ribonucleic acid (rRNA) genes that can differentiate *E.histolytica*, *E.dispar* and *E.moshkovskii* with a sensitivity of nearing 90% and specificity of 90–100 % (Table 3.4)

Real-time PCR can be used as alternate to the conventional PCR. It is more sensitive, quantitates the parasite load and takes less time with less contamination rates.

**Table 3.4:** Sensitivity and specificity of various tests in the diagnosis of amoebiasis

Test	Specimen	Sensitivity		Specificity
		Amoebic dysentery	Amoebic liver abscess	
Microscopy (wet mount/permanent stain)	Stool	25–60%	< 10%	10–50%
	Liver abscess fluid	NA	< 25%	100%
Antigen detection (ELISA)	Stool	> 95%	Negative	> 95%
	Serum	65% (Early stage)	75% (late), 100% (early before treatment)	> 90%
	ALA fluid	Negative	100% (early before treatment)	90–100%
Antibody detection (ELISA)	Serum (acute infection)	75–85%	70–100%	> 85%
	Serum (convalescent infection)	> 90%	> 90%	> 85%
Culture and Isoenzyme analysis		50–70% (problems in case of mixed infections)	< 25%	Gold standard
PCR-based assays	Stool/ALA fluid	Stool > 90%	ALA fluid 100%	90–100%

Abbreviations: NA, not applicable; ELISA, enzyme linked immunosorbent assay; ALA, amoebic liver abscess; PCR, polymerase chain reaction



**Other nonspecific findings**

- Charcot Leyden crystals in stool
- Moderate leucocytosis in blood

**Laboratory Diagnosis** Amoebic liver abscess

- Microscopy—detects trophozoites
- Stool culture
- Antigen detection—ELISA
- Antibody detection—IHA, IFA, ELISA, CIEP, CFT, SAT, CIA, etc
- Histopathology—PAS stain
- Molecular diagnosis—PCR
- Ultrasonography

**Laboratory Diagnosis of Amoebic Liver Abscess**

**Microscopy**

Microscopy of liver pus can detect trophozoites (but never cyst) with less than 25% sensitivity. However, it confirms the diagnosis. Stool microscopy is not useful.

**Stool culture**

Though it is considered as the gold standard test, the sensitivity is low (<25%).

**Antigen detection**

Lectin antigen is usually absent in stool but can be demonstrated in serum (70% sensitive in late stage, 100% sensitive when tested before treatment), liver pus (100% sensitive when tested before treatment) and saliva (70% sensitive).

**Antibody detection**

Antibody detection methods like IHA, IFA, ELISA, CIEP, complement fixation test (CFT), staphylococcal adherence test (SAT) and carbon immune assay (CIA) are used in establishing the diagnosis of amoebic liver abscess

- However, antibody persists even after the cure, so it cannot differentiate recent and old infection
- IHA (using crude antigenic extract) and IFA with titer of 1:256 and 1:200 respectively are considered as significant

- ELISA is now replacing IHA and has reported sensitivity of 90% and specificity of 85%.

**Histopathology**

The trophozoites in pus aspirate can be demonstrated by histopathological stains. In PAS stain, organism appears bright pink with green blue background.

**Molecular diagnosis**

PCR done on amoebic liver pus approaches sensitivity of 100% and specificity of 90–100%.

**Ultrasonography**

Ultrasonography (USG) of liver shows the site of the abscess and its extension.

Treatment	Amoebiasis
	<ul style="list-style-type: none"> <li>• Metronidazole or tinidazole is the drug of choice for intestinal amoebiasis and amoebic liver abscess (Table 3.5)</li> <li>• Other measures include fluid and electrolyte replacement and symptomatic treatment.</li> </ul>

**Prevention**

Preventive measures are as follows:

- Avoidance of the ingestion of food and water contaminated with human feces
- Treatment of asymptomatic persons who pass *E. histolytica* cysts in the stool may help to reduce opportunities for disease transmission.

**Vaccination**

Till now, there is no effective vaccine licensed for human use. However, colonization blocking vaccines are under trial targeting three *E. histolytica* specific antigens such as: SREHP 170 kDa subunit of lectin antigen and 29kDa cysteine rich protein.

**NONPATHOGENIC INTESTINAL AMOEBAS**

**Entamoeba dispar**

*E. dispar* is morphologically indistinguishable (both cyst and trophozoite) from *E. histolytica*,

**Table 3.5** Antiamoebic drugs and their recommended therapeutic dosages

Drug	Dosage
<b>Luminal amoebicide</b>	
(that acts on amoeba present in gut lumen)	
• Paromomycin	30 mg/kg in three divided doses for 5–10 days
• Diiodohydroxyquin	–
• Diloxanide furoate	–
• Iodoquinol	650 mg orally thrice a day for 20 days
<b>Tissue amoebicide</b>	
(effective on intestinal wall, liver and other tissue)	–
• Emetine and dehydroemetine	
<b>Hepatic amoebicide</b>	
• Chloroquine	–
<b>Luminal and hepatic amoebicide</b>	
• Metronidazole	750 mg thrice a day for 5–10 days
• Tinidazole	2 g/day with food for 3 days
• Benzimidazole	–

so it may be considered as a subspecies of *E. histolytica*.

- It can be distinguished from *E. histolytica* by:
  - Zymodeme study (hexokinase isoenzyme pattern)
  - Molecular methods, PCR amplifying small subunit rRNA gene)
  - Detection of lectin antigen in stool
  - RBC inside trophozoites—present only in *E. histolytica*.
- It was described by Brumpt in 1993
- It is nonpathogenic, usually colonizes in the large intestine (10 times more than *E. histolytica*) but doesn't invade intestinal mucosa
- It grows well in polyxenic media, however, poorly grows on axenic media
- *E. dispar* doesn't induce antibody production.

**Entamoeba moshkovskii**

*E. moshkovskii* is also morphologically indistinguishable from *E. histolytica* and *E. dispar* (may be the third subspecies of *E. histolytica*).

- This species was first described from Moscow sewage by Tshalaia in 1941 and was thereafter reported to occur in many different countries including India
- It can be distinguished from *E. histolytica* by isoenzyme analysis, molecular methods and detection of lectin antigen
- Though it is a nonpathogen harboring in intestine but recent studies from Bangladesh and India have reported *E. moshkovskii* as a sole potential pathogen in patients presenting with gastrointestinal symptoms and/or dysentery, highlighting the need for further study to investigate the pathogenic potential of this organism.

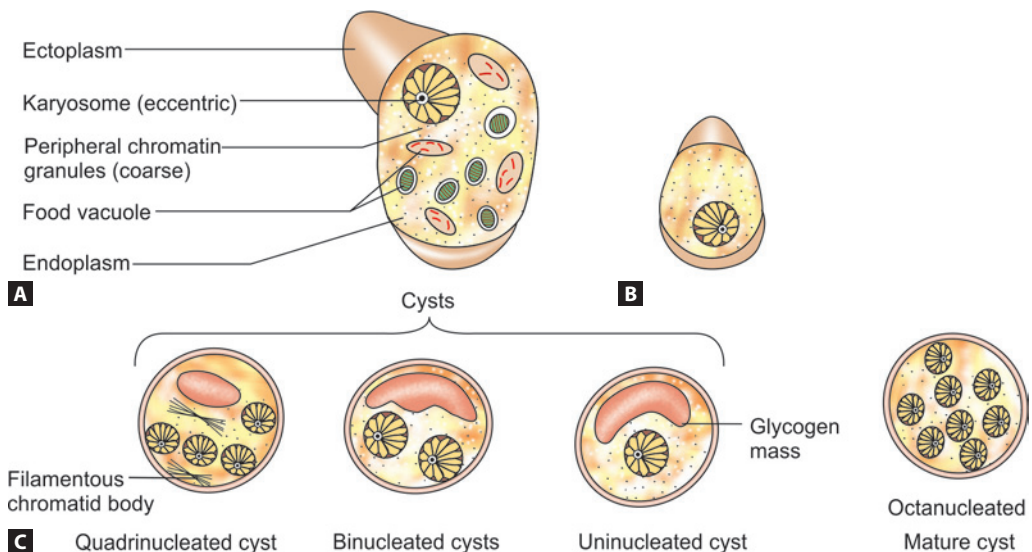
**Entamoeba coli**

*E. coli* is a nonpathogenic amoeba that colonizes the large intestine.

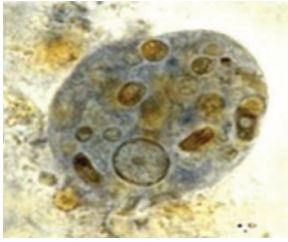
- The life cycle is similar to *E. histolytica*
- It has also three forms—trophozoites, precyst and cyst (Table 3.6, Figs 3.7, 3.8 and 3.9)
- It is frequently found in the stool samples of healthy individuals and should be differentiated from that of *E. histolytica* (Table 3.6).

**Table 3.6:** Differences between *Entamoeba histolytica* and *Entamoeba coli*

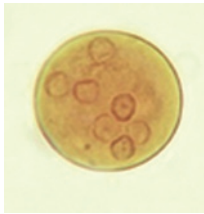
	<i>Entamoeba histolytica</i>	<i>Entamoeba coli</i>
<b>Trophozoite</b>		
Size	15–20 $\mu\text{m}$	20–25 $\mu\text{m}$
Motility	<ul style="list-style-type: none"> <li>• Very active and unidirectional purposeful motility</li> <li>• Pseudopodia with finger like projection</li> </ul>	<ul style="list-style-type: none"> <li>• Sluggish, nonpurposeful and aimless motility in any direction</li> <li>• Blunt pseudopodia</li> </ul>
Cytoplasm	Clearly differentiated to ectoplasm and endoplasm	Not differentiated
Cytoplasmic inclusions	RBC, leucocytes, tissue debris and bacteria	Same except it doesn't contain RBC
Nucleus	<ul style="list-style-type: none"> <li>• Karyosome is small and central</li> <li>• Nuclear membrane is thin and lined by fine chromatin granules</li> </ul>	<ul style="list-style-type: none"> <li>• Karyosome is large and eccentric</li> <li>• Nuclear membrane is thick and lined by coarse chromatin granules</li> </ul>
<b>Precyst</b>		
	10–20 $\mu\text{m}$ size, oval with blunt pseudopodium, no food vacuoles and nucleus same as trophozoite	Same as <i>E. histolytica</i> except size is 20 $\mu\text{m}$
<b>Cyst</b>		
Size	12–15 $\mu\text{m}$	15–25 $\mu\text{m}$
Nucleus	Same as trophozoite	Same as trophozoite
Number of nuclei	1–4	1–8
Chromatoid body	Thick bars with rounded ends	Filamentous and thread like ends



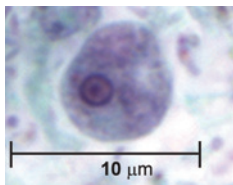
**Figs 3.7A to C:** *Entamoeba coli* (schematic diagram) (A) trophozoite; (B) precyst; (C) cyst



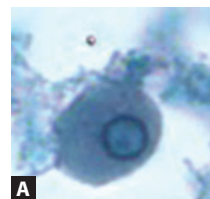
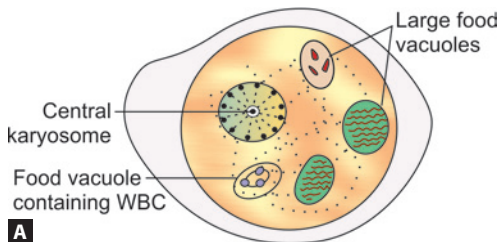
**Fig. 3.8:** Trophozoite of *Entamoeba coli* (Iron hematoxylin stain) shows nucleus with coarse peripheral chromatin and abundant food vacuoles in the cytoplasm containing fecal debris  
Source: Giovanni Swierczynski, Bruno Milanese. "Atlas of human intestinal protozoa Microscopic diagnosis" (with permission)



**Fig. 3.9:** Cyst of *Entamoeba coli* (Iodine mount) shows seven nuclei  
Source: Giovanni Swierczynski, Bruno Milanese. "Atlas of human intestinal protozoa Microscopic diagnosis" (with permission)



**Fig. 3.10:** *Entamoeba hartmanni* (smear showing trophozoite)  
Source: DPDx Image Library, Centre for Disease Control and prevention (CDC), Atlanta (with permission)



**Figs 3.11 A and B:** Trophozoite of *Entamoeba gingivalis* (A) schematic diagram; (B) trichrome stain  
Source: B- DPDx Image Library, Centre for Disease Control and prevention (CDC), Atlanta (with permission)

### Entamoeba hartmanni

It is also known as small race variant of *E. histolytica*, i.e. morphologically it is similar to *E. histolytica* but of smaller size (trophozoite is 8–10 µm and cyst is 6–8 µm (Fig. 3.10).

- It is nonpathogenic and colonizes the large intestine
- Its life cycle is similar to *E. histolytica*.

### Entamoeba gingivalis

It is the first parasitic amoeba of humans to be described; recovered from the soft tarter between the teeth.

- It is unusual in two respects:
  1. It inhabits in the mouth rather than in the large intestine
  2. Only trophozoite stage exists; no cystic stage
- Trophozoite is similar to that of *E. histolytica* trophozoite except (Fig. 3.11 A and B):
  - Smaller in size (10–15 µm)
  - Larger food vacuoles containing WBCs (only *Entamoeba* species that contains WBCs)
  - Nucleus similar to that of *E. histolytica*
- It is recovered from:
  - Vaginal secretions of women using intrauterine devices
  - Oral cavities of patients on radiation therapy and human immunodeficiency virus (HIV) infection
  - Patients with pyorrhea alveolaris
- Though it is considered nonpathogen, but still needs further study to determine its pathogenicity.

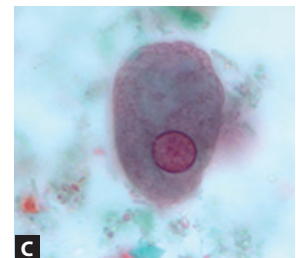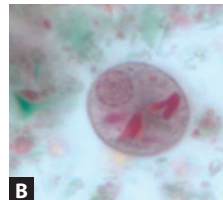
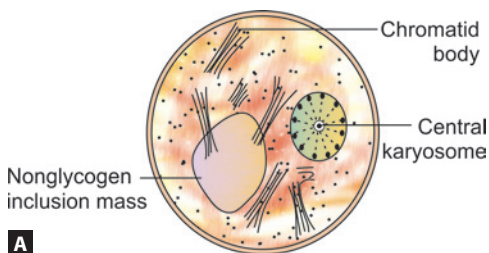
### Entamoeba polecki

It is a nonpathogenic amoeba usually found in the intestine of pigs and monkeys.

- However, human infection is rare, mainly restricted to Papua New Guinea where it is the most common intestinal amoeba in humans
- The trophozoites measure 10–12  $\mu\text{m}$  size, motility nonprogressive and sluggish (like *E. coli*) and contains one nucleus having central karyosome and fine peripheral chromatin (like *E. histolytica*) (Fig. 3.12)
- Cyst is of 5–11  $\mu\text{m}$  size and has one nucleus with features similar to that of trophozoite. It has many chromatoid bodies with thread-like ends (like *E. coli*) and cytoplasm has a large nonglycogen inclusion mass (Fig. 3.12).

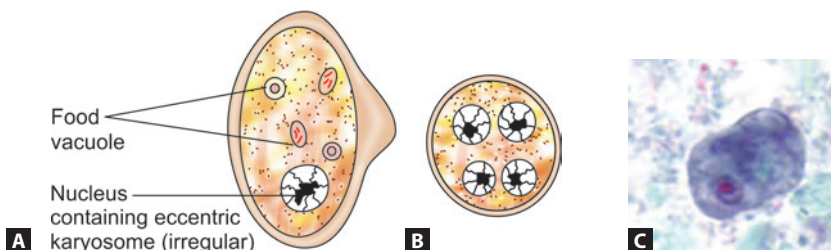
### Endolimax nana

It is a small (*nana* means small) nonpathogenic amoeba.



**Figs 3.12 A to C:** *Entamoeba polecki* (A) cyst (schematic diagram); (B) cyst (trichrome stain); (C) trophozoite (trichrome stain)

Source: B- and C- DPDx Image Library, Centre for Disease Control and prevention (CDC), Atlanta (with permission)



**Figs 3.13 A to C:** *Endolimax nana* (A and B) trophozoite and cyst (schematic diagram); (C) trophozoite (trichrome stain)

Source: C- DPDx Image Library, Center for Disease Control and Prevention (CDC), Atlanta (with permission)

- It is worldwide in distribution, frequently resides in the large intestine of humans and other animals
- Trophozoite measures 8–10  $\mu\text{m}$  in size and shows sluggish motility
- Cyst is 6–8  $\mu\text{m}$  in size and contains one to four nuclei. Cytoplasm doesn't have chromatoid body or glycogen vacuole
- Nucleus (both trophozoite and cyst)—Karyosome is eccentric and irregular; from which several achromatic strands extend to the nuclear membrane. There is no peripheral chromatin on nuclear membrane (Fig. 3.13).

### Iodamoeba butschlii

It is also worldwide in distribution though less common than *E. coli* and *E. nana*

- Trophozoite is 12–15  $\mu\text{m}$  in size. The ectoplasm and endoplasm are not differentiated. Cytoplasm is more vacuolated. Nucleus is similar to that of the cyst



- Cyst measures 10–12  $\mu\text{m}$  in size, round to oval and mostly is uninucleated
  - Nucleus has central karyosome surrounded by refractile chromatin granules (**bull's eye appearance or basket nucleus**). On permanent smear, the nucleus may appear to have a halo surrounding the karyosome
  - Cytoplasm of the cyst contains large iodine stained glycogen mass or iodophilic body (hence named as *Iodamoeba*) and no chromatoid body (Fig. 3.14).
- They differ from intestinal amoeba by:
  - Naturally found freely outside the host in the environment (soil and water)
  - Possesses plenty of mitochondria (intestinal amoeba lack mitochondria)
  - Nuclear membrane is distinct, not lined by peripheral chromatin granules and nucleolus is large, deep stained. (Intestinal amoeba has a delicate nuclear membrane, small pale stained nucleolus)
  - Cause opportunistic infection affecting central nervous system (CNS).

### ■ FREE-LIVING AMOEBAS

These amoebae are small, freely living, widely distributed in soil and water and can cause opportunistic infections in humans.

- Among the many genera of free-living amoebae that exist in nature, only four genera have an association with human disease. They are:
  1. *Naegleria fowleri* is a causative agent of primary amoebic meningoencephalitis (PAM)
  2. *Acanthamoeba* species causes granulomatous amoebic encephalitis (GAE) and amoebic keratitis in contact lens wearers
  3. *Balamuthia mandrillaris* causes GAE
  4. *Sappinia diploidea*

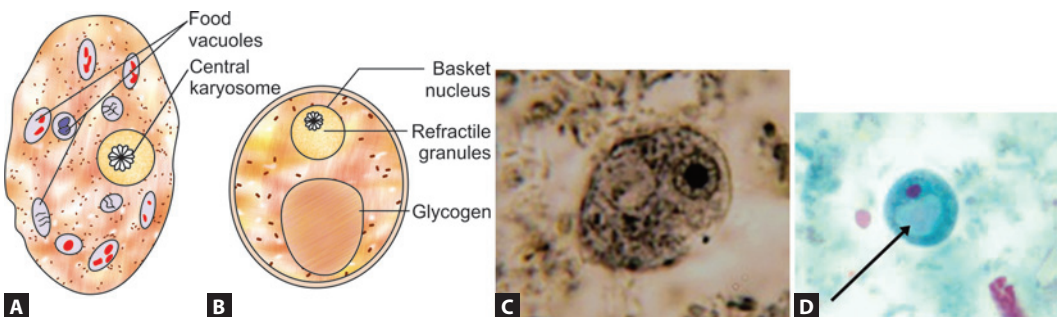
### Naegleria fowleri

*Naegleria* is a free-living amoeba, typically found in warm fresh water, such as ponds, lakes, rivers and hot springs. It is also found in soil, near warm-water discharges of industrial plants and swimming pools.

- Only one species, *N. fowleri*, is known to cause infection, although two other species, *N. australiensis* and *N. italica*, can cause infection in mice
- *N. fowleri* (also known as “the brain-eating amoeba”) is first described by physicians M. Fowler (hence named as *fowleri*) and R. F. Carter in Australia in 1965.

### Morphology

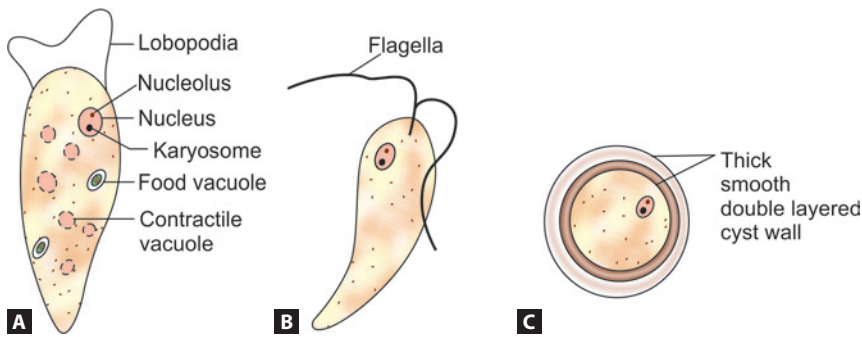
*Naegleria fowleri* exists in nature as cyst and trophozoite forms (Fig. 3.15).



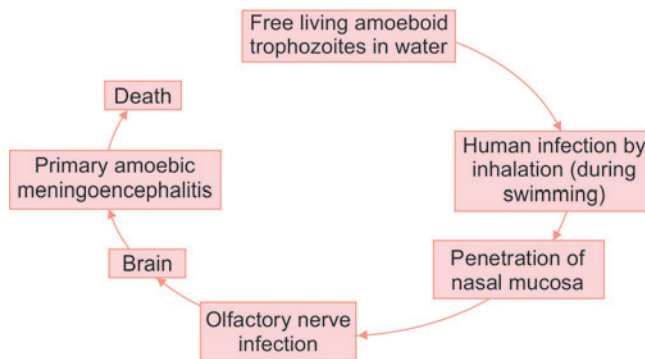
**Figs 3.14 A to D:** *Iodamoeba butschlii* (A and B) trophozoite and cyst (schematic diagram);

(C) trophozoite (Iron hematoxylin stain) shows basket nucleus and glycogen vacuole; (D) cyst (stained)

Source: C- Giovanni Swierczynski, Bruno Milanese. "Atlas of human intestinal protozoa microscopic diagnosis" (with permission); D- DPDx Image Library, Centre for Disease Control and prevention (CDC), Atlanta (with permission)



**Figs 3.15 A to C:** *Naegleria fowleri* trophozoite stage (schematic diagram)  
(A) amoeboid form; (B) flagellated form; (C) cyst stage



**Fig. 3.16:** Life cycle of *Naegleria fowleri*

### ***Trophozoite Stage***

The trophozoites occur in two forms, amoeboid and flagellated form. Both measure 8–15  $\mu\text{m}$ .

- **Amoeboid form:** It is the only recognizable form in humans. It possesses lobate pseudopodia (called as **lobopodia**). Cytoplasm is granular with food vacuoles; nucleus shows central karyosome and no peripheral chromatin. It is the only replicating form and it divides by binary fission (Fig. 3.15 A)
- **Flagellated form:** When the amoeboid forms are exposed to a change in ionic concentration such as placement in distilled water at 27–37°C, they transform to pear shaped flagellated form that possess two flagella at the broader end. This change occurs very quickly within a few hours. They show typical jerky or spinning motility.

When the flagella are lost, they revert back to amoeboid form (Fig. 3.15 B).

### ***Cyst Stage***

Cysts measure 7–15  $\mu\text{m}$  in size and is surrounded by a thick, smooth double wall. Nucleus is identical to that found in the trophozoite. Cysts are not found in tissue (humans) but can be grown in culture. (Fig. 3.15 C).

### ***Life Cycle and Pathogenicity (Fig. 3.16)***

**Infective form:** Amoeboid form is the invasive form and also the usual infective form of the parasite.

**Mode of transmission:** Man acquires infection by nasal contamination during swimming in fresh hot water bodies like ponds, river, swimming pools or lakes. Rarely, if the flagellated or cyst form enters, soon they revert back to amoeboid form.

- **CNS invasion:** The amoeboid form invades the nasal mucosa, cribriform plate and travels along the olfactory nerve to reach brain. The penetration initially results in significant necrosis and hemorrhages in the nasal mucosa and olfactory bulbs
- The two main mechanisms of pathogenesis are:
  1. Direct ingestion of the brain tissue by producing food cups or **amoebostome** into which the cytopathic enzymes are liberated
  2. Contact dependent cytolysis mediated by hemolytic proteins, cytolytins and phospholipase enzymes
- Gradually, it produces an acute suppurative meningoencephalitis, which becomes hemorrhagic and necrotic later
- Only amoeboid trophozoites are found in cerebrospinal fluid (CSF) and in brain tissue; but not other forms.

### Clinical Features (Primary Amoebic Meningoencephalitis)

*N. fowleri* causes acute suppurative fulminant infection of CNS known as primary amoebic meningoencephalitis (PAM).

- It is so named because to distinguish it from the secondary invasions of CNS caused by *E. histolytica*
- PAM usually occurs in healthy children or young adults with recent history of swimming in fresh hot water
- **Incubation period:** 1–2 days to 2 weeks after exposure. Clinical course is acute and fulminant
- The initial symptoms include changes in the taste and smell (due to olfactory nerve involvement) followed by headache, anorexia, nausea, vomiting, high fever, and signs of meningeal involvement like stiff neck and a positive Kernig's sign
- Secondary symptoms include confusion, hallucinations, lack of attention, ataxia, and seizures
- The mortality rate is nearly 98%. Death occurs within 7–14 days after exposure.

### Epidemiology

- The first case was reported from water and soil from Australia and from sewage sludge of India
- Till now more than 200 cases of PAM have been reported mainly from USA (> 90 cases) and also from other parts of the world like Czechoslovakia, Australia, New Zealand and Brazil
- In India, it is reported from Mangalore, Kolkata and Rajasthan (> 20 cases reported so far).

#### Laboratory Diagnosis

*Naegleria fowleri*

- Cerebrospinal fluid analysis
- Microscopy
- Culture on nonnutrient agar
- Isoenzyme analysis
- Molecular methods—PCR
- Imaging methods—CT and MRI

### Laboratory Diagnosis

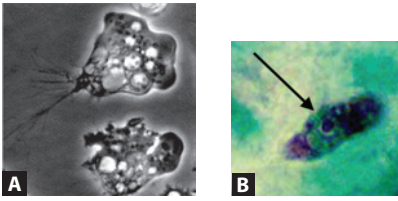
#### Cerebrospinal fluid analysis

CSF is thick purulent, with polymorpho-nuclear cells more than 20,000/μl, elevated protein and reduced sugar level (mimic bacterial meningitis).

#### Microscopy

- **Direct microscopy:** Motile amoeboid trophozoites can be demonstrated in wet mount preparation of CSF made with cover slip (counting chamber is not used as trophozoites in CSF mimic leucocytes) Other forms are not seen in CSF
- Care should be taken to differentiate the trophozoites from leukocytes. Motile trophozoite containing a spherical nucleus with large karyosome is the clue for identification
- **Phase contrast microscope** yields better result than light microscope. (Fig. 3.17A)
- **Histopathological staining** (Wright's or Giemsa) of CSF or brain biopsied tissue may demonstrate trophozoites with sky blue cytoplasm with a pink nucleus (Fig. 3.17B)





**Figs 3.17A and B:** *Naegleria fowleri* (A) saline mount (phase contrast microscopy) top—flagellated trophozoite, below—amoeboid trophozoite; (B) arrow shows amoeboid trophozoite (hematoxylin and eosin stain)

Source: DPDx Image Library, Centre for Disease Control and prevention (CDC), Atlanta (with permission)

- Refrigeration is not recommended if there is a delay in examining the CSF
- If the parasite load is low then CSF can be centrifuged at low speed (150 rpm for 5 minutes). Trophozoites are not damaged, they only lose their pseudopodia
- Trophozoites can also be demonstrated by **direct fluorescence antibody** staining of centrifuged CSF using monoclonal antibody.

### Culture

CSF sample can be cultivated on **nonnutrient agar (Page's saline and 1.5% agar)**, lawn cultured with bacterial supplement like *E. coli*. *Naegleria* feeds on bacteria and crawls over the lawn culture of *E. coli* to produce trails (**Trail sign**).

### Enflagellation test

When the scrapping of the nonnutrient agar is transferred to sterile tubes containing distilled water, *N. fowleri* undergoes transformation to a pear shaped flagellate form.

### Isoenzyme Analysis

Isoenzyme analysis has been developed for the specific identification of *N. fowleri* cultured from the CSF and brain specimens of the patients as well as from the environment samples.

### Molecular Methods

Both conventional PCR and nested PCR assays have been described for the identification of

*N. fowleri* targeting specific 5.8s rRNA genes and internal transcribed spacer genes

### Imaging Methods

Computed tomography (CT) scan and magnetic resonance imaging (MRI) show obliteration of cisterns, and diffuse enhancement around midbrain, subarachnoid space and over cerebrum.

Treatment	<i>Naegleria fowleri</i>
	<ul style="list-style-type: none"> <li>• No effective treatment is available for PAM</li> <li>• Amphotericin B has considerable anti <i>Naegleria</i> effect. Four cases were treated successfully with amphotericin B.</li> <li>• Other drugs like rifampicin, azithromycin and antifungals like miconazole and voriconazole are also found to be effective.</li> </ul>

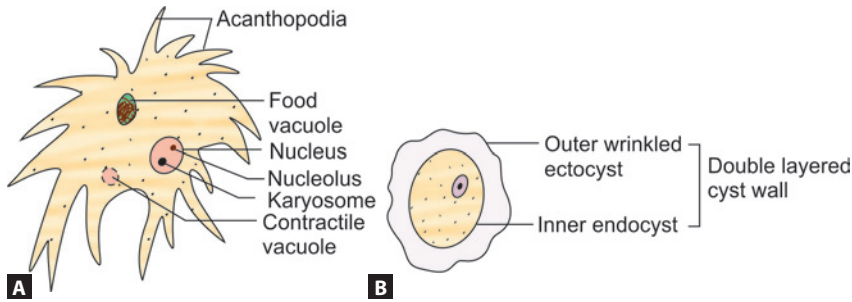
### Acanthamoeba

*Acanthamoeba* species is ubiquitous and present worldwide. They have been isolated from soil, fresh and brackish waters

- Griffin and Sawyer proposed the name in 1975. It is so named because of the spine like pseudopodia present in trophozoite (called as acanthopodia).
- More than 24 species have been identified. Important ones that cause human infection include *Acanthamoeba astronyxis*, *A. castellanii*, *A. culbertsoni* and *A. polyphaga*.
- It principally affects CNS and eye.
- **Reservoir for bacteria:** Approximately 20–24% of clinical and environmental isolates of *Acanthamoeba* harbor bacterial pathogens such as *Legionella* species *Mycobacterium avium* and *Listeria*, and may serve as a potential reservoir and act as **Trojan horse** of the microbial world.

### Morphology

*Acanthamoeba* species exists in nature as cyst and trophozoite forms. There is no flagellated form. (Fig. 3.18 A and B).



**Figs 3.18 A and B:** *Acanthamoeba* species (schematic diagram) (A) amoeboid form; (B) cyst

### Trophozoite

It is larger than *Naegleria* measuring 15–25  $\mu\text{m}$  size

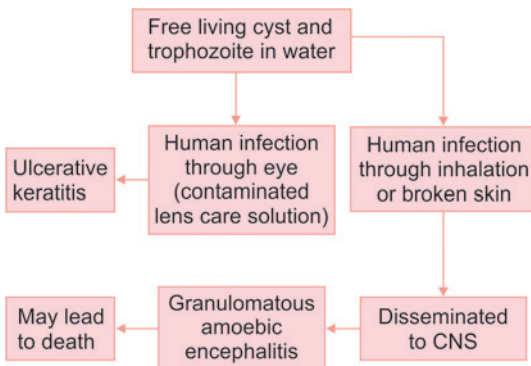
- It bears spine or thorn like pseudopodia (**acanthopodia**)
- **Nucleus:** Single with central karyosome and no peripheral chromatin.

### Cyst

It is double walled (outer wrinkled ectocyst and inner endocyst), nuclear characteristics are same as trophozoite.

### Life Cycle and Pathogenesis (Fig. 3.19)

- **Mode of transmission:** Man acquires infection by inhalational route by aerosol contaminated with cyst or trophozoite, or rarely by direct spread through broken skin or infected eye
- From lungs, trophozoites reach CNS by hematogenous route



**Fig. 3.19:** Life cycle of *Acanthamoeba* species

- It causes **GAE (granulomatous amoebic encephalitis)** in immunocompromised patients like HIV positive patients and keratitis in healthy individuals.
- **GAE** is characterized by:
  - **Insidious onset:** Incubation period varies from several weeks to months
  - **Chronic course:** Lasts for months to years
  - History of immunosuppression or underlying disease or trauma
  - **Pathology:** Focal granulomatous lesions in brain
  - Lymphocytosis of CSF
  - **Symptoms:** Confusion, dizziness, nausea, headache, stiff neck and sometimes seizure and hemiplegia
  - More than 200 cases of GAE due to *Acanthamoeba* have been reported so far, half of those from USA. From India, few cases are reported from Vellore and other places.
- **Amoebic keratitis** is characterized by:
  - Corneal spread with *Acanthamoeba* occurs following:
    - trauma (onset is rapid)
    - contact lens use; especially present in the lens cleaning solution (onset is slow)
    - contaminated water (onset is slow)
  - **Mechanism of adhesion:** Mannose binding protein on *Acanthamoeba* adheres to glycoprotein receptors on corneal epithelium

- Characterized by corneal infiltration and ulcerations, iritis, scleritis, hypopyon (pus in anterior chamber), severe pain, and loss of vision
- In India, it is commonly associated with contact lens users (75–93% of cases) However, a recent South Indian study done at Arvind eye hospital, Madurai had shown an increase trend of *Acanthamoeba* keratitis in noncontact lens wearers.
- In **HIV patients**, it produces:
  - GAE
  - Nasal ulcers
  - Cutaneous ulcers and abscess
  - Musculoskeletal abscesses.

#### Laboratory Diagnosis Acanthamoeba

- Direct microscopy
  - Wet mount examination of CSF or corneal scraping
  - Permanent staining of brain biopsy
- Culture on nonnutrient agar
- Indirect fluorescent antibody technique
- Molecular methods—PCR
- CSF examination—lymphocytosis

### Laboratory Diagnosis

#### Direct microscopy

- **Wet mount examination:** CSF or corneal

scrapping is done to demonstrate both cyst and trophozoites (Fig. 3.20A). Phase contrast microscope gives better results:

- Trophozoite is characterized by acanthopodia
- Cyst has two layers with an outer wrinkled ectocyst.

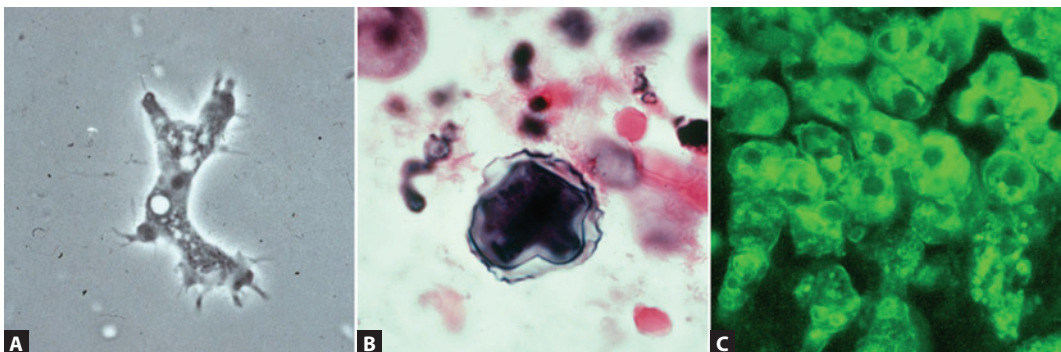
- **Permanent staining:** It is done for CSF and brain biopsy. Hematoxylin and eosin stain, trichrome stain are used to visualize characteristic morphology of trophozoite such as prominent nucleolus, contractile vacuole and cytoplasmic vacuole (Fig. 3.20B)
- **Calcofluor stain:** It is recommended to visualize the double walled cyst.

#### Indirect fluorescent antibody technique

Indirect fluorescent antibody technique (IFAT) with specific antisera can be used for speciation of *Acanthamoeba*. *A. culbertsoni* and *A. castellanii* are the most frequently identified species in CSF; whereas *A. polyphaga* and *A. castellanii* from corneal scraping (Fig. 3.20C).

#### Culture

- Various culture media used are nonnutrient agar with bacterial supplement, tryptic soy agar with horse blood, buffer charcoal yeast extract (BCYE) incubated at 30°C



**Figs 3.20 A to C:** *Acanthamoeba* species (A) trophozoite in CSF saline mount; (B) cyst in brain tissue (hematoxylin and eosin stain); (C) indirect fluorescent antibody technique of *Acanthamoeba* species viewed under UV microscopy

Source: DPDx Image Library, Centre for Disease Control and prevention (CDC), Atlanta (with permission)

- However, unlike *Naegleria*, *Acanthamoeba* is not readily isolated from culture (Table 3.7)
- Compared to centrifugation of CSF, Parasite detection rate is higher when CSF sample is cultured following filtration through cellulose membrane.

Treatment	Acanthamoeba
<b>Granulomatous amoebic encephalitis</b>	
<ul style="list-style-type: none"><li>• Unfortunately, there are no therapies with proven efficacy against this disease. Only three cases are survived so far</li><li>• They were treated with multidrug combinations that included cotrimoxazole, ketoconazole, pentamidine, flucytosine and rifampin. Surgery was done in one of those patients.</li></ul>	
<b>Amoebic keratitis</b>	
<ul style="list-style-type: none"><li>• Topical antiseptic agents such as a biguanide or chlorhexidine are used</li><li>• In severe cases of vision impairment may need penetrating keratoplasty.</li></ul>	

**Balamuthia mandrillaris**

*Balamuthia mandrillaris* is a free-living, heterotrophic amoeba that also causes GAE.

**History**

The name goes in the honor of the late Professor William Balamuth and it was first discovered in a pregnant mandrill (an old world monkey) at San Diego.

**Epidemiology**

It is distributed in the temperate regions of the world. Till now more than 150 cases are reported, half of them being from USA and South America. There are no reports from India yet.

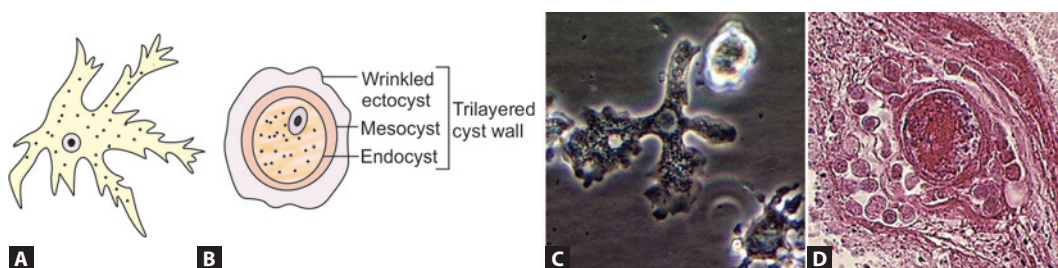
**Life Cycle**

It is similar to *Acanthamoeba*. It has trophozoite and cyst form (no flagellated form) (Fig. 3.21).

**Table 3.7:** Differences in the characteristics of *Naegleria* and *Acanthamoeba*

Character	<i>Naegleria fowleri</i>	<i>Acanthamoeba</i>
Disease	Primary amoebic meningoencephalitis	Granulomatous amoebic encephalitis • Ulcerative keratitis
Risk factor	Swimming in contaminated water	Immunodeficiency
Clinical course	Acute	Sub-acute to chronic
Pathology	Diffuse suppurative changes	Focal granulomatous inflammation
Trophozoites	<ul style="list-style-type: none"><li>• Two forms, amoeboid and flagellated form</li><li>• Lobated and blunt pseudopodium (lobopodia)</li><li>• 8–15 µm size</li></ul>	<ul style="list-style-type: none"><li>• One form, no flagellated form</li><li>• Thorn like pseudopodium (acanthopodia)</li><li>• 15–25 µm size</li></ul>
Cyst	<ul style="list-style-type: none"><li>• Not present in tissue or CSF</li><li>• Small (7–15 µm), thick and smooth double wall</li></ul>	<ul style="list-style-type: none"><li>• Can be found in tissue or CSF</li><li>• Larger (12–20 µm), thin wrinkled double wall</li></ul>
Spread	Direct neural spread	Hematogenous spread
CSF Leukocytes	Neutrophils	Lymphocytes
Culture	<ul style="list-style-type: none"><li>• Require bacterial supplement</li><li>• Don't grow with &gt; 0.4% NaCl</li></ul>	<ul style="list-style-type: none"><li>• May grow without bacterial supplement</li><li>• Not affected by NaCl</li></ul>
CT scan	Unremarkable (such as basal arachnoiditis), no specific feature	Space occupying lesion is seen

Abbreviations: CSF, cerebrospinal fluid; NaCl, sodium chloride; CT, computed tomography



**Figs 3.21A to D:** *Balamuthia mandrillaris* (A and B) trophozoite and cyst (schematic diagram); (C) trophozoite (saline mount); (D) cyst (hematoxylin and eosin stain)

Source: C- and D- DPDx Image Library, Centre for Disease Control and prevention (CDC), Atlanta (with permission)

- The trophozoite is approximately 30  $\mu\text{m}$ , irregular with finger like pseudopodia
- The cyst measures 6–30  $\mu\text{m}$ , surrounded by a three-layered cell wall (outer wrinkled ectocyst, middle mesocyst and inner thin endocyst), and an abnormally large, vesicular nucleus.

### Clinical Features

It may enter the body through the respiratory tract or through open wounds. In CNS, it causes GAE. It also can cause skin lesion.

### Diagnosis

#### Microscopy

CSF microscopy reveals trophozoites and cysts.

#### Culture

It can be cultured on monkey kidney cell line, HEp2, Vero and diploid macrophage cell line. It doesn't grow on agar plate culture coated with bacteria.

It can be differentiated from *Acanthamoeba* species by:

- Microscopy: Nucleus contains more than one nucleoli and cyst wall is tri-layered
- IFAT using specific antisera
- Culture on cell lines but not in agar plate
- PCR targeting mitochondrial small subunit rRNA gene.

### Sappinia diploidea

- It is newly recognized pathogenic free-living amoeba found in soil and water
- The characteristic feature is both trophozoite and cyst stages are binucleated
- The trophozoite is oval, measures 40–70  $\mu\text{m}$ . The mature cyst is round and measures 15–30  $\mu\text{m}$
- *S. diploidea* can be cultivated on nonnutrient agar plate coated with bacteria.
- Till now, only one case of amoebic encephalitis has been reported.

## EXPECTED QUESTIONS

### I. Write essay on:

- Describe the life cycle, pathogenesis and laboratory diagnosis of *Entamoeba histolytica*?
- List the free-living amoeba. Write in detail about their life cycle, pathogenesis and laboratory diagnosis?

### II. Write short notes on:

- Amoebic liver abscess
- Entamoeba dispar*

### III. Differentiate between:

- Features of *Entamoeba dispar* and *Entamoeba histolytica*
- Amoebic dysentery and bacillary dysentery
- Features of *Entamoeba coli* and *Entamoeba histolytica*
- Features of *Naegleria* and *Acanthamoeba*
- Features of *Acanthamoeba* and *Balamuthia*

Contd...



Contd...

**IV. Multiple choice questions (MCQs):**

**1. What would be the most likely manifestation of extraintestinal amoebiasis?**

- (a) High periodic fever
- (b) Draining skin lesion
- (c) Enlarged painful spleen
- (d) Tender, enlarged liver

**2. A 30-year-old female having habit of keeping her contact lenses in tap water. She noticed deterioration of vision and visited an ophthalmologist who diagnosed her with severe retinitis. Culture of the water as well as vitreous fluid would most likely reveal:**

- (a) *Naegleria*
- (b) *Entamoeba histolytica*
- (c) *Acanthamoeba*
- (d) *Entamoeba coli*

**3. Mature cyst of *Entamoeba histolytica* differs from *Entamoeba coli* by:**

- (a) Larger and uninucleated
- (b) Smaller and binucleated
- (c) Smaller and quadrinucleated
- (d) Larger and quadrinucleated

**4. All nonpathogenic amoebae live in the lumen of large intestine except:**

- (a) *Entamoeba dispar*
- (b) *Entamoeba moshkovskii*
- (c) *Entamoeba gingivalis*
- (d) *Endolimax nana*

**5. Lobopodia are seen in trophozoites of:**

- (a) *Naegleria fowleri*
- (b) *Acanthamoeba* species
- (c) *Balamuthia mandrillaris*
- (d) *Sappinia diploidea*

**6. *Balamuthia* causes:**

- (a) Primary amoebic meningoencephalitis
- (b) Granulomatous amoebic encephalitis
- (c) Keratitis
- (d) Liver abscess

**7. Infection with *Naegleria* can be acquired by:**

- (a) Swimming in lakes, ponds or pools containing infective forms
- (b) Parenteral route
- (c) Oro-genital contact
- (d) Feco-oral route

**8. Which is not a feature of CSF in primary amoebic meningoencephalitis?**

- (a) Purulent
- (b) Lymphocytic leucocytosis
- (c) High protein
- (d) Low glucose content

**9. Cysts of *Entamoeba histolytica* are formed in:**

- (a) Lumen of the large intestine
- (b) Tissues
- (c) Lumen of the small intestine
- (d) Epithelium of large intestine

**10. Infective form and invasive form of *Entamoeba histolytica* are:**

- (a) Trophozoite and quadrinucleated cyst
- (b) Quadrinucleated cyst and trophozoite
- (c) Both trophozoite
- (d) Both quadrinucleated cyst

**Answers**

1. (d)    2. (c)    3. (c)    4. (c)    5. (a)    6. (b)    7. (a)    8. (b)    9. (a)    10. (b)

# 4

## Flagellates—I (Intestinal and Genital)

### Chapter Outline

- Classification of flagellates
- *Giardia lamblia*
- *Trichomonas vaginalis*
- Other intestinal flagellates of minor importance
- Expected questions

### CLASSIFICATION OF FLAGELLATES

This group of parasites bear flagella as the organ of locomotion.

- Flagella are slender, long and thread-like extension of cytoplasm. Its intracellular portion is called as **axostyle** or **axoneme**. Flagella arise from kinetoplast (made up of copies of mitochondrial DNA) which in turn consists of:

- Blepharoplast or basal body or kinetosome from which flagellum arises
- Parabasal body, through which it passes as axostyle
- In most of the flagellates, the flagella are external except in *Dientamoeba fragilis* which bears internal flagellum.

### Taxonomic Classification

Different flagellates belong to three different phyla (Table 4.1).

**Table 4.1:** Taxonomic classification of flagellates

Kingdom	Subkingdom	Phylum	Class	Order	Genus
Protozoa	Archezoa	Metamonada	Trepomonadea	Diplomonadida	<i>Giardia</i>
				Enteromonadida	<i>Enteromonas</i>
			Retortamonadea	Retortamonadida	<i>Retortamonas</i> <i>Chilomastix</i>
		Parabasalia	Trichomonadea	Trichomonadida	<i>Trichomonas</i> <i>Pentatrichomonas</i> <i>Dientamoeba</i>
	Neozoa	Euglenozoa	Kinetoplastea	Trypanosomatida	<i>Leishmania</i> <i>Trypanosoma</i>

**Table 4.2:** Classification of flagellates based on habitat

Intestinal/genital flagellates	Habitat
<i>Giardia lamblia</i>	Duodenum and jejunum
<i>Enteromonas hominis</i>	Large intestine
<i>Retortamonas intestinalis</i>	Large intestine
<i>Chilomastix mesnili</i>	Cecum
<i>Dientamoeba fragilis</i>	Cecum and colon
<i>Trichomonas tenax</i>	Mouth (teeth and gum)
<i>Pentatrichomonas hominis</i>	Ileocecal region
<i>Trichomonas vaginalis</i>	Vagina and urethra
Blood and somatic flagellates	Habitat
<i>Leishmania</i>	Blood and tissue
<i>Trypanosoma</i>	Blood and tissue

**Classification Based on Habitat**

They are grouped into intestinal, genital and blood flagellates (Table 4.2).

**GIARDIA LAMBLIA**

**History**

*Giardia lamblia* was first observed by A.V. Leeuwenhoek in 1681 while examining his own stool.

The parasite was named after Dr F. Lambli of Prague and Prof. A.Giard of Paris in 1859.

They have described the morphology of the parasite in the human intestine.

**Classification**

*Giardia* can be differentiated to various species based on the origin of the host.

- *G. lamblia* infects humans and other mammals, *G.muris* in mice, *G.agilis* in amphibians, *G.psittaci* in birds and *G. microti* in voles
- *G. lamblia* can further be differentiated into seven genotypes from A to G, out of which genotype A and B usually infect humans.

**Epidemiology**

*G. lamblia* is worldwide in distribution, it is considered as one of the most common parasitic diseases, causing both endemic and epidemic intestinal disease and diarrhea.

**Geographical area:** More common in warm climate of tropics and subtropics.

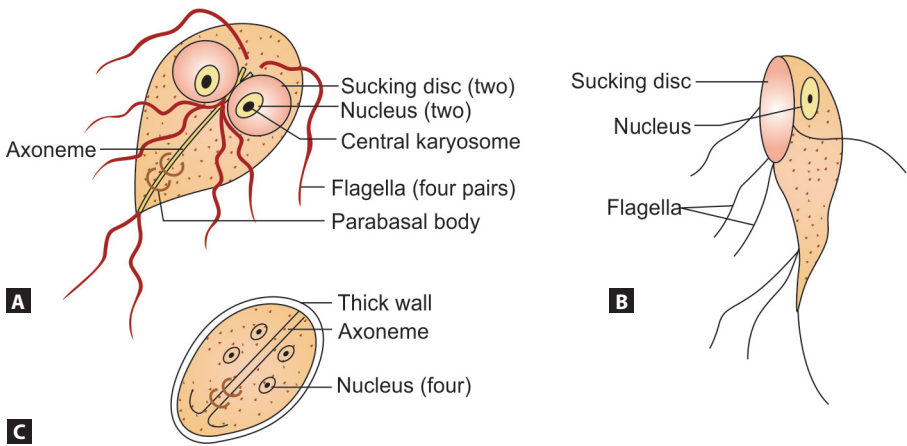
**In India:** Prevalence of giardiasis in children ranges from 2.67 to 32%. Majority of infections are caused by genotype B as reported by a South Indian study.

**Habitat**

Duodenum and upper part of jejunum.

**Morphology**

It occurs in two forms—(1) trophozoite and (2) cyst (Fig. 4.1).



**Figs 4.1 A to C:** *Giardia lamblia* (schematic diagram) (A) trophozoite front view; (B) trophozoite lateral view; (C) cyst



### Trophozoite

The trophozoite has a falling leaf-like motility, usually measures 10–20  $\mu\text{m}$  in length and 5–15  $\mu\text{m}$  in width.

- Shape:
  - In front view, it is pear shaped (or tear drop or tennis racket shaped) with rounded anterior end and pointed posterior end
  - Laterally, it appears as a curved portion of a spoon (sickle shaped)
- It is convex dorsally while the ventral surface has a concavity bearing a bilobed adhesive disc. Hence, it appears as sickle shaped in lateral view
- Trophozoite is bilaterally symmetrical; on each side from the midline it bears (Figs 4.1A and B):
  - One pair of nuclei
  - Pair of median bodies
  - Four pairs of basal bodies or blepharoplast (from which the axoneme arises)
  - Four pairs of flagella—two lateral, one ventral and one caudal pair of flagella
  - Pair of parabasal bodies (connected to basal bodies through which the axoneme passes)
  - Pair of axoneme or axostyle (the intracellular portion of the flagella).

### Cyst

*Giardia* cyst is oval shaped, measures 11–14  $\mu\text{m}$  in length and 7–10  $\mu\text{m}$  in width.

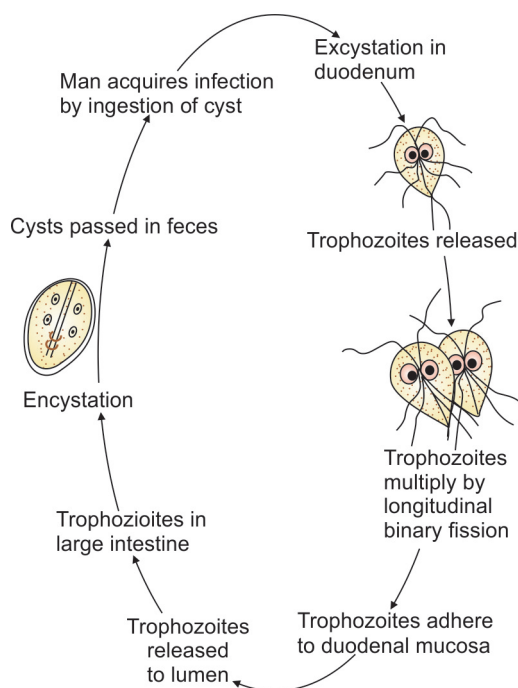
- It contains four nuclei and remnants of axonemes, basal bodies and parabasal bodies (Fig. 4.1C)
- It is the infective form as well as the diagnostic form of the parasite.

### Life Cycle (Fig. 4.2)

**Host:** *Giardia* completes its life cycle in one host.

**Infective form:** Mature cyst.

**Mode of transmission:** Man acquires infection by ingestion of food and water contaminated with mature cysts or rarely by sexual route (mainly in homosexuals).



**Fig. 4.2:** Life cycle of *Giardia lamblia*

### Development in Man

- **Excystation:** Two trophozoites are released from each cyst in the duodenum within 30 minutes of entry
- **Multiplication:** Trophozoites multiply by longitudinal binary fission in the duodenum.
- **Adhesion:** Trophozoites adhere to the duodenal mucosa by the bilobed adhesive ventral disc
  - This is achieved by the microtubules of median bodies, contractile proteins and lectins present on the surface of adhesive disc that bind to the intestinal receptors (sugar molecules)
- In active stage of the disease, sometimes the trophozoites are excreted in diarrhea stool
- **Encystation:** Gradually when the trophozoites pass down to large intestine, encystation begins
  - Promoting factors for encystation are the conjugated bile salts, alkaline pH and cholesterol starvation

- **Encystation specific vesicles (ESV)** appear in the cytoplasm that helps in processing and transportation of the cyst wall protein antigens to the exterior of the plasma membrane to synthesize the cyst wall
  - Encystation begins with retraction of the flagella followed by condensation of the cytoplasm and finally formation of the cyst wall
  - On maturation, nuclei divide to become four. The mature cysts excreted in feces can survive better in the environment and are infective to man.
- **Antigenic variation:**
    - *Giardia* undergoes frequent antigenic variation due to a cysteine rich protein on its surface called **variant surface protein (VSP)**
    - This helps the parasite in evasion of the host immune system and resistant to intestinal proteases which in turn leads to persistence of infection resulting into chronic and recurrent illness.

### Pathogenicity

- **Infective dose:** As few as 10–25 cysts can initiate the infection
  - **Risk factors:** Children are commonly affected. Other high-risk groups are elderly debilitated persons and patients with cystic fibrosis, poor hygiene, and immunodeficiency syndromes such as common variable hypoglobulinemia. However, association with acquired immunodeficiency syndrome (AIDS) patient is not been confirmed yet
  - **Several pathogenic mechanisms** have been postulated that include:
    - Trophozoites adhere to the duodenal mucosa and cause disruption of the intestinal epithelial brush border that leads to increase permeability and malabsorption
    - Very rarely, elaboration of enterotoxin such as cysteine rich surface protein 136 (CRP-136)
  - **Malabsorption:** There could be various types which include:
    - Malabsorption of fat (steatorrhea)—leads to foul smelling profuse frothy diarrhea
    - Disaccharidase deficiencies (lactate, xylose)—leading to lactose intolerance
    - Malabsorption of vitamin B12 and folic acid
    - Protein losing enteropathy
- **Clinical Features**

Clinical course of giardiasis can be divided into three stages:

    1. **Asymptomatic carriers:** Most infected persons are asymptomatic, harboring the cysts and spreading the infection
    2. **Acute giardiasis:**
      - Incubation period varies from 1 week to 3 weeks (average 12–20 days). Symptoms may develop suddenly or gradually
      - Common symptoms include diarrhea, abdominal pain, bloating, belching, flatus and vomiting
      - Diarrhea is often foul smelling with fat and mucus but no blood
      - The acute stage lasts for 1 week but usually resolves spontaneously. Very rarely, in some children may last for months
    3. **Chronic giardiasis:**
      - It may present with or without a previous acute symptomatic episode
      - Symptoms are intermittent and recurring
      - Common symptoms include recurrent episodes of foul smelling diarrhea, foul flatus, sulfurous belching with rotten egg taste, and profound weight loss leading to growth retardation
      - Uncommon symptoms such as—fever, presence of blood and/or mucus in the stools, and other signs and symptoms of colitis
      - Extraintestinal manifestations have been described, such as urticaria,

anterior uveitis, salt and pepper retinal changes and arthritis.

#### Laboratory Diagnosis *Giardia lamblia*

- Stool examination—detects cysts and trophozoites
- Entero-test
- Antigen detection in stool (copro-antigen)—ELISA, ICT
- Antibody detection in serum—ELISA, IFA
- Culture
- Molecular method—PCR
- Radiological findings—barium meal, X-ray

### Laboratory Diagnosis

#### Stool Examination

*Giardia* cysts can be demonstrated by iodine and saline wet mount preparations but they cannot differentiate active disease from carriers (Fig. 4.3).

Demonstration of the trophozoites with falling leaf like motility by saline mount indicates active stage of the disease (Fig. 4.4).

- *Giardia* adheres firmly to the duodenal mucosa by adhesive disc leading to intermittent shedding. Hence, repeated stool examination (at least three consecutive samples) should be done

- Sensitivity varies from 60% to 80% with one stool and more than 90% after three stools examination
- **Concentration techniques** like zinc sulfate floatation or formalin ether sedimentation methods are employed to increase the chance of detection
- **Duodenal sampling:** If stool examination is negative, then direct duodenal samples like aspirates (obtained by entero-test) or biopsy (done by endoscopy) should be processed.

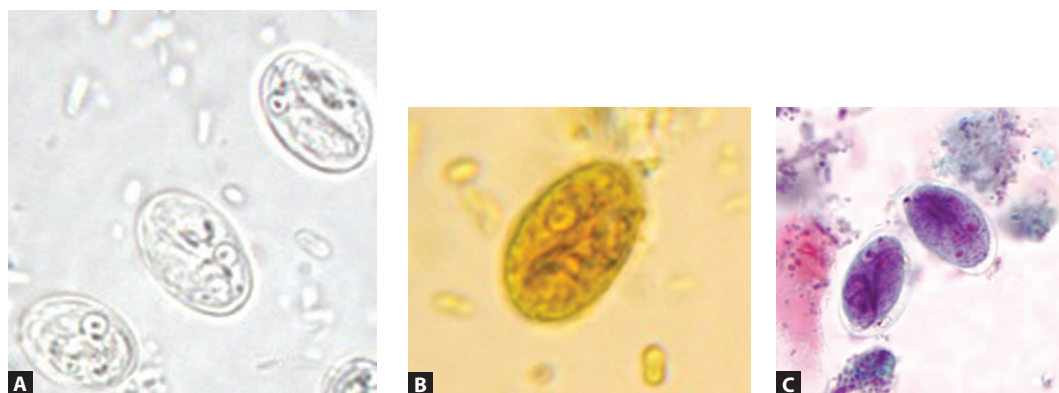
#### Entero-test

It uses a gelatin capsule attached to a thread.

- One end of the thread is attached to the inner aspect of the patient's cheek, and then, the capsule is swallowed
- Capsule gets dissolved in the intestine releasing the thread which is kept there for 4–6 hours to take the duodenal fluid
- Later, the thread is withdrawn and shaken in saline to release trophozoites which can be detected microscopically
- The entero-test is also useful in the search for other upper intestinal parasites such as *Strongyloides stercoralis* (Fig. 4.5).

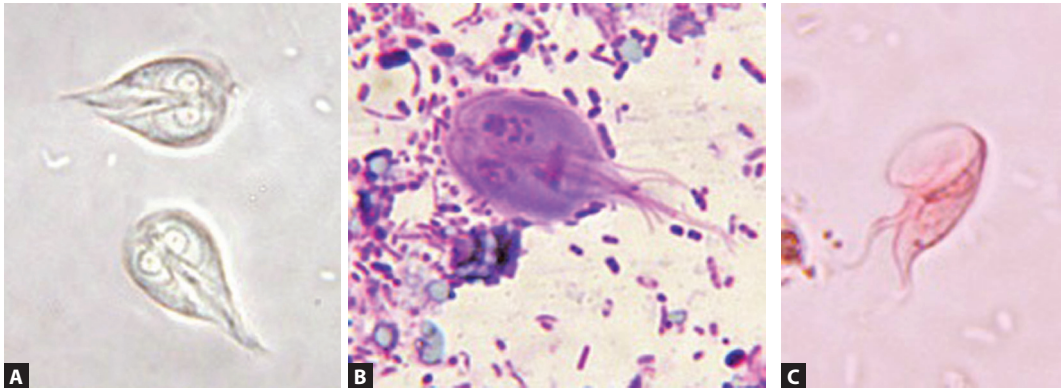
#### Antigen Detection in Stool (Copro-antigen)

The enzyme linked immunosorbent assay (ELISA) and direct fluorescent antibody



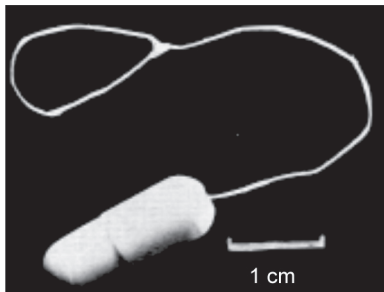
**Figs 4.3A and B:** Cysts of *Giardia lamblia* (A) saline mount (B) iodine mount (C) trichrome stain

Source: A- and B- Giovanni Swierczynski, Bruno Milanese "Atlas of human intestinal protozoa Microscopic diagnosis" (with permission); C- DPDx Image Library, Centre for Disease Control and prevention (CDC), Atlanta (with permission)



**Figs 4.4A to C:** Trophozoites of *Giardia lamblia* (A) saline mount front view; (B) Giemsa stain front view; (C) merthiolate iodine formalin (MIF) stain lateral view (spoon shaped)

Source: Giovanni Swierczynski, Bruno Milanesi. "Atlas of human intestinal protozoa Microscopic diagnosis" (with permission)



**Fig. 4.5:** Entero-test equipment showing duodenal capsule attached with thread at other end

tests are available using labeled monoclonal antibodies against cyst wall protein antigens. Both the tests are highly sensitive (90–100%) and specific (99–100%). They are very useful in microscopy negative samples and also in outbreak situations.

Rapid **immunochromatographic test** (commercial name **triage parasite panel**) has been developed that simultaneously detect antigens of *Giardia*, *Entamoeba histolytica* and *Cryptosporidium* with comparable sensitivity and specificity like ELISA. It is simple, easy to perform, doesn't require any costly instruments and can be done at peripheral laboratory.

### Antibody Detection

Both indirect fluorescent antibody (IFA)

and ELISA formats are developed to detect antibodies in serum.

- But unlike microscopy and antigen detection, presence of antibody cannot differentiate recent and past infection
- Hence, serology is only helpful for epidemiological purpose for estimating the prevalence of infection.

### Culture

*Giardia* can be cultivated in axenic media like Diamond's media used for *E. histolytica*.

- Culture is done for research purpose and to prepare the antigens
- It is not routinely used because of the difficulty in isolating *Giardia* from patient samples.

### Molecular Methods

Detection of *Giardia* nucleic acid by polymerase chain reaction (PCR) or by gene probes is highly sensitive and specific

- It is used to detect the parasites in water samples or to genotype the isolates from various mammalian hosts
- However, its use in routine laboratory diagnostics is limited.

### Radiological Finding

X-ray after barium meal is generally non-specific and may be positive in 20% of cases

- It shows an increased secretion and irregular thickening of small bowel folds
- Barium meal may also interfere with the stool examination. So, stool samples should be collected before the barium meal.

Treatment	Giardia lamblia
<ul style="list-style-type: none"> <li>• Metronidazole (250 mg thrice daily for 5 days) is usually effective in more than 90% of cases of giardiasis</li> <li>• Tinidazole (2 g once orally) is more effective than metronidazole</li> <li>• Nitazoxanide (500 mg twice daily for 3 days) is an alternative agent for treatment of giardiasis</li> <li>• Furazolidone is given to children and paromomycin can be given in pregnancy</li> <li>• In patients with AIDS and hypogammaglobulinemia, giardiasis is often refractory to treatment. Prolonged therapy with metronidazole (750 mg thrice daily for 21 days) has been successful.</li> </ul>	

## Prevention

Giardiasis can be prevented by:

- Improved food and personal hygiene
- Boiling or filtering of potentially contaminated water
- Treatment of asymptomatic carriers
- No vaccine is currently available.

## TRICHOMONAS

*Trichomonas* differ from other flagellates as they lack the cyst stage. They exist as only trophozoites.

- *Trichomonas* belongs to:
  - Class: Trichomonadea
  - Order: Trichomonadida
  - Family: Trichomonadidae
- Three species of *Trichomonas* infect humans. They are:
  1. *Trichomonas vaginalis* is the only pathogen. It resides in the genital tract
  2. *Pentatrichomonas hominis*: Non-pathogen, resides in large intestine
  3. *Trichomonas tenax*: Nonpathogen, resides in mouth (teeth and gum).

## TRICHOMONAS VAGINALIS

It is the most common parasitic cause of sexually transmitted diseases (STDs).

- Females are commonly affected than males
- It was first observed by Donne in 1836 from the purulent genital discharge of a female
- Though it is an eukaryote, its metabolism is similar to a primitive anaerobic bacteria
- Carbohydrate is utilized fermentatively. It is unable to synthesize fatty acid, sterols, purines and pyrimidines and hence depends on exogenous sources.

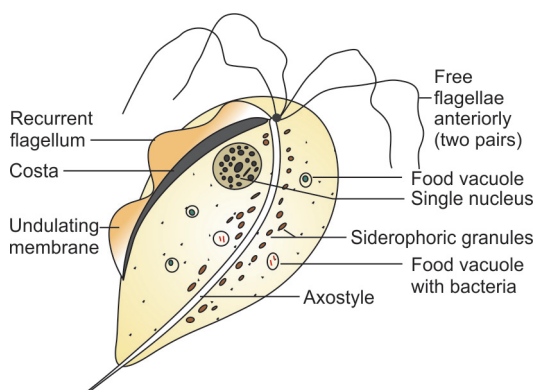
## Morphology

Trophozoites are the only stage, there is no cystic stage.

## Trophozoites

It is pear (pyriform) shaped, measures 7–23  $\mu\text{m}$  and 5–15  $\mu\text{m}$  wide (Fig. 4.6), resides in vagina and urethra of women and urethra, seminal vesicle and prostate of men.

- It shows characteristic jerky or twitchy motility in saline mount preparation
- It bears five flagella—four anterior flagella and one lateral flagellum called as **recurrent flagellum** as it curves back on the surface of the parasite and traverses as undulating membrane and stops halfway down the side



**Fig. 4.6:** Trophozoite of *Trichomonas vaginalis* (schematic diagram)



of the trophozoite. It doesn't come out free posteriorly

- The undulating membrane is supported on to the surface of the parasite by a rod like structure called as **costa**
- The axostyle runs down the middle of the trophozoite and ends in the pointed end of the posterior pole
- It has a single nucleus containing central karyosome with evenly distributed nuclear chromatin and the cytoplasm contains a number of siderophore granules along the axostyle
- The respiratory organelle is called as **hydrogenosome**.

### Life Cycle

Trophozoites are the infective stage as well as the diagnostic stage.

- Asymptomatic females are the reservoir of infection and transmit the disease by sexual route
- Trophozoites divide by longitudinal binary fission giving rise to a number of daughter trophozoites in the urogenital tract which can infect other individuals.

### Pathogenicity and Clinical Features

Trichomoniasis is the most common parasitic cause of STDs.

- It is worldwide in distribution and accounts for 10% of cases of vulvovaginitis
- Incubation period is variable (4–28 days)
- **Predisposing factors:**
  - Binding to the vaginal epithelium by various metabolic enzymes secreted by the trophozoites like adhesins, proteolytic enzymes, iron regulated proteins, erythrocyte binding proteins, etc
  - Vaginal pH of more than 4.5 facilitates infection
  - Hormonal levels
  - Coexisting vaginal flora
  - Strain and relative concentration of the organisms present in the vagina

- **Asymptomatic infection:** 25–50% of individuals are asymptomatic, harboring the trophozoites and can transmit the infection

- **Acute infection (vulvovaginitis):**

- Females are commonly affected and are presented as vulvovaginitis, characterized by profuse foul smelling purulent vaginal discharge. Discharge may be frothy (10% of cases) and yellowish green color mixed with a number of polymorphonuclear leukocytes
- Strawberry appearance of vaginal mucosa (**Colpitis macularis**) is observed in 2% of patients. It is characterized by small punctate hemorrhagic spots on vaginal and cervical mucosa
- Other features include dysuria and lower abdominal pain
- In males, the common features are nongonococcal urethritis and rarely epididymitis, prostatitis and penile ulcerations

- **Chronic infection:** In chronic stage, the disease is mild with pruritus and pain during coitus. Vaginal discharge is scanty, mixed with mucus

- **Complications:**

- Rarely it is associated with complications like pyosalpinx, endometritis, infertility, low birth weight and cervical erosions

#### Laboratory Diagnosis

*Trichomonas vaginalis*

- Direct microscopy
  - Wet saline mounting
  - Permanent stain
  - Acridine orange fluorescent stain
  - Direct fluorescent antibody test
- Culture— gold standard method
- Antigen detection in vaginal secretion— ELISA, ICT, etc
- Antibody detection—ELISA
- Molecular method—PCR
- Other supportive test
  - Raised vaginal pH
  - Positive whiff test

- There is also an association of increased HIV transmission and cervical dysplasia
- Respiratory distress may be seen in few cases.

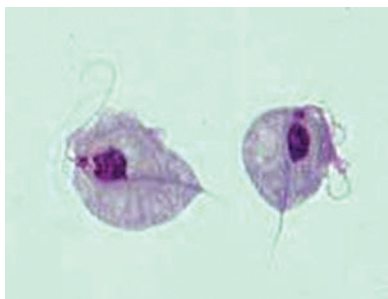
## Laboratory Diagnosis

### Direct Microscopy

- **Samples:** Vaginal, urethral discharge, urine sediment and prostatic secretions can be examined
- **Wet (saline) mounting** of fresh samples (within 10–20 minutes of collection) should be done to demonstrate the jerky motile trophozoites and pus cells. Its sensitivity is variable (40–80%)
- **Permanent stain:** Giemsa stain and Papanicolaou stain are routinely performed to demonstrate the morphology trophozoites (Fig. 4.7)
- **Acridine orange fluorescent stain** can be used. It is rapid and sensitive; comparable to wet mount
- **Direct fluorescent antibody test (DFA):** Trophozoites are detected by staining with fluorescent labeled monoclonal antibodies. DAF test is more sensitive (70–90%) than wet-mount examination.

### Culture

Culture is the gold standard method for diagnosis. It is highly sensitive 95% and specific (100%). It is positive even in microscopy negative samples.



**Fig. 4.7:** *Trichomonas vaginalis* trophozoite (Giemsa stain)  
Source: DPDx Image Library, Centre for Disease Control and prevention (CDC), Atlanta (with permission)

- Specimen should be collected properly and processed immediately (preferably bedside)
- Cultures should be incubated for 3–7 days or longer, followed by mounting of the culture to demonstrate the trophozoites
- If facilities are available, special container like “InPouch TV” can be used. It contains a specimen transport container, growth chamber for incubation and a slide for mounting
- Various culture medias can be used like:
  - Lash’s cysteine hydrolysate serum media
  - Diamond’s trypticase yeast maltose media
  - Cysteine peptone liver maltose media
  - Cell lines like McCoy cell line highly sensitive, can detect as low as three trophozoites/mL.

### Antigen Detection in Vaginal Secretion

Antigen detection methods are more sensitive than microscopy, easy to perform and indicates recent infection.

- A rapid immunochromatographic test (ICT) (dipstick) is available which shows result within 10 minutes, requires no sophisticated instruments. Compared to culture, it is 83% sensitive and 99% specific
- ELISA using monoclonal antibodies has been developed; which shows sensitivity of 89% and specificity of 97%.

### Antibody Detection

ELISA is available using whole cell antigen preparation and aqueous antigenic extract to detect antitrichomonal antibodies in serum and vaginal secretion of the patients.

However, antibodies persist for longer time, hence cannot differentiate between current infection and past infection. More over, its sensitivity is variable with variable antibody response.

### Molecular Methods

- PCR detecting *T. vaginalis* specific beta tubulin genes are available with sensitivity and specificity comparable to culture

- PCR based ELISA format has been developed for urine samples (sensitivity 90% and specificity 93%)
- Recently, transcription-mediated amplification test has been developed for urine and genital specimens from men and women.

**Other Supportive Tests**

- **Raised vaginal pH (> 4.5):** It is not specific as the vaginal pH is also raised in bacterial vaginosis. However, in vaginal candidiasis, the pH is not raised
- **Positive whiff test:**
  - Fishy odor is accentuated when a drop of 10% KOH is added to vaginal discharge due to production of amine
  - It is positive in more than 75% of cases
  - It is also positive in bacterial vaginosis
- Excess of polymorphonuclear neutrophils on wet mount (seen in more than 75% of cases).

Treatment	Trichomonas vaginalis
<b>Metronidazole or tinidazole</b>	
<ul style="list-style-type: none"><li>• Drug of choice, 2g, single dose is usually effective</li><li>• Both the sexual partners must be treated simultaneously to prevent reinfection, especially asymptomatic males</li><li>• <b>Resistance to metronidazole:</b><ul style="list-style-type: none"><li>➢ Resistance is rare but has been reported:<ul style="list-style-type: none"><li>- 2.5–10% to metronidazole</li><li>- Less than 1% to tinidazole</li></ul></li><li>➢ The mechanism of development of resistance to metronidazole is controlled by hydrogenosome</li><li>➢ Metronidazole requires hydrogen as an electron acceptor which is provided by hydrogenosome present in <i>T. vaginalis</i></li><li>➢ In metronidazole-resistant <i>T. vaginalis</i>, the expression levels of the hydrogenosomal enzymes like ferredoxin are reduced dramatically, which probably eliminates the ability of the parasite to activate metronidazole</li><li>➢ Resistance is relative and can be overcome with higher doses of oral metronidazole</li></ul></li></ul>	

**Prevention**

Trichomoniasis can be prevented by:

- Treatment of both the partners
- Safe sex practices like use of condoms
- Avoidance of sex with infected person
- **Vaccine:** There is no effective vaccine licensed so far. However, trials are going on targeting potential immunogenic antigens like 100 kDa protein.

**OTHER INTESTINAL  
FLAGELLATES OF MINOR  
IMPORTANCE**

**Pentatrichomonas hominis**

It is worldwide in distribution found both in warm and temperate climates.

- It is a harmless commensal present in large intestine
- Trophozoite is pyriform shaped, measures 5–15 µm long and 7–10 µm wide, similar to that of *T. vaginalis*, except that the undulating membrane is extended throughout the body.

**Trichomonas tenax**

*T. tenax* is a harmless commensal in the mouth (gum and tartar of the teeth).

- However, few cases of respiratory infection and thoracic abscesses are reported from Western Europe particularly in patients with cancer or other underlying lung disease
- The trophozoite is similar to *P. hominis* (undulating membrane is extended throughout the body); but it is smaller (5–12 µm long and 5–10 µm wide) and more slender
- Prevalence may vary from 0% to 0.25% depending on the oral hygiene.

**Chilomastix mesnili**

*Chilomastix mesnili* is a harmless commensal of cecum and colon in man.



- It is worldwide in distribution, found more frequently in warm climate
- It has two stages—trophozoites and cyst stages (Fig. 4.8):

### 1. Trophozoite:

- It is pear-shaped, measuring 10–15  $\mu\text{m}$  in length and 4–6  $\mu\text{m}$  in width
- At the anterior end, there is a single nucleus and a distinct groove present near the nucleus called as cytostome
- It has four flagella—three anterior and one in cytostome
- It shows stiff, rotary movement
- Cytostome is supported by two cytotosomal fibrils right one is prominent and curved, left one is straight and less conspicuous (Figs 4.8A and C)

### 2. Cyst:

- It is the infective stage
- It is lemon shaped with a narrow anterior end, surrounded by a cyst wall
- It measures 6–10  $\mu\text{m}$  in length and 4–6  $\mu\text{m}$  in width
- Bears a single nucleus; cytoplasm is densely granular, separated from the cyst wall at the anterior end
- Remnant of the curved cytotosomal fibrils can be seen, called as shepherd's crook (Figs 4.8B and D)

- Both the forms can be demonstrated by permanent staining of the stool samples
- Since it's a commensal so no treatment is required
- Prevention depends on improved personal hygiene.

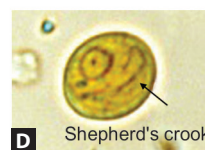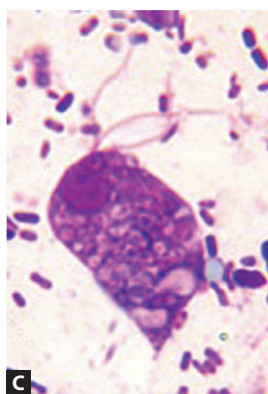
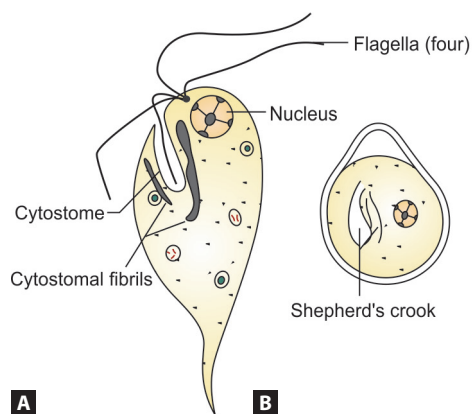
## Enteromonas hominis

*Enteromonas hominis* is considered as a non-pathogenic commensal that is rarely encountered in man's in the large intestine (cecum).

- It is reported from both tropical (warm) and temperate (cold) climate
- It exists in two forms—(1) trophozoite and (2) cyst

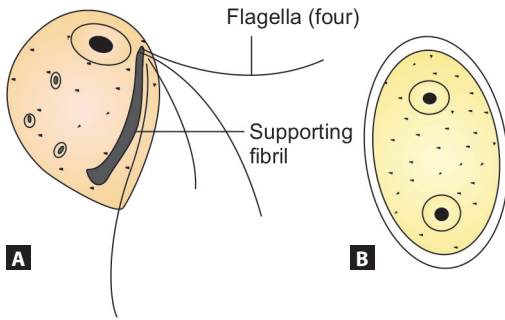
### 1. Trophozoite:

- Oval to pear shaped, smaller in size, measuring 8–9  $\mu\text{m}$  long and 5–6  $\mu\text{m}$  wide
- It possesses four flagella—three anterior and one recurrent. The recurrent flagellum extends free posteriorly and supported by a darkly stained fibril
- It shows jerky forward movement
- Nucleus is placed anteriorly and there is no cytosome
- Cytoplasm is vacuolated and contains numerous bacteria (Fig. 4.9A)



**Figs 4.8A to D:** *Chilomastix mesnili* (A and B) trophozoite and cyst (schematic diagram); (C) trophozoite (Giemsa stain); (D) cyst (iodine stain)

Source: C- and D- Giovanni Swierczynski, Bruno Milanese "Atlas of human intestinal protozoa Microscopic diagnosis" (with permission)



**Figs 4.9A and B:** *Enteromonas hominis* (schematic diagram) (A) trophozoite; (B) cyst

## 2. Cyst:

- It is the infective stage
- It is oval, measuring 6–8  $\mu\text{m}$  long and 4–6  $\mu\text{m}$  wide
- Possesses one to four nuclei, binucleated being most common (two nuclei lie at opposite poles) (Fig. 4.9B)
- It resembles like the cyst of *Endolimax nana*
- Infection is transmitted by ingestion of contaminated cyst
- Both the forms can be demonstrated by permanent staining of the stool samples
- Since it is a commensal, no treatment is required
- Prevention depends on improved personal hygiene.

## Retortamonas intestinalis

*Retortamonas intestinalis* is a harmless commensal found less commonly in human's large intestine.

- It is reported from both tropical (warm) and temperate (cold) climate
- It exists in two forms—trophozoite and cyst

## 1. Trophozoite:

- Elongated pyriform or oval shaped, smaller in size, measuring 6–7  $\mu\text{m}$  long and 3–4  $\mu\text{m}$  wide
- It bears two flagella—one anterior and one posterior. It shows jerky movement
- It has a cytostomal groove anteriorly

with cystostomal fibrils and a single nucleus (Fig. 4.10A)

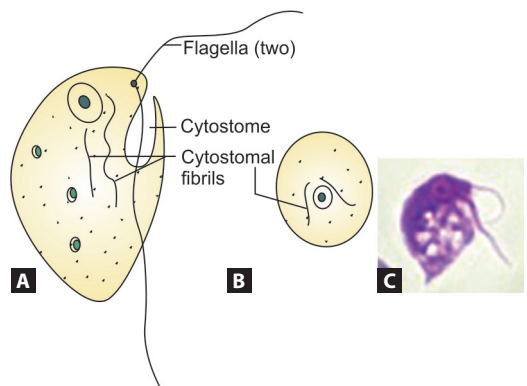
## 2. Cyst:

- It is the infective stage
- It is pear shaped, measuring 4–7  $\mu\text{m}$  long and 5  $\mu\text{m}$  wide
- It resembles like the cyst of *Chilomastix* having single nucleus and cytostome with supporting fibrils extends above nucleus (Fig. 4.10B)
- Infection is transmitted by ingestion of contaminated cyst
- Both the forms can be demonstrated by permanent staining of the stool samples
- Since it is a commensal, there is no therapy indicated
- Prevention depends on improved personal hygiene.

## Dientamoeba fragilis

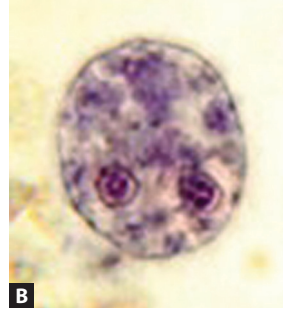
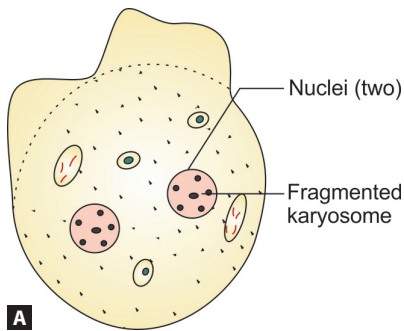
*Dientamoeba fragilis* is a common commensal that lives in the lumen of the cecum and upper colon of humans.

- It was initially thought to be an amoeba as it bears no external flagella but recently, by electron microscopic studies; it is reclassified as an amoeboflagellate as the



**Figs 4.10A and B:** *Retortamonas intestinalis* (A and B) trophozoite and cyst (schematic diagram); (C) trophozoite (Giemsa stain)

Source: C- Giovanni Swierczynski, Bruno Milanesi "Atlas of human intestinal protozoa Microscopic diagnosis" (with permission)



**Figs 4.11A and B:** Trophozoite of *Dientamoeba fragilis* (A) schematic diagram; (B) iron hematoxylin stain showing two nuclei with fragmented karyosome

Source: B- Giovanni Swierczynski, Bruno Milanese "Atlas of human intestinal protozoa microscopic diagnosis" (with permission)

flagellum is internal. It closely resembles *Histomonas*, a parasite infecting turkeys.

- It is cosmopolitan in distribution with incidence rate varies from 1.4% to 19%.
- Higher incidence is reported in children.

### Morphology and Life Cycle

Trophozoite is the only stage. Cyst stage is not been confirmed till date.

#### Trophozoite

- It is irregular in shape (amoeboid), relatively small, varying from 9  $\mu\text{m}$  to 12  $\mu\text{m}$
- **Nucleus:** one to four in number (commonly two nuclei in 60–80% of cases, hence named as *Dientamoeba*) (Figs 4.11A and B)
- The nuclear chromatin is usually fragmented into three to five granules (hence named as **fragilis**), no peripheral chromatin on the nuclear membrane
- The cytoplasm is usually vacuolated and may contain ingested debris as well as some large uniform granules

The life cycle is not fully understood. Trophozoites are the infective forms; transmitted by feco-oral route. They multiply in the large intestine and excreted in feces.

### Pathogenesis

This is controversial; the pathogenic status is not well defined.

- Some authors believe that there may be two distinct genotypes one of which may be pathogenic
- The organism has been reported in association with mucous diarrhea, abdominal pain and tenderness, nausea, vomiting, and low-grade fever.

#### Laboratory Diagnosis

*Dientamoeba fragilis*

- Stool examination
- Antigen detection in stool
- Antibody detection in serum—IFA

### Laboratory Diagnosis

#### Stool examination

Trophozoite doesn't survive for longer time hence the fresh direct wet preparations should be examined immediately or stained by permanent stains.

- The recommended stains are Fields', giemra and iron hematoxylin stain
- Trophozoites are destroyed in a formol-ether concentration technique.

**Antigen Detection in Stool**

Both immunofluorescence and enzyme immunoassays are commercially available.

**Antibody detection in serum**

It can be detected by IFA technique.

**Treatment****Dientamoeba fragilis**

Tetracycline or metronidazole is effective. However, antimicrobial drugs are not preferred as its pathogenicity is not confirmed. Symptomatic treatment is sufficient.

**EXPECTED QUESTIONS****I. Write short notes on:**

- (a) Giardiasis
- (b) Trichomoniasis
- (c) *Dientamoeba fragilis*
- (d) *Chilomastix mesnili*

**II. Multiple choice questions (MCQs):**

**1. How many pairs of flagella are present in the trophozoite of *Giardia lamblia*?**

- (a) One
- (b) Two
- (c) Four
- (d) Eight

**2. *Giardia lamblia* resides in:**

- (a) Sigmoid colon
- (b) Colon
- (c) Duodenum
- (d) Vagina

**3. Which is the most common cause of steatorrhea:**

- (a) *Ascaris lumbricoides*
- (b) *Giardia lamblia*

(c) *Entamoeba histolytica*

(d) *Enteromonas hominis*

**4. Trophozoites of which of the following bear two nuclei with fragmented karyosome?**

- (a) *Dientamoeba fragilis*
- (b) *Chilomastix mesnili*
- (c) *Retortamonas intestinalis*
- (d) *Enteromonas hominis*

**5. Diagnosis of which of the following parasite uses Entero-Test?**

- (a) *Cyclospora* species
- (b) *Entamoeba histolytica*
- (c) *Giardia lamblia*
- (d) *Dientamoeba fragilis*

**6. Which of the following parasite doesn't have a cyst stage?**

- (a) *Enteromonas hominis*
- (b) *Dientamoeba fragilis*
- (c) *Giardia lamblia*
- (d) *Chilomastix mesnili*

**Answers**

1. (c)    2. (c)    3. (b)    4. (a)    5. (c)    6. (b)

# 5

## Flagellates—II (Hemoflagellates)

### Chapter Outline

- Introduction
- Morphology of hemoflagellates
- Leishmania
  - Old world leishmaniasis
  - New world leishmaniasis
- Trypanosoma
  - Trypanosoma cruzi
  - Trypanosoma brucei complex
- Expected questions

### INTRODUCTION

Hemoflagellates are the flagellated protozoa that are found in peripheral blood circulation. They complete their life cycle in two hosts, i.e. vertebrate host and insect vector; therefore, called as **digenetic** or **heteroxenous parasites**. Hemoflagellates of medical importance belongs to:

- Phylum: Euglenozoa
- Class: Kinetoplastea
- Order: Trypanosomatida
- Family: Trypanosomatidae
- Genera: *Leishmania* and *Trypanosoma*.

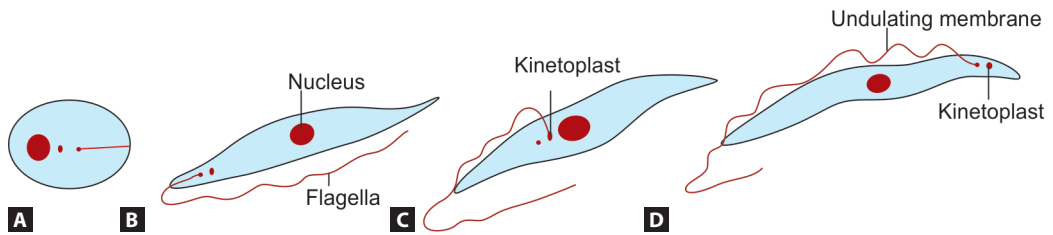
### MORPHOLOGY OF HEMOFLAGELLATES

Hemoflagellates have an oval to elongated body, nucleus, and a single flagellum arising from kinetoplast.

- **Kinetoplast:** It consists of blepharoplast and parabasal body connected by a delicate fibril (cytoskeleton). It lies tangentially or

at right angle to the nucleus. It represents multiple copies of mitochondrial DNA

- **Axoneme (or axostyle):** It extends from blepharoplast to the cell wall. It represents the intracellular portion (root) of flagellum
- Based upon arrangement of flagellum, they exist in four morphological stages—(1) amastigote, (2) promastigote, (3) epimastigote and (4) trypomastigote. Names are ended with a suffix “**mastigote**” (Greek word Mastix means whip) (Fig. 5.1)
- 1. **Amastigote form:** Round to oval, lacks flagellum, found in reticuloendothelial cells of man infected with *Leishmania* and *Trypanosoma cruzi*
- 2. **Promastigote form:** Lanceolate shaped; kinetoplast is anterior to nucleus (antenuclear kinetoplast). Flagellum arises from the anterior end. It is found in the mid gut of insect vector. This is the infective stage of *Leishmania* to man
- 3. **Epimastigote form:** Elongated, kinetoplast is placed close to the nucleus (juxtenuclear kinetoplast). Flagellum arises from the



**Figs 5.1A to D:** Various morphological forms of flagellates (schematic diagrams) (A) amastigote; (B) promastigote; (C) epimastigote; (D) trypomastigote

lateral side and traverses the body as a short undulating membrane and comes out from the anterior end. This form is seen for *Trypanosoma* in insect vector

4. **Trypomastigote form:** Elongated and spindle shaped with central nucleus. Kinetoplast lies near the posterior end. Flagellum arises posteriorly and runs as long undulating membrane. It is the infective stage of *Trypanosoma* found in insect vector and peripheral blood of humans.

## LEISHMANIA

Leishmaniasis is caused by the obligatory intracellular protozoa of the genus *Leishmania*. Primarily it affects the reticulo-endothelial system of the host.

- *Leishmania* species produce widely varying group of clinical syndromes ranging from self-healing cutaneous ulcers to fatal visceral disease
- Leishmaniasis is mainly a zoonotic disease affecting dogs, foxes, jackals and rodents. Animal reservoir plays a major role for transmission; except in Indian subcontinent where it is anthrophilic affecting only humans
- The parasite is transmitted by bite of the female sandfly vector (Fig. 16.5).

## Classification of Leishmaniasis

*Leishmania* has two subgenera *L. Leishmania* and *L. Viannia*.

- The main difference between the two subgenera is that promastigotes of the sub-genus *Viannia* develop in the midgut and hindgut of sandfly where as that of subgenus *Leishmania* develop in the anterior portion of the alimentary tract of sandfly
- Both of the subgenera comprise of nearly 20 species. (Table 5.1)
  - **Old world leishmaniasis:** Affects Asia, Africa and Europe and transmitted by sandfly (Genus *Phlebotomus*)
  - **New World Leishmaniasis:** Affects Central and South America and transmitted by sandfly (Genus *Lutzomyia*)
- Clinical syndromes of leishmaniasis include:
  - Visceral leishmaniasis (VL)
  - Post-kala-azar dermal leishmaniasis (PKDL)
  - Cutaneous leishmaniasis (CL)
  - Diffuse cutaneous leishmaniasis (DCL)
  - Leishmaniasis recidivans (LR)
  - Mucocutaneous leishmaniasis (MCL)

## OLD WORLD LEISHMANIASIS

### *Leishmania donovani*

#### History

*Leishmania donovani* causes VL or kala azar (a hindi term meaning “black fever”)

- It was named after two scientists who discovered the parasite in the same year 1903

1. Sir William Boog Leishman in London observed the amastigotes form of the

**Table 5.1:** Classification of *Leishmania*

Species	Geographical distribution	Clinical syndrome	Vector (sandfly)	Reservoir	Transmission
<b>Old World Leishmaniasis</b>					
<b><i>Leishmania Leishmania (L. L.) donovani</i> Complex</b>					
<i>L. L. donovani</i>	South Asia (Indian subcontinent)	VL (Kala-azar) PKDL	<i>Phlebotomus argentipes</i>	Humans	Anthroponotic
	Sudan, Ethiopia, Kenya and Uganda	VL, PKDL	<i>P. orientalis, P. martini</i>	Humans/rodents	Anthroponotic/Zoonotic
	Middle East, Africa and China	VL	<i>P. perniciosus</i>		Zoonotic
<i>L. L. infantum</i>	Mediterranean, Middle East, Central Asia and China	VL, CL	<i>P. perniciosus</i>	Dogs, foxes, jackals, etc	Zoonotic
<b><i>L. L. tropica</i> Complex</b>					
<i>L. L. tropica (Delhi boil)</i>	Western India, North Africa, Mediterranean littoral, Middle East	CL, LR	<i>P. sergenti</i>	Humans	Anthroponotic
<i>L. L. aethiopica</i>	Ethiopia, Uganda, and Kenya	CL, DCL	<i>P. longipes</i>	Hyraxes	Zoonotic
<i>L. L. major</i>	Middle East, India, China Africa, central and western Asia	CL	<i>P. papatasi</i>	Rodents	Zoonotic
<b>New World Leishmaniasis</b>					
<i>L. L. chagasi</i> (new world variant of <i>L.L. infantum</i> )	Central and South America	VL, CL	<i>Lutzomyia</i> spp.	Dogs, foxes, etc	Zoonotic
<i>L. L. Mexicana</i> Complex	Central America and northern parts of South America	CL, DCL	<i>Lutzomyia</i> spp.	Forest rodents	Zoonotic
<i>L. Viannia braziliensis</i> Complex	South and Central America	CL, MCL	<i>Lutzomyia</i> spp.	Forest rodents	Zoonotic

Abbreviations: VL, Visceral leishmaniasis; PKDL, post-kala-azar dermal leishmaniasis; CL, cutaneous leishmaniasis; LR, leishmaniasis recidivans DCL, diffuse cutaneous leishmaniasis; MCL, mucocutaneous leishmaniasis

parasite in the liver of a British soldier died at Dumdum, Kolkata. (Hence also known as Dum-Dum fever)

2. Sir Donovan who found the amastigotes in the splenic smear from a patient from Chennai
- Charles Nicolle, a 1928 Nobel laureate, at the Pasteur Institute of Tunis, characterized the new world VL and cultivated the etiologic agent.

## Morphology

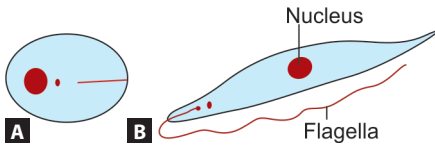
*Leishmania* occurs in two forms:

### Amastigote form

It is an obligate intracellular form and the infective stage to vector, sandfly.

- Found in reticuloendothelial cells like macrophages, neutrophils, endothelial cells of liver, spleen, bone marrow, etc. of





**Figs 5.2A and B:** *Leishmania* species (schematic diagram) (A) amastigote form; (B) promastigote form

the vertebrate hosts like humans, dogs and rodents

- Round to oval, 3-5  $\mu\text{m}$  in size
- **Nucleus:** It measures less than 1  $\mu\text{m}$ , oval to round, located in center or side of the cell
- **Kinetoplast:** Consists of copies of mitochondrial DNA. It is made up blepharoplast and parabasal body connected by a delicate fibril (cytoskeleton). It lies at right angle to the nucleus
- **Axoneme:** It extends from blepharoplast to the cell wall. It represents the intracellular portion (root) of flagellum
- There is no external flagellum and it is nonmotile
- **Vacuole:** It is a clear space, lies adjacent to axoneme (Fig. 5.2A).

### Promastigote form

This is an extracellular form, infective stage to humans.

- It is mainly found in sandfly and in culture
- It is motile and contains single anterior flagellum
- Pear shaped, 8-15  $\mu\text{m}$  length
- Nucleus is situated centrally and kinetoplast is placed near the anterior end transversely
- **Axoneme:** Represents the intracellular portion of flagellum (Fig. 5.2B).

### Life Cycle (Fig. 5.3)

**Host:** *Leishmania* completes its life cycle in two hosts:

1. **Vertebrate host** (man, dog, rodents, etc.)
2. **Insect vector (female sandfly):** *Phlebotomus argentipes*

**Infective form:** Promastigote forms present in the midgut (majority) or foregut (small proportion) of female sandfly

**Mode of transmission:** By bite of an infected sandfly mainly during the late evening or the night time. Minimum 10-1,000 promastigotes per infective bite are required to initiate the infection

### In vertebrate hosts, including humans:

- Promastigotes are regurgitated from the midgut rarely or directly discharged from foregut (proboscis) of the female sandfly into the skin of the vertebrate host
- Promastigotes are phagocytosed by the skin macrophages and transform into amastigote forms within 12-24 hours
- The amastigote forms inside the macrophages multiply further causing cell rupture and release into the circulation
- Amastigotes are carried out in the circulation to various organs like liver, spleen and bone marrow and invade the reticuloendothelial cells like macrophages, endothelial cells, etc.

### In sandfly:

- During the blood meal taken up by the sandfly, the amastigotes are ingested and transformed into promastigote forms in the insect midgut
- Promastigotes multiply by longitudinal fission and pass through various stages such as:
  - **Amastigote** → **procyclic promastigote** → **nectomonad promastigote** → **haptomonad promastigote** → **leptomonad promastigote** → **metacyclic promastigote**
  - The metacyclic promastigotes multiply in the midgut of vector by binary fission and a small proportion migrates to the foregut (proboscis). They infect a new host during another blood meal
- The duration of the life cycle in sandfly varies from 4 to 18 days depending on the species.

### Pathogenicity

Various factors contribute to the pathogenesis such as:

- The phagocytosis of the promastigotes is facilitated by binding of the promastigote surface antigens such as 63 kDa glycoprotein (gp-63)



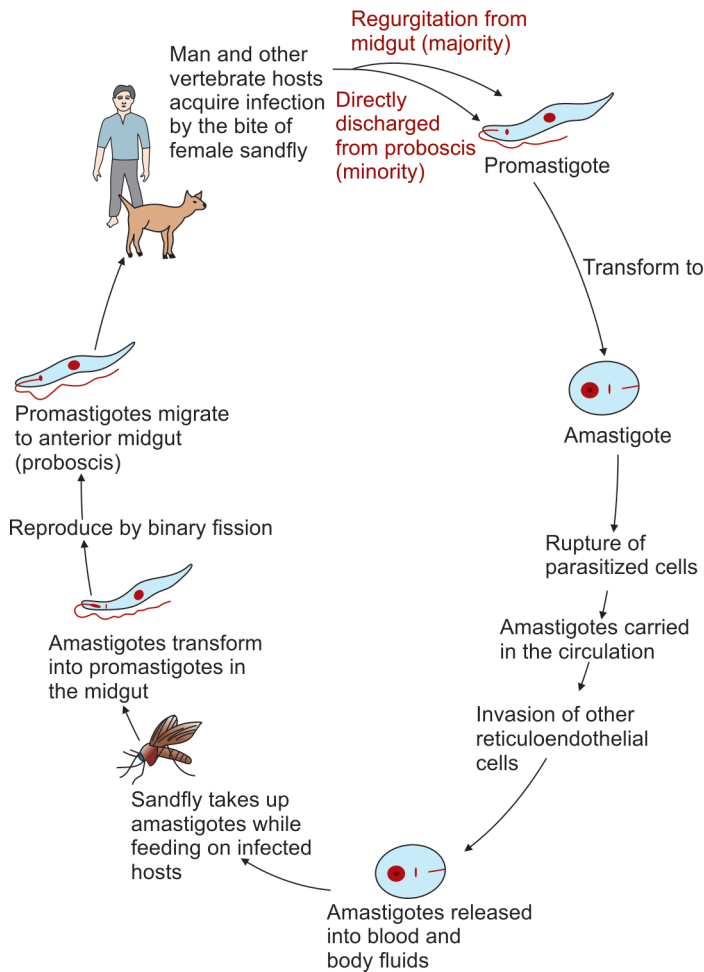


Fig. 5.3: Life cycle of *Leishmania donovani*

and lipophosphoglycan (LPG) to complement receptors (CR3 and Cq1) on macrophages.

- The gp-63 antigen also gives protection from proteolytic enzymes secreted from the phagolysosome
- LPG is the principle virulence factor, exhibits variety of functions. It prevents phagosome maturation and protects the parasite against hydrolytic enzymes secreted from the phagolysosome
- The amastigotes multiply within acidic parasitophorous vacuoles
- **Glycosyl phosphatidyl inositols (GPIs)** is a

major surface protein on amastigotes, helps in protecting from phagolysosomal attack inside the macrophage.

### Host Immune Response

Depending on the host immune response, the amastigotes are either killed or allowed to multiply inside the macrophages.

- Like leprosy, the immunology of leishmaniasis is complex and bipolar. It has two extreme poles, each which is characterized by one of the two type of T helper subset responses, i.e. T helper 1 or T helper 2 responses.

**Thelper 1 response**

Th-1 response is induced by interleukin -12 (IL-12) which leads to increase production of interferon  $\gamma$  (IFN- $\gamma$ ) and IL-2.

- At the cellular level, IFN- $\gamma$  activates macrophages which in turn kill amastigotes by induction of nitric oxide synthase and oxidative killing mechanisms
- Th1 response is observed in:
  - The majority of individuals who mount a successful immune response and control the infection
  - Cutaneous leishmaniasis
  - Patients after recovering/treated for VL
  - Leishmaniasis recidivans
- These individuals exhibit a delayed-type hypersensitivity (DTH) to leishmanial antigens (positive leishmanin skin test).

**Thelper 2 response**

Stimulation of Th-2 cells results in increase production of IL-10 and IL-4.

- It is observed in patients developing active VL and in diffuse CL
- IL-10 inhibits macrophages to kill amastigote by downregulating the production

of (TNF- $\alpha$ ) and nitric oxide. That helps in enhanced survival and growth of the parasite

- Patients do not show positive leishmanin skin test
- The parasite uses the macrophage much like a Trojan horse
- Amastigotes are released periodically by rupture of the macrophages
- They disseminate through the regional lymphatics and the vascular system to infect the reticuloendothelial cells of various organs
- This results in remarkable enlargement of the spleen, liver and bone marrow dysfunction.

**Clinical Features**

**Visceral leishmaniasis**

Visceral leishmaniasis is mainly caused by the *L. donovani* and sometimes by *L. infantum*, (designated as *L. chagasi* in the New World) together known as *L. donovani* complex. (Table 5.2).

**Table 5.2:** Various forms of visceral leishmaniasis

Characters	Indian VL (kala-azar)	Old World VL		New World VL
	<b>Indian VL (kala-azar)</b>	<b>Infantile VL</b>	<b>African VL</b>	<b>Mediterranean VL</b>
Agent	<i>Leishmania donovani</i>	<i>L. infantum</i>	<i>L. donovani</i>	<i>L. chagasi</i>
Vector	<i>Phlebotomus argentipes</i>	<i>P. perniciosus</i>	<i>P. orientalis, P. martini</i>	<i>Lutzomyia longipalpis</i>
Epidemiology	India	Middle East, Central Asia, China and Mediterranean basin	Sudan, Ethiopia, Kenya and Uganda	Central and South America
Age affected	Young adults	Infants and children < 5 years of age	Adults	Children
Reservoir	Anthroponotic (human)	Zoonotic (canine)	Anthroponotic, Rarely- Zoonotic (rodents)	Zoonotic (canine)
PKDL	Common	Less common	Common	Less common
Lymphnode involvement	Less common	More common, Aggravated by poor nutrition	Less common	Less common

Abbreviations: VL, visceral leishmaniasis; PKDL, post-kala-azar dermal leishmaniasis

- Incubation period ranges from 2–6 months.
- The hallmark of VL is a triad of fever, hepatosplenomegaly and pancytopenia
- **Fever:** The most common symptom of VL is an abrupt onset of moderate to high grade fever associated with rigor and chills. Typically it is described as double rise of fever in 24 hours
- **Splenomegaly:** It is the most consistent sign. The spleen may become hugely enlarged and palpable below the umbilicus. (Fig. 5.4A)
- Hepatomegaly (usually moderate in degree) soon follows splenomegaly
- **Lymphadenopathy:** Common in most of the African endemic regions (rare in Indian subcontinent)
- **Hyperpigmentation:** Mostly seen in brown-skinned individuals from Indian subcontinent
- **Pedal edema and ascites:** Occur due to hypoalbuminemia, may be seen in advanced illness
- Mucosal lesions in mouth and nasopharynx—Seen in Sudan, rare in India
- **Hematological abnormalities** (bone marrow dysfunction):
  - Anemia (normocytic and normochromic): Appears early and may become

severe enough to cause congestive heart failure

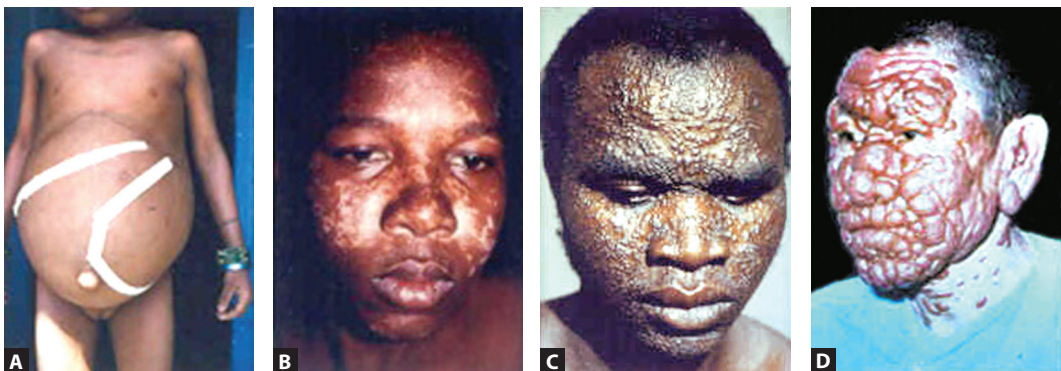- Leucopenia
- Thrombocytopenia: Can lead to epistaxis, retinal hemorrhages, and gastrointestinal bleeding
- Hypergammaglobulinemia (due to polyclonal B cell activation)

- **Leishmanoma:** Nodular skin lesions seen in African cases only
- Weight loss (cachexia)
- **Secondary infections:** Such as measles, pneumonia, tuberculosis, bacillary or amoebic dysentery and gastroenteritis are common.

#### Post-kala azar dermal leishmaniasis

It is a nonulcerative lesion of skin occurs in 2–50% of patients of VL following the completion of treatment.

- Mainly seen in India and East African countries (Table 5.3)
- It develops as hypopigmented macule (most common feature) near mouth which later on spreads to face and then to arms and trunk (extensor surfaces) and finally becomes nodules resembling leprosy (Figs 5.4B to D)
- Ocular lesions like conjunctivitis and



**Figs 5.4A to D:** Real images showing clinical features (A) splenomegaly seen in visceral leishmaniasis; (B) hypopigmented skin changes in early PKDL; (C and D) extensive facial nodular lesions in late PKDL

Source: World Health Organization "Manual on visceral leishmaniasis control" Slide 1/Desjeux; Slide 4 and 5/ El Hassan; Slide 6/ Bryceson (with permission)

**Table 5.3:** Post-kala azar dermal leishmaniasis from Indian Subcontinent and East Africa

Feature	Indian subcontinent	East Africa
Most affected country	Bangladesh followed by India	Sudan
Incidence among patients with VL	2–20%	~50% (rare in other part of Africa)
Interval between VL and PKDL	2–10 years	Can occur during VL to 6 months
Age affected	Any age	Mainly children
History of prior kala-azar	Not necessarily	Yes
PKDL persists for	Long period (20 years)	Few months
Treatment with antimonial	2–4 months	2 months
Course	Resolve slowly (noncompliance)	Spontaneous cure usually occurs

Abbreviations: VL, visceral leishmaniasis; PKDL, post-kala-azar dermal leishmaniasis

- uveitis are associated in some patients.
- Sometimes, PKDL occurs in subclinical patients without a history of VL.
  - **The diagnosis is based on:**
    - Amastigote can be detected in the skin in more than 80% of cases in the Sudan. It is more easily detected from nodular lesions than other lesions
    - Serological tests: Direct agglutination test (DAT) and antibodies to rK39 antigen are positive in most of the cases.

Treatment	PKDL
<ul style="list-style-type: none"><li>• Extended course of antimonial is given for a period of 2–4 months</li><li>• They respond poor treatment and often serve as reservoir of infection during inter-endemic cycles.</li></ul>	

***Leishmaniasis with HIV co-infection***

Co-infection of HIV with VL has been reported from more than 35 countries.

- Mainly it is reported from Southern Europe (France, Italy, Spain and Portugal) where 50–75% of adult cases of VL are HIV positive and 7–17% of HIV infected people with fever have amastigotes
- Also reported from other places like sub-Saharan African and Indian subcontinent
- In India, it is reported from Bihar, sub-Himalayan region and other North Indian

states. Various studies reported the co-infection prevalence around 2–6%

- Both HIV and *Leishmania* affect each other’s pathogenesis

**Effect on HIV:**

- *Leishmania* appears to cause activation of latent HIV
- It expresses high level of chemokine receptor (CCR5) receptors on macrophages

**Effect on *Leishmania*:**

- HIV causes activation of T helper 2 cells response leading to disease progression
- *Leishmania* uptake is enhanced by the HIV infected macrophages
- Associated with more relapses
- HIV co-infected patients don’t show the classic signs of VL like hepatosplenomegaly
- But they present with atypical features due to loss of immunity with presence of more gastrointestinal tract (GIT) and pulmonary symptoms
- CD4 T cell count often fall below 50/μL (almost always < 200/μL)
- There is consideration to include leishmaniasis in Center for Disease Control and Prevention (CDC) clinical category C for the definition of AIDS as an opportunistic pathogen
- **Diagnosis:** Serodiagnostic tests are usually negative. Amastigote are demonstrated

from unusual sites such as bronchoalveolar lavage fluid and buffy coat region of blood

Treatment	HIV/VL coinfection
Liposomal amphotericin B is the drug of choice for HIV/VL co-infection. But response is poor with frequent relapses.	

### Epidemiology

Leishmaniasis occurs in 98 countries; most of them developing countries of tropical and temperate regions.

- More than 350 million people are at risk, with an overall prevalence of 12 million
- Two million cases occur annually, of which 1–1.5 million are CL (and its variations) and 500,000 are VL
- Four largest foci of VL (90%): India and neighboring countries like Nepal, Bangladesh, Sudan and Brazil
- In Indian subcontinents, VL is anthroponotic, while zoonotic VL is reported from Middle East, Pakistan and other countries from Western Asia to China.
- **India:** India is the worst affected country. Bihar is affected the most followed by Jharkhand, West Bengal and Uttar Pradesh. 48 districts with more than 165 millions of people are at risk. In 2012, more than 20,000 cases are reported from India with 23 deaths.

### Laboratory Diagnosis

#### Leishmania donovani

- Microscopy (detects LD bodies)
  - Splenic aspiration: Most sensitive
  - Bone marrow aspiration: Most commonly preferred
  - Lymph node aspirates (in African patients)
  - Liver biopsy
  - Peripheral blood smear (in HIV infected people)
  - Biopsy of various organs (in HIV infected people)
- Culture (detects promastigotes)
  - NNN medium
  - Schneider's liquid medium

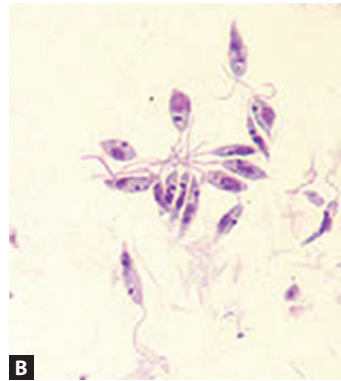
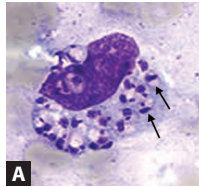
- Antibody detection in serum
  - CFT using WKK antigen of tubercle bacilli
  - ELISA
  - Direct agglutination test
  - ICT using rk39 antigen
- Nonspecific tests to detect hypergammaglobulinemia
  - Napier's aldehyde test
  - Chopra antimony test
- Molecular method—PCR
- Leishmanin test (montenegro test)
- Animal inoculation—golden hamster
- Pancytopenia.

### Laboratory Diagnosis

#### Microscopy

Demonstration of amastigotes inside the macrophages (also known as **Leishman Donovan bodies** or **LD bodies**) is the gold standard method for the diagnosis of VL (Fig. 5.5A). Smears should be stained with Leishman, Giemsa or Wright stains. The various samples include:

- **Splenic aspiration:** The sensitivity of splenic smear examination is excellent (> 95%) but splenic puncture is associated with risk of hemorrhage. Grading of LD bodies from splenic smear is useful in determining the parasitic load and monitoring the response to treatment
- **Bone marrow aspiration:** Iliac crest aspirate is the most commonly preferred sample though the sensitivity is around 60–85%. If bone marrow findings are negative but the clinical suspicion is strong, then the splenic aspiration is indicated
- **Lymph node aspiration:** It is useful only in African cases of kala-azar and sensitivity is low (50%)
- **Liver biopsy:** Less sensitive and carries the risk of hemorrhage
- **Peripheral blood smear:** Amastigotes within mononuclear cells and neutrophils can be seen in a stained blood smear.



**Figs 5.5A and B:** (A) Amastigote form [arrows shows inside a macrophage (Giemsa stain)]; (B) smear shows promastigote form (Giemsa stain) from culture

Source: DPDx Image Library, Centre for Disease Control and prevention (CDC), Atlanta (with permission)



**Fig. 5.6:** NNN medium

Source: World Health Organization, "Manual on visceral leishmaniasis control" (Slide22/Alvar) (with permission)

Sensitivity increases by making thick smears, using centrifuged blood and making smears from buffy coat particularly in HIV patients

- **Biopsy specimens of various organs:** Like oropharynx, stomach, or intestine. This is particularly important in patients with AIDS.

### Culture

- **Sample:** Aspirations from spleen, bone marrow or other tissue and also buffy coat.
- **Medium:**
  - **NNN medium** (described by Novy, McNeal-1903 and Nicolle-1908): Novy-MacNeal-Nicolle (NNN) medium is a biphasic medium, composed of two parts salt agar and one part defibrinated rabbit blood (Fig. 5.6)
  - **Schneider's Liquid medium:** It con-

tains Schneider's *Drosophila* insect medium supplemented with 30% fetal calf serum. It is found to be more sensitive than NNN media

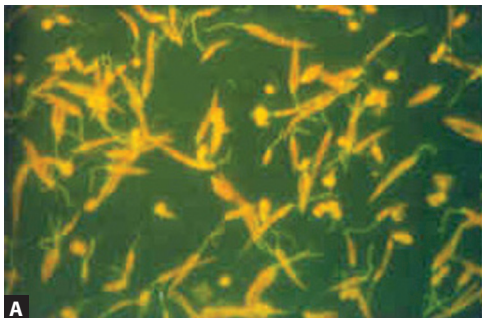
- Semisynthetic fetal calf serum free medium
- Microculture method using microcapillary tubes
- Inoculated specimens are incubated at ambient temperature (22–26°C) upto 4 weeks
- Amastigotes transform into promastigotes in the culture fluid which are detected by staining with Giemsa stain (Fig. 5.5B)
- Culture fluid is examined for twice a week for first 2 weeks and once a week thereafter for up to 4 weeks; before they are reported as negative
- Culture is found to be positive in 75% of cases.

### Antibody detection in serum

In general, the serological tests are sensitive, but less specific. False-positive results may occur due to cross-reacting antibodies in patients with leprosy, Chagas' disease, CL, and other infections. Antibodies cannot differentiate current and past infection. More so, antibodies may be absent or present in low titer in patients with AIDS



- **Complement fixation test (CFT):** Cross reacting antibodies are detected in patient's blood by using nonspecific antigens like human tubercle bacilli antigens called as WKK antigen (as described by Witebsky, Klingenstein, Kuhn). It is not in use nowadays
- **Enzyme-linked immunosorbent assay (ELISA) and indirect fluorescent antibody (IFA) test,** (Fig. 5.7A) are the newer tests found to be more sensitive and have replaced CFT
- **Direct agglutination test:** Patient serum is incubated with extract of axenic amastigote antigens in a microtitre plate. Mat formation indicates a positive result where as a negative result is reported when button is formed. It is found to be 100% sensitive and specific. It is simple, rapid and doesn't need any instrument. However, antibodies persist up to 5 years after the treatment. (Fig. 5.7B)
- **Immunochromatographic test (ICT):** Immunochromatographic test (ICT) detects leishmanial antibody by using *L. infantum* recombinant kinesin antigen (rk39). It claims 98% sensitivity and 90% specificity, however, the sensitivity is low in East Africa and in HIV patients. Like DAT, it is also simple, rapid and doesn't need any instrument (useful in field studies).



#### Nonspecific tests to detect hypergammaglobulinemia

- **Napier's Aldehyde test:** Patient's serum is added with a drop of 40% formalin in a test tube. Positive test is indicated by jellification of the serum forming milk white opacity like that of white of a boiled egg within 20 minutes  
Disadvantages include:
  - › It is negative in the first three months
  - › False positive results are seen with *Schistosoma japonicum*, *Trypanosoma cruzi*, multiple myeloma and cirrhosis
  - › It is negative in CL cases
- **Chopra's antimony test:** Positive test is indicated by formation of profuse flocculation when patient's serum is mixed with 4% urea stibamine solution.


#### Molecular methods

Qualitative detection by polymerase chain reaction (PCR) and quantitative detection by real-time PCR are available targeting *Leishmania* specific kinetoplast (mitochondrial) DNA. It is mostly confined to the reference laboratories with sensitivity varying from 70% to 93%.

#### Leishmanin test (Montenegro test)

Introduced by Sir Montenegro in South America.

- It is a delayed hypersensitivity skin test to



**Figs 5.7A and B:** (A) Indirect fluorescent antibody test; (B) direct agglutination test

Source: "Manual on visceral leishmaniasis control", World Health Organization A- Slide31/Evans, B- (Slide32/Alvar) (with permission)

a suspension of killed *L. donovani* promastigote injected intradermally

- A positive test is indicated by induration of more than or equal to 5 mm in 72 hours
- Positive test indicates prior exposure to *Leishmania* antigens
- It is positive in people with good cell-mediated immunity (CMI):
  - Asymptomatic individuals: It is used for epidemiological survey to estimate the burden of the disease
  - Cutaneous leishmaniasis
  - 6-8 weeks after recovery from VL
  - Leishmaniasis recidivans
- However, this test is negative in [when CMI is low]:
  - Active visceral leishmaniasis
  - Diffuse cutaneous leishmaniasis.

**Animal inoculation**

Intranasal inoculation of specimens to golden hamsters yields amastigotes after several months. It is not in use nowadays.

**Nonspecific tests**

- Complete blood count—to detect pancytopenia
- Elevated liver enzymes
- Reversal of albumin globulin ratio (reflects hypergammaglobulinemia)

**Leishmania tropica Complex**

It includes three species—*L. tropica*, *L.*

*aethiopica* and *L. major*. They cause old world Cutaneous Leishmaniasis (Table 5.4).

- *L. tropica* is reported from Western India (mainly Rajasthan), Middle East and Mediterranean coast. It mainly affects urban area hence known as agent of urban anthroponotic CL
- *L. aethiopica* infects people from Ethiopia, Uganda and Kenya
- *L. major* is reported from Middle East, India, China, Africa, and central and western Asia. It mainly affects rural area hence known as agent of rural zoonotic CL.

**Life Cycle**

The life cycle of the *L. tropica* complex is same as *L. donovani* except:

- The species of vector sandfly are different-
  - *L. tropica*—vector is *P. sergenti*
  - *L. aethiopica*—vector is *P. longipes*
  - *L. major*—vector is *P. papatasi*
- Reservoir of infection:
  - *L. tropica*—is man (anthroponotic)
  - *L. aethiopica*—is *Hyraxes* (Zoonotic)
  - *L. major*—is rodents (zoonotic)
- In humans, the amastigote forms reside in reticuloendothelial cells of skin (they do not migrate to viscera).

**Clinical Features**

**Cutaneous leishmaniasis**

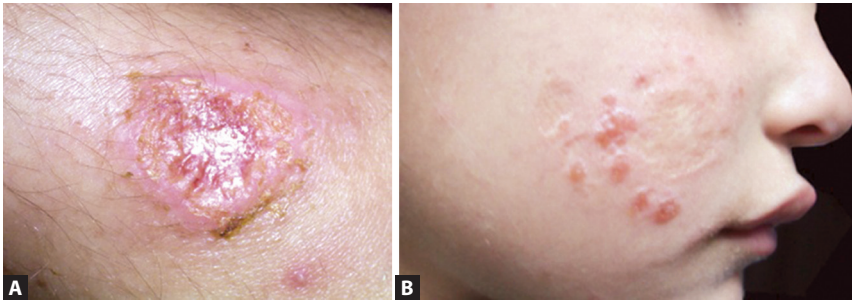
It is caused by *L. tropica* complex. This condition is also known as “**Oriental sore**”,

**Table 5.4:** Various agents of cutaneous leishmaniasis

Species	Geographical distribution	Clinical syndrome	Vector (Sandfly)	Reservoir	Transmission
<i>Leishmania</i> <i>Leishmania</i> <i>tropica</i> (Oriental sore)	Western India, North Africa, and Middle East	CL, LR	<i>Phelobotomus sergenti</i>	Humans	Anthroponotic
<i>L. L. aethiopica</i>	Ethiopia, Uganda, and Kenya	CL, DCL	<i>P. longipes</i>	Hyraxes	Zoonotic
<i>L. L. major</i>	Middle East, India, China Africa, Central and Western Asia	CL	<i>P. papatasi</i>	Rodents	Zoonotic

Abbreviations: CL, cutaneous leishmaniasis; LR, leishmania recidivans; DCL, diffuse cutaneous leishmaniasis





**Figs 5.8A and B:** Real images showing clinical features of (A) cutaneous leishmaniasis; (B) leishmaniasis recidivans

Source: A- World Health Organization, “Manual on visceral leishmaniasis control” (with permission); B- Global Skin Atlas/Image Number 2268/Nameer Al-Sudany (with permission)

Delhi Boil, Aleppo Boil and Baghdad Button, etc (Fig. 5.8A).

- Oriental sore usually occurs on face and hands
- It begins as papule, becomes nodular and finally it ulcerates
- The margins of the ulcers are raised, painless and indurated
- Lesions may be single or multiple and vary in size from 0.5 cm to more than 3 cm
- Mostly, it heals spontaneously leaving behind a scar
- There may be satellite lesions, especially in *L. major* and *L. tropica* infections.

### ***Leishmaniasis recidivans***

It is a granulomatous response occurs years after healing of primary sore due to *L. tropica*.

- Characterized by new lesions formed on the face, usually scaly, erythematous papules and nodules develop in the center or periphery of a previously healed sore
- CMI is intact and skin test is positive
- Very few parasites can be demonstrated in the smears from the lesions (Fig. 5.8B).

### ***Diffuse cutaneous leishmaniasis***

It is a rare form of leishmaniasis, caused by *L. amazonensis* and *L. mexicana* in South and Central America (New World) and by *L. aethiopica* in Ethiopia and Kenya (old World).

- Characterized by the lack of a CMI response to the parasite

- Low CMI leads to widespread cutaneous disease—symmetric or asymmetric distribution of various lesions like papules, nodules, plaques, and areas of diffuse infiltration, non ulcerative lesions with heavy load of parasites
- The delayed type hypersensitivity (DTH) response is negative, so skin test, i.e. Montenegro test is negative.

### **Laboratory Diagnosis**

*Leishmania tropica* complex

- Microscopy—detects amastigotes
- Culture—NNN medium
- Montenegro test—positive except in diffuse CL

### **Laboratory Diagnosis**

#### **Microscopy**

Amastigotes can be demonstrated from indurated edge of the lesions or biopsy from the margin of the ulcer.

#### **Culture**

Aspiration from the ulcers can be cultured in NNN medium for the isolation of promastigote forms.

#### **Montenegro test**

Positive leishmanin skin test indicates delayed hypersensitivity reaction to the parasite. However, it is negative in diffuse CL.

**Treatment****Old World Leishmaniasis****Supportive therapy**

Correction of pancytopenia should be done by blood transfusion. Similarly, other associated conditions should be managed promptly.

**Specific antileishmanial drugs****Pentavalent antimonial**

- It is the drug of choice in most endemic regions of the world, except in Bihar (due to emergence of drug resistance)
- Two pentavalent antimonial (SbV) preparations are available:
  - Sodium stibogluconate (100 mg of SbV/mL)
  - Meglumine antimoniate (85 mg of SbV/mL)
- **WHO recommendations 1995**
  - For VL, the daily dose is 20 mg/kg by rapid intra venous (IV) infusion or intramuscular (IM) injection, and therapy continues for 28–30 days till smear microscopy is negative
  - For CL, 1–3 ml of antimonial preparations should be infiltrated at the base of the lesions for two to three times at interval of 1–2 days
- **Resistance to antimonials**
  - Increased resistance has been reported to *L. tropica*, *L. major* and *L. mexicana* in comparison to *L. donovani*
  - ***L. donovani***: Resistance is only reported from North Bihar. Mishandling of antileishmanial drugs is the single most important contributor to the development of drug resistance
  - **Mechanisms**: Occurs due to failure of reduction of SbV (prodrug) to its active form SbIII inside the resistant *L. donovani* amastigotes.

**Amphotericin B**

- It is currently used as a first-line drug in Bihar for the treatment of VL. In other parts of the world, it is used when initial antimonial treatment fails

- It is also the drug of choice for the New world mucocutaneous leishmaniasis (MCL)
- Conventional amphotericin B deoxycholate is administered in doses of 0.75–1.0 mg/kg on alternate days for a total of 15 infusions
- Alternatively the lipid formulations of AmB are used which have lower side effects

**Paromomycin**

It is an aminoglycoside antibiotic with antileishmanial activity. It is given IM at a dose of 11 mg of base/kg daily for 21 days

**Miltefosine**

It is the first oral compound approved for the treatment of leishmaniasis. It is given as daily dose of 50 mg once or twice for 28 days.

**Prevention****Vaccine Trials**

Currently no vaccine is available for the prevention of leishmaniasis. However, several trials are going on.

- Both killed and live-attenuated vaccine trials are on going targeting antigens derived from killed promastigotes
- Trials for recombinant and synthetic vaccines are also on going using gp-63 antigen.

**Control Measures**

Vector control measures to eradicate sandfly:

- Personal prophylaxis by using insect repellents or bed nets
- Control of canine or rodent reservoir
- *Phlebotomus* doesn't fly high above the ground level and it is nocturnal in habitat. So, sleeping at top floors also can prevent transmission
- Early treatment of all cases (mainly anthroponotic VL and PKDL cases).

**NEW WORLD LEISHMANIASIS**

It is mainly caused by:

- *Leishmania Viannia (L.V.) braziliensis* complex

- *Leishmania Leishmania (L.L.) mexicana* complex
- *L.L. chagasi* (new world variant of *L.L. infantum*)

The main difference between the two subgenera is promastigotes of the subgenus *Viannia* develop in the midgut and hindgut of sandfly where as that of subgenus *Leishmania* develop in the anterior portion of the alimentary tract of sandfly.

The morphology and life cycle of new world *Leishmania* species are identical to that of *L. donovani* except:

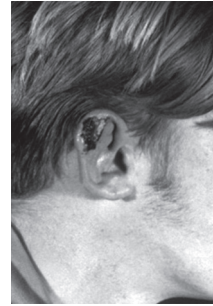- Geographical distribution-restricted to central and south America
- **Vector:** *Lutzomyia* species
- **Reservoir of infection:** Dogs, foxes (zoonotic)
- The amastigote forms in humans reside in reticuloendothelial cells of skin and mucus membrane (don't invade viscera).

### Clinical Features of New World Leishmaniasis

#### *Leishmania Mexicana Complex*

*L. mexicana* complex infected people develop CL similar to those seen with old world cutaneous disease (Table 5.5).

- *L. mexicana* causes a specific form of CL called as **chiclero ulcer** (or bay sore) characterized by persistent ulcerations in pinna seen in Central America among workers living in forests harvesting chicle



**Fig. 5.9:** Real image showing chiclero ulcer in pinna  
Source: Public Health Image Library, ID#15062/David O. Madorsky: Capt. Loren Quigg, Centre for Disease Control and Prevention (CDC), Atlanta (with permission)

plants to collect chewing gum latex. 30% of people are infected during the first year of exposure (Fig. 5.9)

- *L. mexicana* and *L. amazonensis* produce DCL similar to that is described earlier for *L. aethiopica*.

#### *Leishmania Viannia braziliensis Complex*

They cause MCL and also CL similar to oriental sore but they are more severe (Table 5.6).

#### *Espundia (mucocutaneous leishmaniasis)*

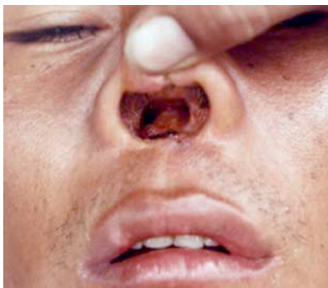*L. braziliensis* infects mucous membrane of the nose, oral cavity, pharynx or larynx months to years after the CL.

- It is seen in 1–3% of patients infected with *L. braziliensis*, more in males of age 10–30 years

**Table 5.5:** *Leishmania Leishmania mexicana* complex

Species	Geographical distribution	Clinical syndrome	Vector	Reservoir	Transmission
<i>Leishmania Leishmania mexicana</i>	Central America and Northern parts of South America	CL (chiclero ulcer), DCL, MCL	<i>Lutzomyia</i> spp.	Forest rodents Marsupial and Humans	Zoonotic
<i>L. L. amazonensis</i>		CL, DCL and MCL			
<i>L. L. venezuelensis</i>		CL			
<i>L. L. pifanoi</i>		CL, DCL			
<i>L. L. garnhami</i>		CL			

Abbreviations: CL, cutaneous leishmaniasis; DCL, diffuse cutaneous leishmaniasis; MCL, mucocutaneous leishmaniasis



**Fig. 5.10:** Real image showing mucocutaneous leishmaniasis or espundia  
Source: Calvopina et al. BMC Infectious Diseases 2006 (with permission)

- The initial symptoms are often nasal stuffiness, erythema and mucopurulent discharge.
- It may eventually involve the upper lip, buccal, pharyngeal, or laryngeal mucosa (Fig. 5.10)
- Ulcerative lesions are formed with erosion of the soft tissue and the cartilages leading to loss of lips, soft part of nose and soft palate
- Gradually, the nasal septum may be destroyed, resulting in nasal collapse with hypertrophy of upper lip and nose leading to development of “**tapir nose**”

**Forest yaws and uta:** The cutaneous lesions of *L. V. guyanensis* and *L. V. peruviana* are known as forest yaws (pain bois) and uta respectively.

**Leishmania Leishmania chagasi**

*L.L. chagasi* is the new world variant of *L. L. infantum*.

- Causes mediterranean VL and CL
- Occurs in Central and South American region
- It is zoonotic (canine reservoir)
- Vector: *Lutzomyia* species
- Age: Children are affected commonly

Laboratory Diagnosis

New World leishmaniasis

- Microscopy—detects amastigotes
- Culture—NNN medium
- Montenegro test—Positive (except in DCL and active VL)
- Antibody detection—Poorly sensitive in DCL and MCL

**Laboratory Diagnosis of New World Leishmaniasis**

**Microscopy**

Amastigote forms within the macrophages are found abundant in the lesions of DCL followed by CL and VL when stained with Giemsa or Leishman stain. However, in lesions of MCL fewer parasites are found.

**Culture**

Skin and mucosal biopsy specimens are first minced to release the organisms and then

**Table 5.6:** *Leishmania Viannia braziliensis* complex

Species	Geographical distribution	Clinical syndrome	Vector	Reservoir	Transmission
<i>Leishmaina Viannia braziliensis</i>	Brazil	CL and MCL (espundia)	<i>Lutzomyia</i> spp.	Dogs, foxes, forest rodents and humans	Zoonotic
<i>L. V. panamensis</i>	Panama and Colombia	CL and MCL			
<i>L. V. guyanensis</i>	Guyana	CL (forest yaws) and MCL			
<i>L. V. peruviana</i>	Peru	CL (Uta) and MCL			

Abbreviations: CL, cutaneous leishmaniasis; MCL, mucocutaneous leishmaniasis

inoculated in NNN media and Schneider's *Drosophila* medium.

### Montenegro Test

Positive Leishmanin skin test indicates delayed hypersensitivity reaction to the parasites. However, it is negative in diffuse CL and active VL (*L. chagasi*).

### Antibody Detection

Antibodies are detected in patients with active VL by various formats described before. However, they show variable sensitivity in CL and poor response in MCL and DCL.

Treatment	New world leishmaniasis
<ul style="list-style-type: none"> <li>• In contrast to Old World CL, systemic therapy is recommended for New World CL as the lesions are more chronic, multiple and shows tendency for mucosal involvement</li> <li>• Pentavalent antimonial is the drug of choice, administered as a dose of 20 mg/kg for 30 days</li> <li>• In case of relapse, liposomal amphotericin B (2–3 mg/kg for 20 days) or miltefosine (2.5 mg/kg for 28 days) are given.</li> </ul>	

## TRYPANOSOMA

Trypanosomes are hemoflagellates that reside in peripheral blood and tissues of their host. They can be classified as:

### Human Trypanosomes

They show strict geographical distribution:

- ***Trypanosoma cruzi***: It is the causative agent of South American trypanosomiasis (also called as **Chagas' disease**) in man and transmitted by insect vector reduviid bug
- ***Trypanosoma brucei***: It causes African trypanosomiasis, transmitted by tsetse fly. It has three important subspecies out of which only two of them infect humans
  - ***Trypanosoma brucei rhodesiense***: It is the causative agent of East African sleeping sickness

➤ ***Trypanosoma brucei gambiense***: It is the causative agent of West African sleeping sickness

- ***Trypanosoma rangeli***: It is a nonpathogenic species that rarely infects humans in South America.

### Animal Trypanosomes

- ***Trypanosoma brucei brucei***: It causes "**nagana**", a disease affecting cattle in Africa
- *T. congolense* and *T. vivax* cause disease similar to that of *T. brucei brucei*
- ***Trypanosoma evansi***: It causes "**Surra**" in horses and other animals. It is transmitted by flies (tabanidae and stomoxys). Many animal cases are reported in India
- ***Trypanosoma lewisi***: It causes a harmless infection affecting rodents
- ***Trypanosoma equiperdum***: It causes "**Stallion's disease**" in horses. It is transmitted by sexual route (not by insect vector).

## TRYPANOSOMA CRUZI

It is the causative agent of South American trypanosomiasis or Chagas' disease.

- It was first discovered by Brazilian scientist **Carlos Chagas**, isolated from reduviid bug (triatomine bugs) and blood of infected monkeys. Later on he found it causing human infection also
- Hence the condition is named as Chagas' disease. He named the parasite as *T. cruzi* after his guide Oswaldo Cruz.

### Habitat

- In humans, *T. cruzi* exists in two forms: (1) amastigote and (2) trypomastigote form.
- Amastigotes are intracellular parasite found in reticuloendothelial cells of spleen, liver, lymph node, bone marrow, and myocardium. They are also found in cells of epidermis and striated muscles
  - Trypomastigotes are extracellular and found in peripheral blood.



## Epidemiology

Chagas' disease is mainly restricted to South and Central American countries like Brazil, Argentina, Venezuela, etc.

- Currently, it is estimated that 8 million people are chronically infected with *T. cruzi* and 14,000 deaths occur due to the illness every year
- It is a zoonotic disease, having many animal reservoirs like dogs, cats, opossums and rodents.

## Morphology

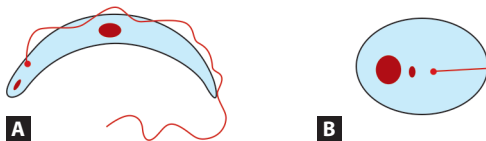
- In vertebrate host, it exists mainly in two forms—(1) trypomastigote form and (2) amastigote form
- In insect vector (reduviid bug), it exists as all four forms, i.e. (1) trypomastigote, (2) amastigote, (3) promastigote and (4) epimastigote form.

### Trypomastigote Form

- It is spindle shaped; measures around 20  $\mu\text{m}$  and appears as C or U shaped
- It is seen in the peripheral blood of the infected patients in two forms—(1) long slender form and (2) short stubby form
- It consists of a central nucleus and large kinetoplast situated posteriorly from which flagellum originates and traverses the whole body as undulating membrane and comes out from the anterior end as free flagellum
- It doesn't multiply (Fig. 5.11 A).

### Amastigote Form

- It is found inside cells of striated muscle (skeletal and cardiac), nervous tissue and reticuloendothelial cells



**FIGS 5.11A and B:** *Trypanosoma cruzi* (schematic diagram) (A) trypomastigote form (B) amastigote form

- When fully developed, a large number of amastigote may be found in a cyst like cavity
- This is indistinguishable from those found in *Leishmania* infection
- It is round to oval, 26  $\mu\text{m}$  in size having a large nucleus, rod shaped kinetoplast and axoneme but no flagella
- It is the multiplying form of the parasite (Fig. 5.11 B).

## Life Cycle (Fig. 5.12)

**Host:** *T. cruzi* passes its life cycle in two hosts—(1) humans and (2) vector reduviid bugs or kissing bugs or triatomine bugs (*Triatoma infestans*, *Rhodnius prolixus* and *Panstrongylus megistus*) (Fig. 5.13).

**Infective form:** Metacyclic trypomastigote form is the infective forms, found in feces of reduviid bugs.

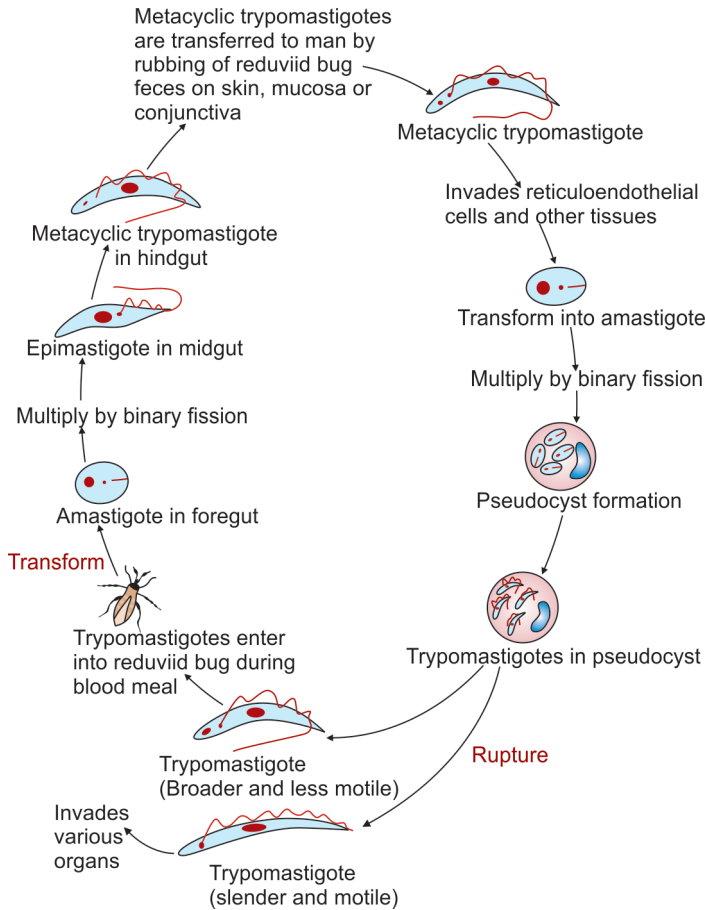
**Mode of transmission:** Reduviid bugs are nocturnal in habitat and humans get infection when abraded skin, mucous membranes, or conjunctivae become contaminated with reduviid bug's feces containing infective form of the parasite.

*T. cruzi* can also be transmitted by the blood transfusion, organ transplantation from mother to fetus or very rarely by ingestion of contaminated food or drink, and most importantly by laboratory accidents.

### Development in Man

The parasite invades the reticuloendothelial cells and other tissues like muscle (cardiac, skeletal and GIT muscles) and nervous tissue and transforms into amastigote form.

- In these tissues, the amastigotes multiply by binary fission forming a cyst like mass of growth known as pseudocyst
- Many amastigotes within the pseudocyst are transformed into motile C shaped nonmultiplying trypomastigote forms.
- On rupture of the pseudocyst, the trypomastigotes are liberated to blood. They are of two types:



**Fig. 5.12:** Life cycle of *Trypanosoma cruzi*



**Fig. 5.13:** Reduviid bug (real image)

Source: DPDx Image Library, Centre for Disease Control and prevention (CDC), Atlanta (with permission)

- **Slender highly motile forms:** Have an elongated nucleus, sub terminal kinetoplast and a short free flagellum. They are the invasive forms, eventually migrate to many organs, penetrate the cells and continue the life cycle

- **Broader less motile forms:** Have an oval nucleus, terminal kinetoplast and a long free flagellum. They persist in the blood to be taken up by the insect vector during a blood meal.

### Development in Reduviid Bugs

Broader less motile trypomastigote forms are transmitted to reduviid bugs during the blood meal.

- They transform into amastigote forms in the foregut
- In the midgut, the amastigote forms multiply by binary fission and divide to form epimastigote forms
- They finally transform into metacyclic

trypomastigote forms in the hindgut and are excreted in the bug's feces

- The insect cycle takes about 10–15 days (extrinsic incubation period). There is no transovarian transmission seen in the bugs and once infected, they retain the infection throughout the life by the molting cycles.

### Pathogenesis and Clinical Feature

Average incubation period is around 1 week. *T. cruzi* causes American trypanosomiasis (also called as Chagas' disease) which can be acute or chronic type.

### Acute Chagas' Disease

It is characterized by:

- **Chagoma:** An erythematous subcutaneous nodule is formed at the site of deposition of bug's feces. It is painful, commonly occurs on face and may take 2–3 months to resolve
- **Romana's sign:** When the parasites enter through conjunctiva, there occurs an unilateral painless edema of the eye lid and conjunctivitis (Fig. 5.14)
- Generalized lymphadenopathy and hepatosplenomegaly may also appear
- Severe myocarditis and neurologic signs like meningoencephalitis occur occasionally, especially in children
- Usually within 4–8 weeks, patient either recovers spontaneously or develops chronic *T. cruzi* infection.



**Fig. 5.14:** Real image showing romana's sign in the eyelid

Source: Public Health-image library, ID # 2617/ Dr. Mac Melvin, Centre for Disease Control and Prevention (CDC), Atlanta (with permission)

### Chronic Chagas' Disease

Chronic Chagas' disease manifests years or even decades after the initial infection. It occurs due to multiplication of the parasites in the muscles (skeletal, cardiac and GIT) and nervous tissue.

**Autoimmune hypothesis:** Though not fully proved, an autoimmune mechanism has been suggested. *T. cruzi* antigens cross react with mammalian antigens (molecular mimicry) and many autoreactive antibodies have been detected in infected patients

- **Asymptomatic (indeterminate form):** Most frequent form, typically observed in the beginning of the chronic phase. Many individuals live in this stage throughout the life
- **Cardiac form:** Occurs in 30% of the patients. Patient develops dilated cardiomyopathy, rhythm disturbances like right bundle-branch block, and thromboembolism
- **Gastrointestinal form:** Involvement of muscles of GIT leads to megaesophagus (manifested as dysphagia, chest pain, and regurgitation) and megacolon (manifested as abdominal pain and chronic constipation)
- **Pulmonary form:** Repeated episodes of aspiration pneumonitis are common (especially during sleep) in patients with severe esophageal dysfunction
- Mixed forms are observed in 10% of the patients.

### Congenital Trypanosomiasis

Rarely, *T. cruzi* can be transmitted transplacentally both in acute and chronic stage of the disease. It is manifested as low birth weight, still birth, rarely myocarditis and neurological alterations.

### In HIV Infected People

HIV infected people are at a greater risk of reactivation of underlying *T. cruzi* infection and are more prone to develop meningoencephalitis.



## Immune Response

Both cell-mediated and humoral immunity are involved against the parasite. IgM antibodies appear early during acute infection. Then the class switch over occurs and IgG and IgA antibodies predominate in the chronic stage of the disease. Antigenic variation which is the characteristic feature of African trypanosomiasis, is rarely observed in *T. cruzi*. CMI is mainly involved in tissue destruction in the chronic stage such as cardiomyopathy and megacolon.

### Laboratory Diagnosis Trypanosoma cruzi

- Peripheral blood microscopy by wet mount, thick or thin smear—detects trypomastigotes
- Culture—NNN medium or Yager's liver infusion tryptose medium
- Antibody detection in serum—ELISA, IFA, CFT, RIPA
- Antigen detection from serum, urine—by CLIA
- Molecular methods—PCR
- Animal inoculation—Mice
- Xenodiagnosis—nymph of reduviid bugs

## Laboratory Diagnosis

### Peripheral Blood Microscopy

In acute Chagas' disease, the trypomastigotes (Fig. 5.15A) are frequently found in peripheral blood which can be detected by:

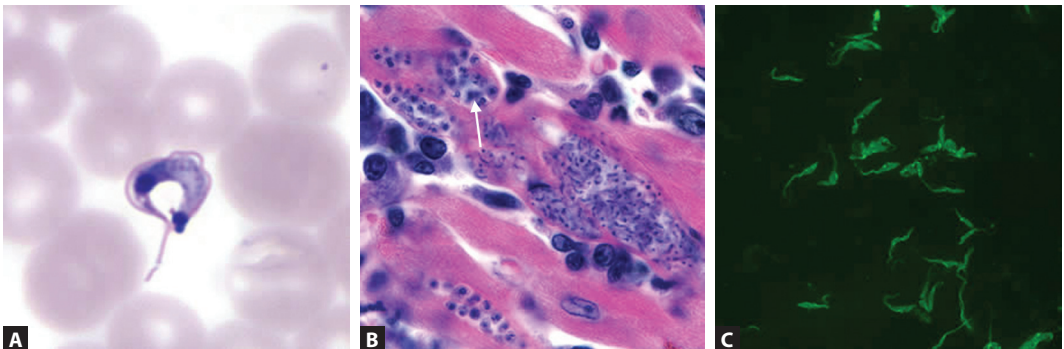
- Wet mount preparation of anticoagulated blood or buffy coat can be done to see the rapid movements of trypomastigotes
- **Thick and thin smear:** (Stained by Giemsa stain) thick smear is more sensitive in detecting the parasite whereas the thin smear helps in differentiating *T. cruzi* with morphologically similar looking *T. rangeli* (Table 5.7)
- Blood concentration techniques like micro-hematocrit method and Strout method of buffy coat preparation may be employed if the parasite count is low
- Amastigotes can be demonstrated in heart tissue obtained at autopsy stained by histopathological stain (Fig. 5.15B).

### Culture

Blood is inoculated in NNN medium or Yager's liver infusion tryptose medium, incubated at 25°C and observed for the epimastigote forms for up to 30 days before they are considered negative. Culture is more sensitive than smear microscopy.

### Antibody Detection

Chronic Chagas' disease is diagnosed by the detection of specific IgG antibodies against *T. cruzi* antigens. IgM antibodies are diagnostic for congenital infection.



**Figs 5.15A to C:** *Trypanosoma cruzi* (A) trypomastigote form (thin blood smear stained with Giemsa) (B) amastigote forms in heart tissue stained by hematoxylin and eosin (C) indirect fluorescent antibody test showing trypomastigote forms

Source: DPDx Image Library, Centre for Disease Control and prevention (CDC), Atlanta (with permission)

**Table 5.7:** Differences between trypomastigote form of *Trypanosoma cruzi* and *Trypanosoma rangeli*

	<i>Trypanosoma cruzi</i>	<i>Trypanosoma rangeli</i>
Pathogenicity	Pathogen, causes Chagas' disease	Nonpathogenic
Size of trypomastigote	Average 20 µm	Average 30 µm
Shape	Often 'C' shaped	Rarely 'C' shaped
Kinetoplast	Large and terminal	Small and sub-terminal
Posterior end	Short blunt	Long pointed
Location in reduviid bug	<ul style="list-style-type: none"><li>• Hindgut (feces)</li><li>• Transmitted by rubbing of reduviid bug's feces on abraded skin</li></ul>	<ul style="list-style-type: none"><li>• Usually found in salivary gland</li><li>• Transmitted by bite of bugs</li></ul>

- Several methods are employed like CFT (Guerreiro Machado test), ELISA, IFA (Fig. 5.15C), IHA (indirect hemagglutination test) and Western blot
- However, false positive reactions may occur in patients with *T. rangeli* infection, leishmaniasis, syphilis, etc
- Radioimmunoprecipitation assay (Chagas' RIPA) is a highly sensitive and specific (confirmatory) method for detecting antibodies to *T. cruzi*.

**Antigen Detection**

*T. cruzi* specific antigens from serum and urine of the infected patients are detected which are very useful for diagnosing acute infection and congenital transmission. Recently, a chemiluminescence immunoassay (CLIA) has been developed for blood bank screening and for the monitoring the response to treatment.

**Molecular Methods**

PCR is available that detects *T. cruzi* specific kinetoplast or nuclear DNA in blood. It is more sensitive than microscopy and serology for the diagnosis of chronic disease. It can detect as low as one trypomastigote per 20 mL of blood. It is also useful in monitoring the response to treatment and for the diagnosis of congenital infection.

**Animal Inoculation**

Blood or CSF of the patients is inoculated

intraperitoneally into mice. Trypomastigotes can be demonstrated from the blood of mice within 10 days of inoculation.

**Xenodiagnosis**

The infected patients are exposed to 20 numbers of laboratory maintained nymphs of reduviid bugs daily for 3 days and the dropping of the insects are examined monthly for 3 months for the presence of the epimastigote forms. This is more sensitive to detect light chronic infection.

Treatment	<i>Trypanosoma cruzi</i>
	<ul style="list-style-type: none"><li>• Therapy for Chagas' disease is still unsatisfactory. Only two drugs—(1) nifurtimox and (2) benznidazole have been available</li><li>• <b>In acute disease:</b><ul style="list-style-type: none"><li>➢ Benznidazole is considered as the drug of choice in Latin America. The recommended oral dosage is 5 mg/kg per day for adults and 5–10 mg/kg per day for children for 60 days</li><li>➢ Nifurtimox is given 8–10 mg/kg for adults and 15–20 mg/kg for children in four divided doses for 90–120 days</li></ul></li><li>• <b>In chronic disease:</b> These drugs lack efficacy and may cause many side effects.</li></ul>

**Prophylaxis**

Prevention of the disease in endemic countries depends on control of vector. This includes residual insecticides, health education and housing improvement.

## TRYPONASOMA BRUCEI COMPLEX

*T. brucei* was first demonstrated by Sir Bruce in 1895 from horses suffering from “nagana”. Forde in 1902 had demonstrated the parasite in man whereas Kleine had demonstrated the parasite in the vector tsetse fly. The name “*Trypanosoma*” was coined by Dutton in 1902. *T. brucei* complex consists of three subspecies:

1. ***T. brucei gambiense***: Agent of West African sleeping sickness
2. ***T. brucei rhodesiense***: Agent of East African sleeping sickness
3. ***T. brucei brucei***: Causes “nagana”, a disease affecting cattle in Africa. It doesn’t infect humans.

### Life Cycle (Fig. 5.16)

**Host:** *T. brucei* passes its life cycle in two hosts.

1. The **vertebrate host** is man and other animals

2. **Invertebrate host** is the **tsetse fly** (genus *Glossina*) (Fig. 16.6.) Both male and female flies bite man and serve as vectors. *Glossina palpalis* group serves as the vector for *T. brucei gambiense* whereas *Glossina morsitans* group is the vector for *T. brucei rhodesiense*.

**Infective form:** The metacyclic trypomastigote forms are found in salivary gland of tsetse fly

**Mode of transmission:** By the bite of tsetse fly, trypomastigote forms are transmitted to the punctured wound from the saliva of the tsetse fly (Fig. 5.16).

### Development in Man

- At the site of inoculation, they transform into long slender trypomastigote forms which multiply by binary fission
- They transform into an intermediate stage and then into nondividing short stumpy form without free flagellum
- Subsequently the parasites invade the blood

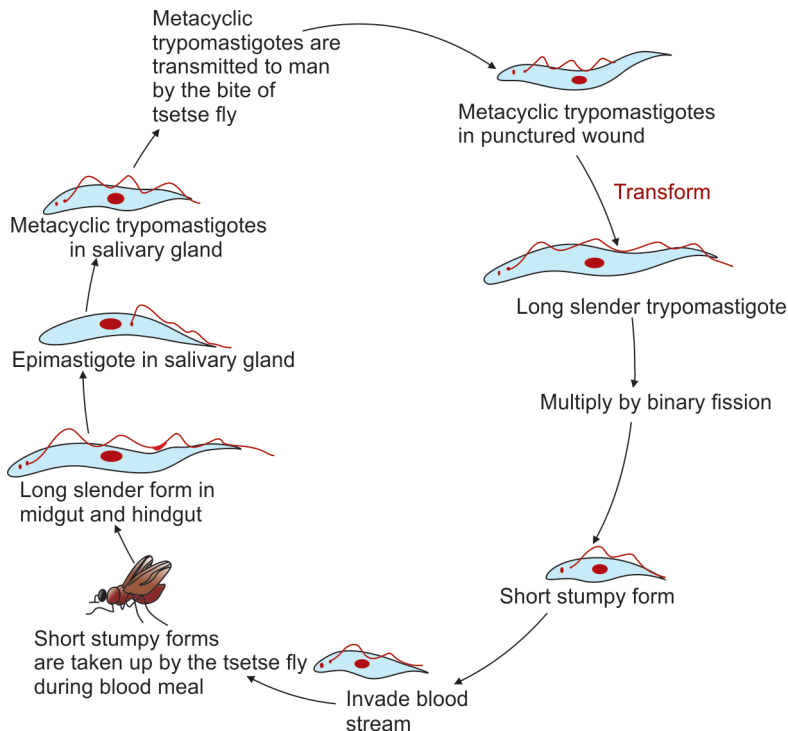


Fig. 5.16: Life cycle of *Trypanosoma brucei*

stream resulting in parasitemia and migrate to various organs including CNS

- The short stumpy forms are the infective form to the tsetse fly, hence the transformation of long slender trypomastigotes into short stumpy forms is critical for the transmission of the parasite.

**Development in Tsetse Fly**

- The short stumpy trypomastigote forms are taken up by the tsetse fly along with the blood meal
- They become long slender forms in the midgut and hindgut of the insect where they multiply and finally reach the salivary gland
- They attach to the epithelial cells of salivary ducts and transform into broad epimastigote forms
- Finally, the epimastigotes develop into metacyclic trypomastigote forms which are the infective forms to man
- It takes around 3 weeks from the time of blood meal till the fly becomes infective (extrinsic incubation period), then the fly remains infected throughout the life.

**Antigenic Variation**

Trypomastigotes undergo periodic antigenic variation leading to frequent change of antigenic nature of variable surface glycoprotein (VSG) antigens present on their surface. This serves as the key mechanism of evading host immune response.

- Genome of *Trypanosoma brucei* contains thousands of genes that undergo gene switching (like mutations, deletions, additions or recombinations) leading to formation of new **variant antigenic types (VATs)**.
- Every 5–10 days, a new wave of genes evolves, that code for a new batch of VATs. Host immunity is strain specific hence, is not able to eliminate the new waves of parasitemia.

**Pathogenesis and Clinical Feature**

In general, *T. brucei gambiense* develops a chronic course with slow progression whereas *T. brucei rhodesiense* runs an acute course with rapid progression and early death (Table 5.8).

**Table 5.8:** Comparison between *Trypanosoma brucei gambiense* and *Trypanosoma brucei rhodesiense*

	<i>Trypanosoma brucei gambiense</i>	<i>Trypanosoma brucei rhodesiense</i>
Disease	West African sleeping sickness	East African sleeping sickness
Vectors	Tsetse flies ( <i>Glossina palpalis</i> group)	Tsetse flies ( <i>Glossina morsitans</i> group)
Primary reservoir	Humans	Animals (Antelope and cattle)
Human illness	Chronic central nervous system (CNS) disease	Acute (early CNS disease) up to 9 months
Duration of illness	Months to years	< 9 months (before that the death occurs)
Lymphadenopathy	Frequent, cervical lymphadenopathy (winter bottom sign)	Minimal (Axially And inguinal)
Parasitemia	Low	High
Virulence	Less	More
Rodent inoculation	Not useful	Diagnostic
Epidemiology	Rural populations	Workers in wild areas, rural populations, and tourists in game parks
Respond to drugs	Less resistant	More resistant

### Trypanosomal Chancre

A self-limited inflammatory lesion may appear a week after the bite of an infected tsetse fly.

### Stage I Disease

It is characterized by a systemic febrile illness that occurs due to dissemination of the parasite through the lymphatics and bloodstream.

- Lymphadenopathy is prominent in West African trypanosomiasis. The posterior cervical nodes are commonly involved and become soft, rubbery and nontender called as **winterbottom's sign**
- Pruritus, maculopapular rashes and transient edema are common
- Delayed sensation to pain is noted (Kerandel's sign)
- Hepatosplenomegaly may be seen in few cases
- Hematologic manifestations include moderate leukocytosis, thrombocytopenia, anemia and production high levels of polyclonal IgM.

### Stage II Disease (Sleeping Sickness)

It involves invasion of the CNS. The presence of trypanosomes in perivascular areas of CNS is accompanied by intense infiltration of mononuclear cells.

- Patient develops characteristic progressive daytime somnolence (hence called as "**sleeping sickness**"), with restlessness and insomnia at night

#### Laboratory Diagnosis Trypanosoma brucei

- Direct microscopy—detects trypomastigotes
  - Serial blood sample examination
  - CSF examination
  - Lymphnode aspirate
- Antibodies from serum and CSF—card agglutination test, ELISA, IFA
- Antigen from serum and CSF—ELISA
- Molecular method—PCR
- Culture—inoculated into KIVI
- Animal inoculation in mice

- Other features include listless gaze, loss of spontaneity, and abnormal speech with few extrapyramidal signs like choreiform movements, tremors and fasciculations
- CSF findings include increased pressure, elevated total protein and pleocytosis, with frequently demonstration of trypanosomes.

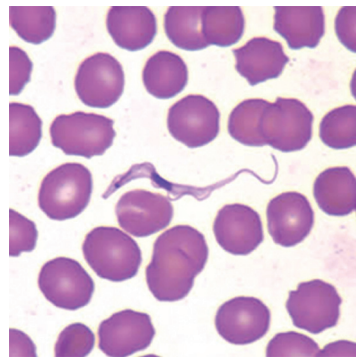
### Laboratory Diagnosis

#### Direct Microscopy

- **Specimen:** Useful samples are multiple blood samples (due to periodic release of trypomastigotes in blood), chancre fluid, CSF, lymphnode aspirate and bone marrow aspirate.

#### Serial blood sample examination

- **Wet mounting:** It is done to demonstrate highly motile trypomastigotes
- **Thin and thick films:** Smear is fixed and stained with Giemsa stain to visualize the trypomastigote forms. Detection limit of thick smear is 1 parasite/200 high power field and that of thin smear is 2000 parasite/mL (or 100/mL following centrifugation) (Fig. 5.17)
- If the parasitemia is low, then blood concentration methods are followed such as: **Microhematocrit centrifugation** using QBC capillary tube coated with Acridine orange. It claims sensitivity of 55–90%



**Fig. 5.17:** Trypomastigote form in peripheral blood smear examination (Giemsa stain)

Source: DPDx Image Library, Centre for Disease Control and prevention (CDC), Atlanta (with permission)

- **Mini anion exchange centrifugation:** Involves separation of trypomastogotes from blood using anion exchange chromatography followed by low speed centrifugation. It can detect as low as less than 100 organisms/mL.

**Cerebrospinal fluid examination**

Centrifuged deposit of the CSF is examined for the presence of **Mott cells** (also called as Morula or Mulberry cells). Mott cells are abnormal plasma cells containing large eosinophilic inclusions of IgM immunoglobulins. Other CSF findings include increased protein level, lymphocytosis, increased pressure and occasional presence of trypomastigotes.

**Lymphnode aspirate**

It is useful for *T. brucei gambiense* and shows variable sensitivity of 40–80%.

**Antibodies from Serum and CSF**

- Card agglutination test for trypanosomes (CATT) for *T. brucei gambiense* has been developed for field use and mass screening. This is highly sensitive (96%) but less specific
- Recently, newer methods like ELISA (using VSG antigen) and indirect fluorescent antibody (IFA) test are available to aid in the diagnosis but they have variable sensitivity and specificity
- Detection of serum and CSF IgM is of great diagnostic value.

**Antigens from Serum and CSF**

Antigen detection by ELISA is useful for clinical staging of disease to determine CNS

infection and for monitoring the response to treatment (antigens are rapidly cleared following improvement).

**Molecular Methods**

PCR assays have been developed which show a detection limit of 5 parasites/mL. Other molecular methods available are branched DNA assay, real time PCR, LAMP (loop mediated amplification technique) and FISH (fluorescent in situ hybridization).

**Culture**

Samples can be inoculated into KIVI (kit for *in vitro* isolation) and trypomastigotes are recovered in 7–10 days. However, culture is not routinely performed and only used as a standard for the evaluation of other diagnostic tests.

**Animal Inoculation in Mice**

It is highly sensitive for the isolation of *T. brucei rhodesiense* but not useful for *T. brucei gambiense*.

Treatment	Trypanosoma brucei complex
The drugs used for treatment of African sleeping sickness are suramin and pentamidine. Alternate drugs are eflornithine, and the organic arsenical melarsoprol. Treatment is based on type of disease (West or East African) and presence or absence of CNS invasion (Table 5.9).	

**Prophylaxis**

Vector control strategies like destruction of the insect’s habitats, elimination of reservoir

**Table 5.9:** Treatment of african trypanosomiasis

Causative organism	Stage I (normal cerebrospinal fluid)	Stage II (abnormal cerebrospinal fluid)
<i>Trypanosoma brucei gambiense</i> (West African)	Pentamidine Alternative: Suramin	Eflornithine Alternative: Melarsoprol
<i>Trypanosoma brucei rhodesiense</i> (East African)	Suramin	Melarsoprol



sources, etc can be done to control African trypanosomiasis. Vaccines are not available as the parasite undergoes frequent antigenic variations.

### EXPECTED QUESTIONS

#### I. Write essay on:

- (a) Classify hemoflagellates. Describe the life cycle, pathogenesis and laboratory diagnosis of *Leishmania donovani*?
- (b) Describe the life cycle, clinical feature and laboratory diagnosis of *Trypanosoma cruzi*?

#### II. Write short notes on:

- (a) Post kala azar dermal leishmaniasis
- (b) Cutaneous leishmaniasis
- (c) African sleeping sickness
- (d) Diffuse cutaneous leishmaniasis (DCL)
- (e) New world Leishmaniasis
- (f) Chagas' disease

#### III. Differentiate between:

- (a) West African sleeping sickness and East African sleeping sickness
- (b) Indian and East African PKDL
- (c) *Trypanosoma cruzi* and *Trypanosoma rangeli*

#### IV. Multiple choice questions (MCQs):

##### 1. Vector for leishmaniasis:

- (a) Sandfly
- (b) Reduviid bugs
- (c) Tsetse fly
- (d) *Anopheles* mosquito

##### 2. Old world leishmaniasis is caused by:

- (a) *Leishmania donovani*
- (b) *Leishmania tropica*
- (c) *Leishmania infantum*
- (d) All of the above

##### 3. New World leishmaniasis is caused by:

- (a) *Leishmania donovani*
- (b) *Leishmania braziliensis* complex
- (c) *Leishmania tropica*
- (d) *Leishmania major*

##### 4. Amastigote form of *Leishmania donovani* resides in the:

- (a) Gastrointestinal tract of insect vector
- (b) Salivary gland of mosquito
- (c) Cells of reticuloendothelial system
- (d) NNN culture media

##### 5. Oriental sore is caused by:

- (a) *Leishmania mexicana* complex
- (b) *Leishmania braziliensis* complex
- (c) *Leishmania tropica*
- (d) *Leishmania chagasi*

##### 6. *Leishmania donovani* can be cultivated in:

- (a) Blood agar
- (b) NNN medium
- (c) Diamond's medium
- (d) RPMI 1640 medium

##### 7. Chiclero's ulcer is caused by:

- (a) *Leishmania mexicana* complex
- (b) *Leishmania braziliensis* complex
- (c) *Leishmania peruviana*
- (d) *Leishmania chagasi*

##### 8. Espundia is caused by:

- (a) *Leishmania mexicana* complex
- (b) *Leishmania braziliensis* complex
- (c) *Leishmania peruviana*
- (d) *Leishmania chagasi*

##### 9. Best animal model used for inoculation of *Leishmania donovani*?

- (a) Hamster
- (b) Guinea pig
- (c) Rabbit
- (d) Mouse

##### 10. American trypanosomiasis (Chagas' disease) is caused by:

- (a) *Trypanosoma brucei gambiense*
- (b) *Trypanosoma rangeli*
- (c) *Trypanosoma brucei rhodesiense*
- (d) *Trypanosoma cruzi*

### Answers

1. (a) 2. (d) 3. (b) 4. (c) 5. (c) 6. (b) 7. (a) 8. (b) 9. (a) 10. (d)



# 6 Sporozoa—I (Malaria parasite and Babesia)

## Chapter Outline

- Classification
- Malaria Parasite
- Babesia
- Expected question

### ■ CLASSIFICATION

Phylum Sporozoa (Apicomplexa) is distinguished morphologically by the presence of a specialized complex of apical organelles (micronemes, rhoptries, polar ring, conoids and dense granules) which help in invasion into the host cell.

- Sporozoa contains one Class Coccidea which in turn has three Orders (1) Eimeriida (2) Haemosporida (3) Piroplasmida
- Order Haemosporida and Order Piroplasmida include the blood parasites belonging to genus *Plasmodium* (the causative agent

of malaria) and *Babesia* (rare parasites infecting humans) respectively (Table 6.1).

### ■ MALARIA PARASITE

#### History

Malaria is one of the oldest documented diseases of mankind.

- Cases of malaria were recorded in the ancient Indian, Chinese textbooks and evidences of patients died of malaria were found from Egyptian mummies of more than 3,000 years old
- The name “Malaria” (“Mal” means bad

**Table 6.1:** Classification of Phylum Sporozoa

Kingdom	Subkingdom	Phylum	Class	Order	Genus
Protozoa	Neozoa	Sporozoa (Apicomplexa)	Coccidea	Eimeriida	<i>Eimeria</i> <i>Toxoplasma</i> <i>Cryptosporidium</i> <i>Cyclospora</i> <i>Isospora</i> <i>Sarcocystis</i>
				Haemosporida	<i>Plasmodium</i>
				Piroplasmida	<i>Babesia</i>

and “aria” means air) was derived from the ancient false belief that “disease is spread by air pollution through stagnant water and marshy lands”

- French army surgeon Alphonse Laveran (1880) was the first to discover the causative agent *Plasmodium*, in the red blood cell (RBC) of a patient in Algeria
- Golgi had described the asexual cycle of the parasite in RBC
- Sir Ronald Ross, in 1897 had described the sexual cycle of the parasite in female *Anopheles* mosquito in Secunderabad, India
- Both Alphonse Laveran in 1902 and Sir Ronald Ross in 1907 won the Noble Prize for their contributions in malaria.

### The Causative Agent of Malaria

More than 125 species of *Plasmodium* exist infecting wide range of birds, reptiles and mammals. However, human infection is mainly caused by five species such as:

1. *P. vivax* causes benign tertian malaria. (periodicity of fever is once in 48 hours, i.e. recurs every third day)
2. *P. falciparum* causes malignant tertian malaria. (severe malaria, periodicity of fever is once in 48 hours, recurs every third day)
3. *P. malariae* causes benign quartan malaria. (periodicity of fever is once in 72 hours, i.e. recurs every fourth day)
4. *P. ovale* causes ovale tertian malaria. (periodicity of fever is once in 48 hours, i.e. recurs every third day)
5. *P. knowlesi* causes quotidian malaria. (fever periodicity is once in 24 hours, i.e. recurs every day). It is a parasite of monkey but can also affect humans and many cases affecting man were recently reported from Asia.

Other *Plasmodium* species are mainly of animal importance like *P. cynomolgi*, *P. simium*, etc.

### Life Cycle (Fig. 6.1)

**Host:** *Plasmodium* completes its life cycle in two hosts:

1. Female *Anopheles* (*Anopheline*) mosquito is the definitive host where the sexual cycle (sporogony) takes place
  2. Man acts as intermediate host where the asexual cycle (schizogony) takes place
- Male *Anopheles* doesn't feed on man and feeds exclusively on fruit juices, i.e. why male *Anopheles* doesn't transmit the disease. Whereas female *Anopheles* needs at least two blood meals before laying eggs
  - Out of 45 species of *Anopheline* mosquitoes in India, only a few are regarded as vectors of primary importance. These are: *Anopheline culicifacies* in rural areas, *A. stephensi* in urban areas and *A. fluviatilis* in hilly areas. Others are *A. minimus*, *A. philippinensis*, *A. sundaicus* and *A. maculatus*.

### Human Cycle

**Infective form:** The sporozoites are the infective form of the parasite. They are present in the salivary gland of female *Anopheles* mosquito.

When *Plasmodium* species is transmitted by blood transfusion or through placenta, merozoites act as infective form.

**Mode of transmission:** Man gets infection by the bite of female *Anopheles* mosquito. Sporozoites from the salivary gland of the mosquito are directly introduced into the blood circulation.

Rarely, it can also be transmitted by:

- Blood transfusion
- Transplacental transmission.

In humans, the asexual cycle takes place through the following stages:

- Pre-erythrocytic schizogony
- Erythrocytic schizogony
- Gametogony.

### Pre-erythrocytic Schizogony

This stage occurs in liver and it is so named

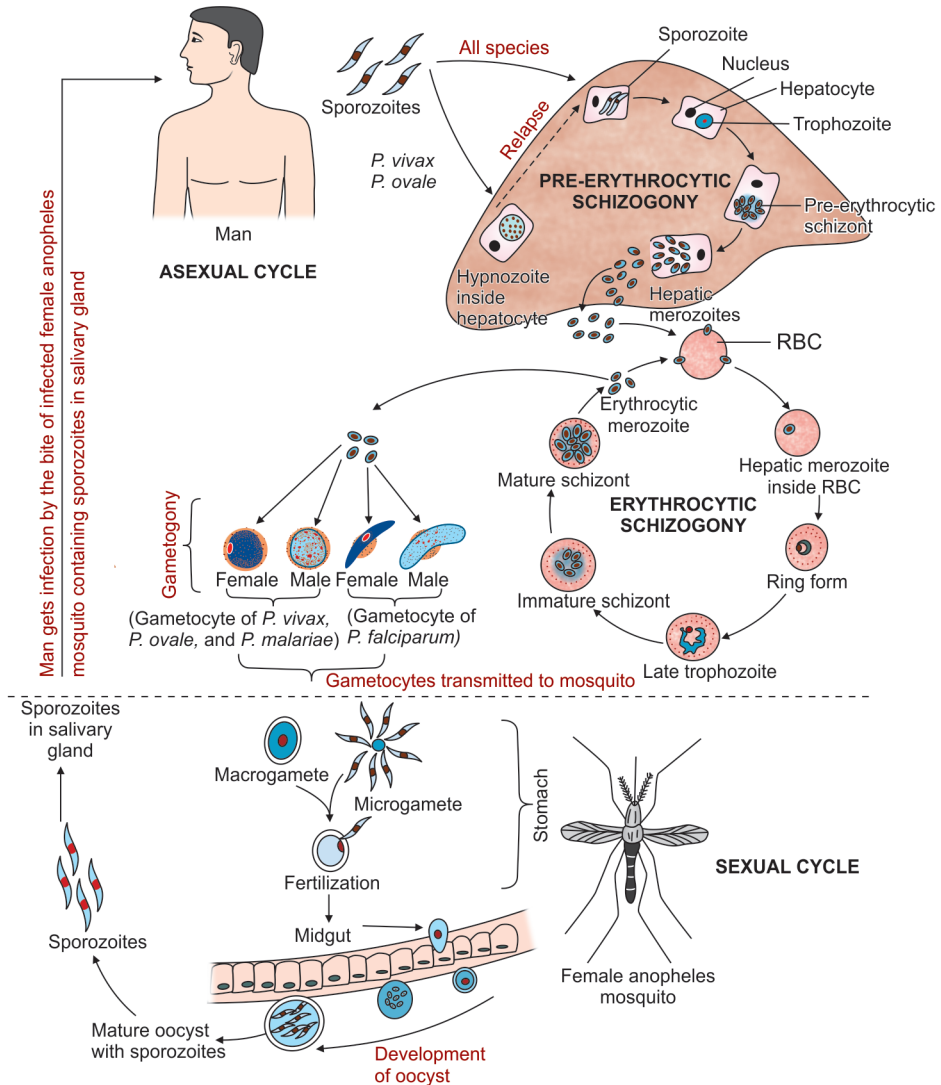


Fig. 6.1: Life cycle of malaria parasite

because it occurs before the invasion of RBC.

- It is also called Exoerythrocytic stage or intrahepatic or tissue stage
- The motile sporozoites leave the circulation within 30 minutes and enter liver
- **Attachment:** The circumsporozoite protein present on the surface of sporozoites binds noncovalently to the receptors on the basolateral surface of hepatocytes facilitating the entry of sporozoites

- After entering into hepatocytes, the spindle shaped sporozoites become rounded and lose their apical complex and transform into trophozoites
- **Trophozoite** is the feeding stage of the parasite which later on undergoes several nuclear divisions (**schizogony**) and transforms into pre-erythrocytic schizont
- **Pre-erythrocytic schizont** contains several merozoites; which are released outside

on rupture and attack RBCs to perform erythrocytic schizogony

- As only few hepatocytes are infected by *Plasmodium*, so hepatic damage doesn't occur in malaria
- Duration of pre-erythrocytic schizogony varies from 5 days to 15 days depending on the species (Table 6.2)
- Some sporozoites of *P. vivax* and *P. ovale* don't develop further and may remain in liver as hypnozoites and cause relapse of malaria after many years
- **Relapse** should be differentiated from another phenomena seen in *P. falciparum* and *P. malariae* called as **recrudescence** (Table 6.3).

### Erythrocytic schizogony

The hepatic merozoites after released from pre-erythrocytic schizont, attack RBCs.

- Merozoites bind to the glycophorin receptors on RBC surface, enter by endocytosis and are contained within a parasitophorous

vacuole inside the RBCs. The process of entry into RBC takes about 30 seconds

- **Trophozoite:** Soon the pear shaped hepatic merozoites round up, lose their internal organelle and transform into trophozoites
- **Ring form:** Early trophozoite form is known as ring form. It is annular or signet ring appearance containing a central vacuole and peripheral thin rim of cytoplasm and a nucleus
- Ring form occupies one-third of RBC except in *P. falciparum*, where it occupies one-sixth of RBC
- **Prepatent period:** Ring forms are the first asexual form that can be demonstrated in the peripheral blood. The time interval between the entry of the parasite into man and demonstration of the parasite in the peripheral blood is called as **prepatent period**. It varies between the species:
  - *P. vivax*—8 days
  - *P. falciparum*—5 days

**Table 6.2:** Characteristic feature of pre-erythrocytic schizogony

Characteristic feature	<i>Plasmodium falciparum</i>	<i>Plasmodium vivax</i>	<i>Plasmodium ovale</i>	<i>Plasmodium malariae</i>
Duration of Pre-erythrocytic schizogony	5.5 days	8 days	9 days	15 days
Number of merozoites per infected Pre-erythrocytic schizont	30,000	10,000	15,000	15,000
Pre-erythrocytic schizont size	60 µm	45 µm	60 µm	55 µm

**Table 6.3:** Relapse and recrudescence in malaria

Relapse	Recrudescence
<ul style="list-style-type: none"> <li>• Seen in <i>Plasmodium vivax</i> and <i>P. ovale</i> infections</li> <li>• Few sporozoites don't develop into pre-erythrocytic schizont, but remain dormant (known as <i>hypnozoites</i>) for 3 weeks to one year</li> <li>• Reactivation of hypnozoites leads to initiation of erythrocytic cycle and relapse of malaria</li> </ul>	<ul style="list-style-type: none"> <li>• Seen in <i>P. falciparum</i> and <i>P. malariae</i> infections</li> <li>• Falciparum malaria—recrudescence is due to persistence of drug resistant parasites, even after completion of treatment</li> <li>• In <i>P. malariae</i> infection, long-term recrudescences are seen for as long as 60 years This is due to long-term survival of erythrocytic stages at a low undetectable level in blood</li> </ul>
<p>Concept of secondary exo or pre-erythrocytic stage—</p> <ul style="list-style-type: none"> <li>• Formerly, it was postulated that relapse occurs due to secondary exo or pre-erythrocytic stage where a proportion of hepatic merozoites released from pre-erythrocytic schizont, again attack the liver cells</li> <li>• But now, it is believed that secondary pre-erythrocytic stage doesn't occur and relapse occurs due to sporozoites undergoing dormancy during the primary pre-erythrocytic stage</li> </ul>	

- *P. malariae*—13 days
  - *P. ovale*—9 days
- **Malarial pigment**
  - *Plasmodium* feeds on hemoglobin. The undigested product of hemoglobin metabolism like hematin, excess protein and iron porphyrin combine to form malarial pigment (hemozoin pigment)
  - The appearance of malarial pigment varies, mostly it is brown black in color and numerous (except in *P. vivax* it is yellowish brown in color and in *P. falciparum*, it is few in number)
- **Late trophozoite:** Ring form enlarges and becomes more irregular due to amoeboid movement and transforms into late trophozoite or amoeboid form
- **Erythrocytic schizont:** Late trophozoites become compact, vacuoles disappear, pigments scatter throughout cytoplasm and nucleus becomes larger and lies at the periphery. This form is known as **erythrocytic schizont**
- **Schizogony:** Erythrocytic schizont undergoes multiple nuclear divisions (erythrocytic schizogony or merogony) and produces 6–30 daughter merozoites arranged in the form of rosette
- Number of merozoites per mature schizont varies:
  - *P. vivax*—12–24 number (average 16)
  - *P. falciparum*—18–24 number (average 20)
  - *P. malariae*—6–12 number (average 8)
  - *P. ovale*—8–12 number (average 8)
- RBCs then rupture to release the daughter merozoites, malarial pigments and toxins into the circulation which result in malarial paroxysm of fever at the end of each erythrocytic cycle
- Each merozoite is potentially capable of invading a new RBC and repeating the cycle. Intraerythrocytic life cycle takes roughly 48 hours for *P. falciparum*, *P. vivax* and

*P. ovale*, 72 hours for *P. malariae* and 24 hours for *P. knowlesi*

- **Incubation period:** The time interval between entry of the parasite to the body and appearance of the first clinical feature is known as **incubation period**. It varies between the species:
  - *P. vivax*—14 days (ranges 8–17 days)
  - *P. falciparum*—12 days (ranges 9–14 days)
  - *P. malariae*—28 days (ranges 18–40 days)
  - *P. ovale*—17 days (ranges 16–18 days)
- In *P. falciparum* infection, the later stages of erythrocytic cycle occur in the capillaries of brain and internal organs. Hence, only the ring forms are found in the peripheral blood by microscopic examination but not late trophozoites and schizonts
- However, for other species, the entire erythrocytic stage takes place in peripheral blood vessel.

### Gametogony

After a series of erythrocytic cycles, some merozoites after entering into RBCs, instead of developing into trophozoites, they transform into sexual forms called as **gametocytes**.

- The gametocytic development takes place in the blood vessels of internal organs such as spleen and bone marrow and only the mature gametocytes appear in the peripheral blood
- The gametocytes of all the species are round in shape except in *P. falciparum* in which they are crescent or banana shaped
- They are of two types—(1) male gametocyte (or microgametocyte) and (2) female gametocyte (or macrogametocyte)
- Microgametocytes in all the species are smaller in size, lesser in number, their cytoplasm stains pale blue, and nucleus is larger, stains red and diffuse
- In contrast, macrogametocytes are larger, numerous, their cytoplasm stains deep blue, nucleus is small, red and compact

- The time of appearance of gametocytes in the circulation from the first appearance of asexual forms (i.e. ring forms) in the peripheral blood varies between the species
  - *P. vivax*—4–5 days
  - *P. falciparum*—10–12 days
  - *P. malariae*—11–14 days
  - *P. ovale*—5–6 days
- Neither gametocytes don't cause any clinical illness nor they divide
- Individuals harboring gametocytes are considered as carriers or reservoirs of infection and play an important role in the transmission of the disease
- A patient can be a carrier of several *Plasmodium* species at the same time
- However, gametocytes are effective in transmission of the infection if they are:
  - **Mature**; immature forms are not transmitted
  - **Viable**, i.e. dead gametocytes are ineffective
  - Present in **sufficient density** to infect mosquitoes. The number of gametocytes necessary to infect mosquitoes is **12 per cubic mm** of blood.

### Mosquito Cycle

A female *Anopheles* mosquito during the blood meal, takes both the asexual forms and the sexual forms.

- The asexual forms get digested whereas the sexual forms, i.e. the gametocytes undergo further development (hence considered as infective form of the parasite to mosquito)
- **Exflagellation:**
  - Nucleus of the male gametocytes divides into eight flagellated actively motile bodies (15–20  $\mu\text{m}$  length) called as **microgametes**.
  - Microgametes protrude out as thread like filaments, lash out for some time and then, break free
  - This process is called as **exflagellation**. At 28°C, it is completed in 15 minutes for *P. vivax* and 15–30 minutes for *P. falciparum*
- Female gametocytes don't divide and don't undergo exflagellation but each undergoes maturation to form one **macrogamete or female gamete**
- **Zygote:** The male microgamete fertilizes with the female macrogamete by fusion of their pronuclei and the zygote is formed. Fertilization occurs in about 30 minutes to 2 hours after the blood meal
- **Ookinete:** Within 24 hours, the nonmotile rounded zygote transforms into vermiform motile elongated form with an apical complex (the ookinete stage). Till this stage, the development takes place in the midgut of the mosquito
- **Oocyst:** The ookinete penetrates into the stomach wall of the mosquito and lies just beneath the basement membrane. It becomes rounded and covered by a thin elastic membrane to form oocyst. This is the stage discovered by Sir Ronald Ross. Several thousands of mature oocysts can be found; each measuring 500  $\mu\text{m}$
- **Sporozoites:** Oocysts undergo sporogony (meiosis) to produce thousands of spindle shaped sporozoites measuring 10–15  $\mu\text{m}$  length with apical complex anteriorly
- On rupture of the mature oocyst, the sporozoites are released and migrate to salivary gland
- Mosquito is said to be infective to man only when the sporozoites are present in salivary gland. Once infected, it remains infective throughout the life
- **Extrinsic incubation period:** Time required to complete the life cycle in mosquito is called as extrinsic incubation period and it varies from 1 week to 4 weeks. At 25°C, it is:
  - *P. vivax*—8–10 days
  - *P. falciparum*—9–10 days
  - *P. malariae*—25–28 days
  - *P. ovale*—14–16 days
- **Mixed infection:** Different species of *Plasmodium* can infect the same mosquito which in turn can transmit mixed infections to man, accounts for 4–8% of total infection.



**Table 6.4:** Differences between the four malaria parasites

Properties	<i>Plasmodium vivax</i>	<i>Plasmodium falciparum</i>	<i>Plasmodium malariae</i>	<i>Plasmodium ovale</i>
Relapse (Hypnozoites)	Seen	Not seen	Not seen	Seen
Recrudescence	Not seen	Seen	Seen (Upto 60 years)	Not seen
Erythrocytic cycle	48 hours	36–48 hours	72 hours	48 hours
Prepatent period	8 days	5 days	13 days	9 days
Incubation period	14 days	12 days	28 days	17 days
R-G interval <sup>a</sup>	4–5 days	10–12 days	11–14 days	5–6 days
Extrinsic IP <sup>b</sup>	8–10 days	9–10 days	25–28 days	14–16 days

Abbreviations: <sup>a</sup>R-G interval, interval between appearance of ring form and gametocyte; <sup>b</sup>IP, incubation period

The mixed infection is seldom observed in endemic areas; most common being *P. vivax* and *P. falciparum* mixed infection

- Differences between the four malaria parasites are described in Table 6.4, 6.5 and Fig. 6.2.

## Pathogenesis and Clinical Feature

### Benign Malaria

Benign malaria is milder in nature, can be caused by all four species. It is characterized by a triad of febrile paroxysm, anemia and splenomegaly.

#### Febrile paroxysm

Fever comes intermittently depending on the species. It occurs every fourth day (72 hour cycle for *P. malariae*) and every third day (48 hour cycle for other three species)

- Paroxysm corresponds to the release of the successive broods of merozoites into the bloodstream, at the end of RBC cycle
- Each paroxysm of fever is comprised of three stages—(1) cold stage (2) hot stage and (3) sweating stage
  - **Cold stage:** Lasts for 15 minutes to 1 hour. The patient feels lassitude, headache, nausea, intense cold, chill and rigor
  - **Hot stage:** Patient develops high grade fever of 39–41°C and dry burning skin. Headache persists but nausea

diminishes

- **Sweating stage:** Fever comes down with profuse sweating. Skin becomes cold and moist. Patient feels relieved and often asleep. This stage lasts for 2–4 hours

- The classical paroxysm may not be present always due to maturation of generations of parasites at different times
- In *P. falciparum*, the fever is more irregular or even continuous with marked prostration, headache and nausea.

#### Anemia

After a few paroxysms of fever, patient develops a normocytic normochromic anemia. Various factors can attribute to the development of anemia such as:

- Parasite induced RBC destruction—Lysis of RBC due to release of merozoites
- Splenic removal of both infected RBC and uninfected RBC coated with immune complexes
- Bone marrow suppression leading to decrease RBC production
- Increased fragility of RBCs
- Autoimmune lysis of coated RBCs

#### Splenomegaly

After a few weeks of febrile paroxysms, spleen gets enlarged and becomes palpable. Splenomegaly is due to massive proliferation of



macrophages that engulf parasitized and nonparasitized coated RBCs.

### **Falciparum Malaria (Malignant Tertian Malaria)**

#### **Pathogenesis of falciparum malaria**

*Plasmodium falciparum* possesses a number of virulence factors and its pathogenesis is different from other species. Hence the disease is more acute and severe in nature with more complications than the benign malaria.

**Sequestration of the parasites:** An important feature of the pathogenesis of *P. falciparum* is its ability to sequester (holding back) the parasites in the blood vessels of deep visceral organs like brain, kidney, etc. This leads to blockade of vessels, congestion and hypoxia of internal organs. Sequestration is mediated by:

- **Cytoadherence:** It refers to binding of infected erythrocytes to endothelial cells. It is mediated by a specialized antigen called as *P. falciparum* **erythrocyte membrane protein-1 (PfEMP-1)**
  - Infected RBCs become sticky and develop protuberances in their cell membrane called as **Knobs** that express high level of PfEMP-1 antigen

- **PfEMP-1** binds to specific receptors present on the endothelium leading to adherence of parasitized RBCs to the vascular endothelium of deep organs
- The endothelial receptors are CD36 molecule (present in most of the organs), ICAM-1 (intracytoplasmic adhesion molecule-1, usually expressed on cerebral vessels) or chondroitin sulfate (on placental endothelium)

- **Rosetting:** It refers binding of infected erythrocytes to uninfected erythrocytes. PfEMP-1 also plays an important role in rosetting, as it can adhere to complement receptor 1 (CR1) and blood group A antigen present on the uninfected erythrocytes
- **Deformability:** Parasitized RBCs become more spherical and rigid, and are less filterable than uninfected cells
- Since the parasites are sequestered back in deep vessels, they can avoid frequent spleen passage, hence can escape splenic clearance
- PfEMP undergoes frequent antigenic variation, thus helps the parasite in evading the host immune response.

**High level of parasitemia:** *P. falciparum* infection is associated with high level of parasitemia

**Table 6.5:** Differences between the four malaria parasites

<b>Parasitic changes</b>	<b><i>Plasmodium vivax</i></b>	<b><i>Plasmodium falciparum</i></b>	<b><i>Plasmodium malariae</i></b>	<b><i>Plasmodium ovale</i></b>
• Forms seen in peripheral blood smear examination	Trophozoites (early and late), gametocytes and schizonts	Ring forms (early trophozoites) and gametocytes	Similar to that of <i>P. vivax</i>	Similar to that of <i>P. vivax</i>
• Ring form (Early trophozoite)	Ring 2.5 µm size, Vacuole in the center, Peripheral thin rim of blue cytoplasm, surrounding the red nucleus. Ring occupies one-third of size of red blood cells (RBCs) Cytoplasm opposite to the nucleus is thick	Ring 1.5 µm size, smaller than in <i>P. vivax</i> , occupying one-sixth of RBC <i>Variants of ring forms:</i> <ul style="list-style-type: none"> <li>• Multiple rings,</li> <li>• Accole (appliqué) forms</li> <li>• Double dot/head phone shaped ring form</li> </ul>	Similar to that of <i>P. vivax</i> but thicker	Similar to that of <i>P. vivax</i> , more compact

Contd...

Contd...

<b>Parasitic changes</b>	<b><i>Plasmodium vivax</i></b>	<b><i>Plasmodium falciparum</i></b>	<b><i>Plasmodium malariae</i></b>	<b><i>Plasmodium ovale</i></b>
• Late trophozoite	Large, amoeboid, cytoplasm, prominent vacuole	Small, compact, rounded, slightly amoeboid, vacuole inconspicuous, not seen in smear	Small, compact, band forms seen, vacuole inconspicuous	Small, compact, rounded, coarse pigment, vacuole inconspicuous
• Schizont	Large, 9-10 $\mu\text{m}$ , completely fills the enlarged RBC	Small, 4.5-5 $\mu\text{m}$ size, Fills two-third of normal sized RBC	Small, 6.5-7 $\mu\text{m}$ size, almost fills a normal sized RBC	Small, 6.2 $\mu\text{m}$ size, Fills three-fourth of enlarged oval RBC
• Merozoites/schizont (numbers)	12-24	18-24	6-12	8-12
• Gametocyte	Spherical, almost occupies the RBC	Banana shaped, larger than RBC size.	Similar to that of <i>P. vivax</i>	Similar to that of <i>P. vivax</i>
– Female Gametocyte	<ul style="list-style-type: none"> <li>• Spherical</li> <li>• Larger than male</li> <li>• Cytoplasm stains deep blue</li> <li>• Nucleus stains red compact and eccentric</li> <li>• Pigments- coarse, diffuse</li> </ul>	<ul style="list-style-type: none"> <li>• Crescentic (banana)</li> <li>• Long slender and pointed tips</li> <li>• Larger than RBC</li> <li>• Cytoplasm stains deep blue,</li> <li>• Nucleus stains red, compact and central,</li> <li>• Pigments- compact</li> </ul>	Similar to that of <i>P. vivax</i>	Similar to that of <i>P. vivax</i>
– Male Gametocyte	Same as female but <ul style="list-style-type: none"> <li>• Smaller</li> <li>• Cytoplasm—pale blue</li> <li>• Nucleus—diffuse</li> </ul>	Same as female but <ul style="list-style-type: none"> <li>• Broader and shorter</li> <li>• Rounded tips</li> <li>• Cytoplasm stains pale blue</li> <li>• Both nucleus and pigments—diffuse and scattered</li> </ul>	Similar to that of <i>P. vivax</i>	Similar to that of <i>P. vivax</i>
<b>Changes in RBCs</b>				
• RBCs infected	Young RBCs	RBCs of all age	Old RBCs	Young RBCs
• RBC size	Enlarged, Round (frequently bizarre form)	Normal in size	Normal in size	Enlarged, oval, fimbriated margin
• Stippling*	Schuffner's dots (small red dots)	Maurer's cleft (large red spots)	Ziemann's dots (small red dots)	James's dots (small red dots)
• Malarial Pigments	Yellowish brown	Dark brown	Dark brown	Dark yellowish brown

**\*Stippling:** Pink to red coloured dots on the surface of RBCs, are seen when stained properly. They are membrane bound structures in the cytoplasm of RBCs, infected with *Plasmodium* which help in protein transport from the parasite to the erythrocyte surface.

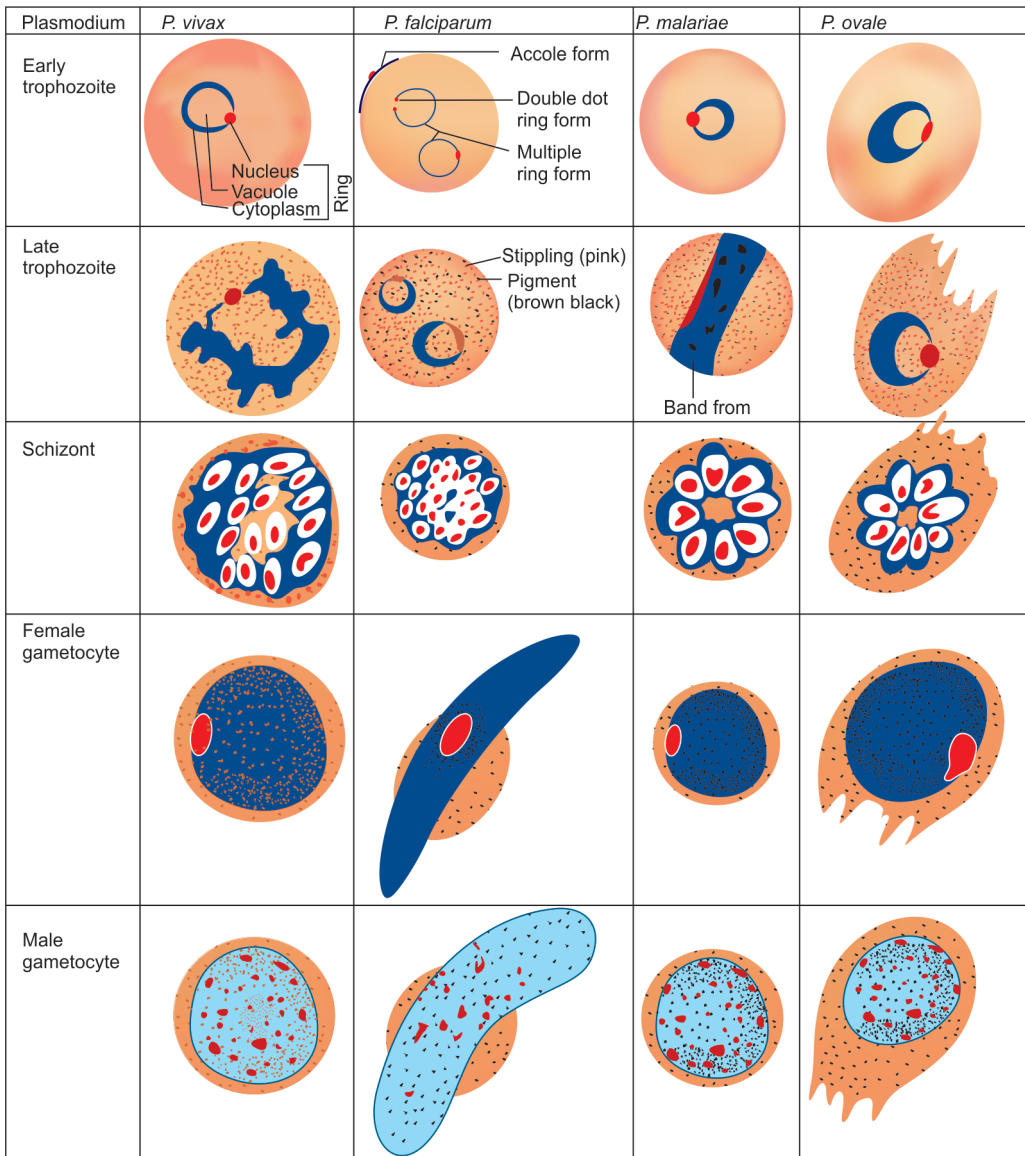


Fig. 6.2: Morphological forms of malaria parasites

(30–40% of total RBC are infected) compared to other species (< 2%)

**Other virulence factors like:**

- Knob associated histidine rich protein II (HRP-II)
- **Glycosyl phosphatidyl inositol (GPI):** Parasitic GPI stimulates the host immune system to release cytokines like IL-1, TNF and IFN- $\gamma$ .

## Complications

### Complications of Falciparum Malaria

- **Cerebral malaria:**
  - Occurs due to plugging of brain capillaries by the rosettes of sequestered parasitized RBCs leading to vascular occlusion and cerebral anoxia
  - Cerebral malaria manifests as diffuse

symmetric encephalopathy characterized by generalized convulsion in 10% of adults and up to 50% of children

- Muscle tone and tendon reflexes are reduced
  - Other defects are retinal hemorrhages, neurologic sequelae, repeated seizures, and rarely deep coma
  - Signs of focal neurologic and meningeal irritations are absent
  - High mortality rate—20% among adults and more than 15% among children
- **Pernicious malaria:** It is characterized by blackwater fever, algid malaria and septicemic malaria
- **Black water fever:**
  - This syndrome is characterized by sudden intravascular hemolysis followed by fever, hemoglobinuria and dark urine
  - It occurs following quinine treatment to subjects previously infected with *P. falciparum*
  - The precise mechanism is not known
  - Autoimmune mechanism has been suggested. Antibodies develop against parasitized and quinized RBCs. With subsequent infection and quinine treatment, there is immunocomplex formation followed by complement mediated massive destruction of both parasitized and nonparasitized RBCs
- **Algid malaria:** Characterized by cold clammy skin, hypotension, peripheral circulatory failure and profound shock
- **Septicemic malaria:** Characterized by high degree of prostration, high grade fever with dissemination of the parasite to various organs leading to multi organ failure
- **Pulmonary edema and adult respiratory distress syndrome:** Severe falciparum malaria in adults may lead to non cardiogenic pulmonary edema often aggravated by over hydration. Usually it doesn't respond to antimalarial therapy mortality rate more than 80%
- **Hypoglycemia:** Hypoglycemia is associated with a poor prognosis and is particularly

problematic in children and pregnant women and following quinine therapy

- **Renal failure:** It occurs due to erythrocyte sequestration in renal microvasculature leading to acute tubular necrosis. It is common among adults than children
- **Bleeding/disseminated intravascular coagulation:** Patient presents with significant bleeding and hemorrhages from the gums, nose and gastrointestinal tract with or without evidence of disseminated intravascular coagulation
- **Severe jaundice:** More common among adults than children; it results from hemolysis, hepatocyte injury and cholestasis
- **Severe normochromic, normocytic anemia:** Characterized by hematocrit of less than 15% or hemoglobin level of less than 5 g/dL with parasitemia level of more than 100,000/ $\mu$ L ( $> 2\%$ )
- **Acidosis:** Results from accumulation of organic acids like lactic acid.

### Chronic Complications of Malaria

#### *Tropical splenomegaly syndrome (hyperactive malarial splenomegaly)*

- It occurs in people of malaria-endemic areas in tropical Africa and Asia (including India)
- It results from an abnormal immunologic response to repeated malaria infections and is characterized by:
  - Cytotoxic IgM antibodies to CD8+ T lymphocytes
  - Elevated IgM (due to polyclonal B cell activation)
  - Massive splenomegaly
  - Hepatic sinusoidal lymphocytosis
  - Peripheral B cell lymphocytosis (in Africa)
- Patients respond well to antimalarial chemoprophylaxis (proguanil).

#### *Quartan malarial nephropathy*

It is a chronic complication seen with *P. malariae* (and possibly with other malarial species). It occurs due to injury to the renal

glomeruli by the immune complexes, resulting in nephrotic syndrome.

### **Promotes Burkitt's lymphoma**

Malaria induced severe immunosuppression in African children provoke Epstein-Barr virus infection to develop Burkitt's Lymphoma.

## **Malaria in Special Situations**

### **Transfusion malaria**

Malaria can be transmitted by blood transfusion, needle-stick injury, or organ transplantation. The clinical features and management of these cases are same as for naturally acquired infections (mosquito borne) but differs in many other ways:

- The infective form is trophozoite
- There is no pre-erythrocytic stage of development and no relapse
- The incubation period is often short
- Radical chemotherapy with primaquine is unnecessary as there is no relapse.

### **Malaria in pregnancy**

Malaria during pregnancy increases the risk of fetal distress and can result in premature labor low birth weight and still birth

- In areas of stable transmission of malaria, the infected mothers remain asymptomatic despite of heavy parasitemia
- However, in areas with unstable and high malaria transmission, pregnant women are particularly vulnerable to severe anemia, hypoglycemia and acute pulmonary edema.

### **Malaria in children**

Nearly 1 million children die of falciparum malaria each year in endemic countries.

Certain complications are relatively common among children like convulsions, coma, hypoglycemia, metabolic acidosis and severe anemia whereas other complications like deep jaundice, acute renal failure, and acute pulmonary edema are unusual in children.

### **Plasmodium knowlesi**

It is a malaria parasite of monkey ( long tailed *Macaca fascicularis* and pig tailed *Macaca*

*nemestrina*), but can also rarely affect humans.

- *Anopheles leucosphyrus* is the main vector
- The first human case was documented in 1965, however, recently many cases affecting men are reported from Asia (2008 onward), largest foci in Malaysia, Thailand and Singapore
- No cases reported from India so far. However, India has all the potential of getting cases because *A. leucosphyrus* is found in the South-West zone (costal region of Kerala and Maharashtra)
- **Clinical features:** *P. knowlesi* produces an acute illness and relatively high parasitemia. Paroxysms of fever occur daily (quotidian malaria) because of short RBC cycle (24 hours)
- **Lab diagnosis:**
  - On blood smear examination, early trophozoite of *P. knowlesi* is indistinguishable from *P. falciparum*, sometimes shows multiple ring forms and double dot ring forms
  - The late trophozoites (with band forms), schizonts (8–10 merozoites arranged in a rosette) and round gametocytes of *P. knowlesi*, are morphologically similar to that of *P. malariae*
  - Currently, no commercially available rapid diagnostic tests (RDTs) are designed to specifically detect *P. knowlesi*
  - *P. knowlesi* specific nested polymerase chain reaction (PCR) assays are available using the primers Pmk8 and Pmkr9.

## **Immunity Against Malaria**

Both innate and acquired immunity contribute to the resistance against malaria.

### **Innate Immunity**

This refers to the inherent and nonimmune mechanisms of host resistance against malaria parasite. This could be due to various factors:

- **Age of red blood cells:** *P. falciparum* attacks

RBCs of any age, *P. vivax* and *P. ovale* attack the young RBCs and reticulocytes whereas *P. malariae* attacks older RBCs

- **Nature of hemoglobin:** Sickle cell disease, hemoglobin C and E, fetal hemoglobin and thalassemia hemoglobin are resistance to falciparum malaria
- **Hereditary ovalocytosis:** In this condition, the rigid RBCs are resistant to falciparum malaria
- **Red blood cells with glucose-6-phosphate dehydrogenase (G6PD) deficiency** are resistant to falciparum malaria
- **Duffy negative red blood cells:** Duffy blood group antigens present on RBC membrane act as receptors for *P. vivax*. So, people with duffy negative RBCs (West Africans) are resistant to vivax malaria
- **HLA-Bw53** and haplotypes bearing DRW-13.02 antigen and R111 gene are protected from cerebral malaria
- **Nutritional status:** It has a paradoxical effect. Severe malaria is seldom evident in children suffering from malnutrition.

### Acquired Immunity

Both cellular and humoral immunity contribute to the resistance against malaria.

- **Humoral immunity:** Circulating antibodies (IgA, IgM and IgG) against asexual forms give protection by inhibiting the red cell invasion and sequestration, whereas antibodies against sexual forms help in reducing the transmission of malaria
- **Cellular immunity:** It also plays role in providing protection against malaria. Cytokines released from T cells stimulate the macrophages and also stimulate the B cells to produce antibodies. The activated macrophages phagocytize or induce extracellular killing of parasitized RBCs. Natural killer (NK) cells mediated cellular cytotoxicity also takes place against the parasitized RBCs
- Immunity against malaria attack is species

specific, stage specific and strain specific. Immune defense of the host is sufficient to resist further infection but insufficient to destroy the parasite. Immunity lasts till the original infection remains active and prevents further infection. This is called as **infection immunity** or **premunition** or **concomitant immunity** or **incomplete immunity**.

### Epidemiology of Malaria

Malaria is the most lethal parasitic disease of humans, transmitted in 108 countries containing 3 billion people.

- Worldwide, the incidence of malaria is estimated to be 300–500 million clinical cases with nearly 1 million deaths every year
- The tropical zone is affected the most. The most common malaria affected regions are Sub-Saharan Africa (accounts for 85% of total infection) followed by South East Asia Region (SEAR) (10%) and Mediterranean (4%)
- *P. vivax* is the predominant species and has the widest geographical distribution throughout the world
- **Age:** Children are more prone to infection and complications. However, newborn are protected from falciparum malaria because of high concentration of fetal hemoglobin in first few months of life
- **Predisposing factors:** The transmission of malaria is directly proportional to:
  - Density of the vector
  - Number of human bites per day per mosquito
  - Time of mosquito bite (more after the dusk)
  - Mosquito longevity (as sporogony lasts for 7–30 days, thus, to transmit malaria, the mosquito must survive for > 7 days)
  - Optimum temperature (20–30°C)
  - Optimum humidity (60%)
  - Rainfall (July to November)
  - Altitude below 2,000 meters.



**Table 6.6A:** Epidemiological classification of malaria depending on endemicity

Endemicity of malaria	Parasite rates <sup>a</sup>	Spleen rate <sup>b</sup>	Indicates
Hypoendemic	<10%	<10%	Transmission is low and malaria is not an important problem
Mesoendemic	11–50%	11–50%	Transmission is moderate
Hyperendemic	51–75%	51–75%	Transmission is intense but seasonal (rainy season)
Holoendemic	>75%	>75%	Transmission is intense and constantly present.

- <sup>a</sup>Parasite rate- % of children between 2–10 years showing malaria parasites in their blood films.
- <sup>b</sup>Spleen rate- % of children between 2–10 years showing enlargement of spleen.

**Table 6.6B:** Epidemiological classification of malaria depending on transmission

	Stable malaria	Unstable malaria
Transmission	Uniform, throughout the year	Seasonal transmission
Immunity	Potent resistance in the community due to intense transmission	Lack of community immunity due to low transmission
Age	Children	All age group
Control	Difficult	Easier
Occurrence	West and East Africa, East India	Ethiopia, North west India

## Malaria Situation

The epidemiological classification of malaria depending on endemicity and transmission are depicted in Table 6.6A and 6.6B.

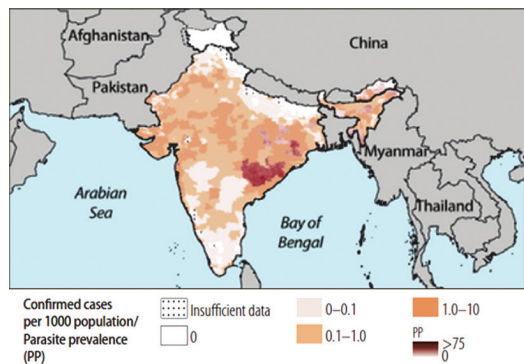
### In India

*P. falciparum* is the most common species in India. Due to wide spread resistance to anti-malarial drugs, the prevalence of *P. falciparum* is increasing every year.

According to the WHO malaria report 2013,

- P. falciparum* is the predominant species (50%) followed by *P. vivax* (nearly 50%). Few cases of mixed infections are also reported
- 22% of people reside in high transmission area ( $\geq 1$  case per 1,000 population), 67% in low transmission area (0–1 case per 1,000 population) and 11% in malaria free area
- Odisha was affected the most (24%) where 92% of cases were due to *P. falciparum* infection
- P. malariae* has a restricted distribution (< 1%) in India. The largest focus of *P. malariae* in India is reported to be in Tumkur and Hassan districts of Karnataka

- P. ovale* is mainly confined to tropical Africa. Only few cases are reported from India (from Odisha, Delhi, Assam, Gujarat and Kolkata)
- The major endemic areas in India are in the north-eastern states, Andhra Pradesh, Chhattisgarh, Gujarat, Jharkhand, Madhya Pradesh, Maharashtra, Rajasthan and Odisha (Fig. 6.3)



**Fig. 6.3:** Epidemiological prevalence of malarial parasite in India

Source: World malaria report 2013, ID# 136584. World Health Organization (WHO) (with permission)



- The government of India has launched many programmes to control malaria in India like:
  - National Malaria Control Programme in April 1953
  - National Malaria Eradication Programme in 1958
  - Modified Plan of Operation (MPO) in 1977
  - National vector born disease control programme in 2005 (which also cover Dengue, Chikungunya, Japanese Encephalitis (JE), Kala-azar and Lymphatic filariasis)
- **Roll back malaria** was launched by WHO and UNICEF in 1998 and reformed in 2000. It has kept a goal to reduce the malaria cases by 50% by the end of 2010 and 75% by the end of 2015
- **World malaria day:** Every year, 25<sup>th</sup> April is being celebrated as “World malaria day”.

#### Laboratory Diagnosis      Malaria parasite

##### Microscopic tests:

- Peripheral blood smear—Gold standard
  - Thick smear—more sensitive
  - Thin smear—speciation can be done
- Fluorescence microscopy (Kawamoto's technique)
- Quantitative buffy coat examination

##### Nonmicroscopic tests:

- Antigen detection tests (RDTs) or ICTs—detects parasitic LDH, HRP-II, aldolase
- Antibody detection—ELISA
- Culture—RPMI 640 medium
- Molecular diagnosis—PCR using PBRK1 primer

## Laboratory Diagnosis

The diagnostic tests for malaria can be divided into microscopic and nonmicroscopic tests.

### Peripheral Blood Smear

Peripheral smear study still remains the simple and gold standard confirmatory test for detection of malarial parasites.

### Specimen

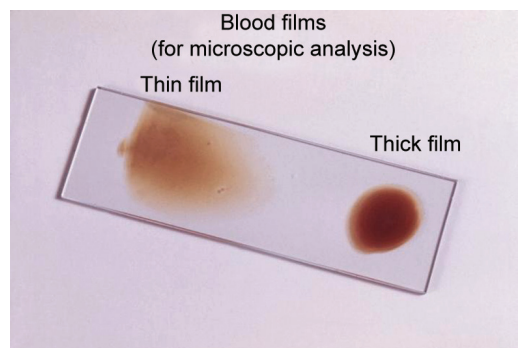
Peripheral blood is collected from ear lobe or by finger prick in older children & adults and from the great toe in infants. Blood films should be prepared directly from the capillary blood. In case of ethylene diamine tetra acetic acid (EDTA) anticoagulated blood, smears should be made within an hour of collection of blood. In pregnant women, cord blood and placental impression smears are used. In postmortem cases, smears from cerebral grey matter can be used

- **Time for taking blood:** Blood should be collected few hours after the height of the paroxysm of fever and before taking antimalarial drugs. Parasite density is maximum during this period
- **Frequency:** Smears should be examined at least twice daily until parasites are detected.

### Types of peripheral blood smear

It is of two types—thin and thick smears. Both the smears are made at the same time from capillary blood either on the same or different slides (Fig. 6.4).

- For thick smear, a big drop of blood is spread over half inch square area on a clean glass slide. The thickness of the film should be such that it allows newsprint to be read. The film is dried and kept in distilled water in a koplins jar for 5–10 minutes for



**Fig. 6.4:** Glass slide showing thin and thick blood smear

dehemoglobinization

- For thin smear, a small drop of blood is taken on a corner of a slide. It is spread by another slide at an angle of 45° and then is lowered to an angle of 30° and is pushed gently to the left, till the blood is exhausted
- The surface of a good thin film is:
  - Even and uniform
  - Consist of a single layer of RBCs
  - The “feathery tail end” is formed near the center of the slide
  - Margins of the film should not extend to the sides of the slide
- They are stained with one of the Romanowsky’s stains such as Leishman’s, Giemsa and Field’s, Wright’s or JSB (Jaswant Singh and Bhattacharya) stain (for staining procedure,see Appendix IV, p-335)
- Thin smear has to be screened first. It is screened near the feathery tail end. At least 200–300 oil immersion fields should be examined before the smears are considered as negative
- Thick smear has to be examined if no parasites are found in thin smear

**Advantages**

- Peripheral smear is simple, rapid and cheap
- Thick smear is useful in:
  - **Detecting the parasites:** It is 40 times more sensitive than thin smear, can detect as low as 5–10 parasites per  $\mu\text{L}$  of blood
  - Quantification of parasitemia
  - Demonstrating the malaria pigments

- Thin smear is useful in speciation of malaria parasite. (Speciation is not possible by thick smear as the RBCs are dehemoglobinized)

**Disadvantages**

- Labor intensive and requires experienced microscopist
- **Low sensitivity:** The detection limit of thin smear is more than 200 parasites per  $\mu\text{L}$  of blood.

**Speciation**

The speciation by thin smear is based on the detection of the asexual forms (ring forms, late trophozoites and schizonts) and gametocytes. However, in falciparum malaria, only the gametocytes and ring forms are demonstrated (but not schizonts and late trophozoites) in peripheral blood (Table 6.5 and Figs 6.2, 6.5, 6.6, 6.7 and 6.8).

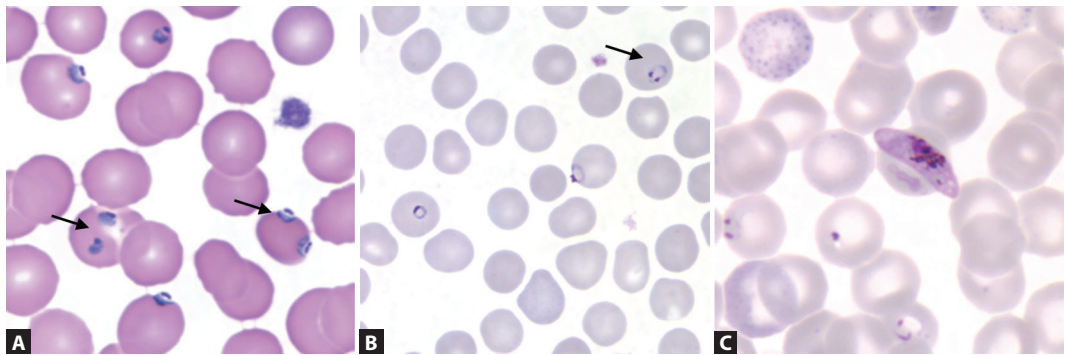
**Quantification of parasites**

Thick smear is preferred to thin smear for quantification of parasitemia

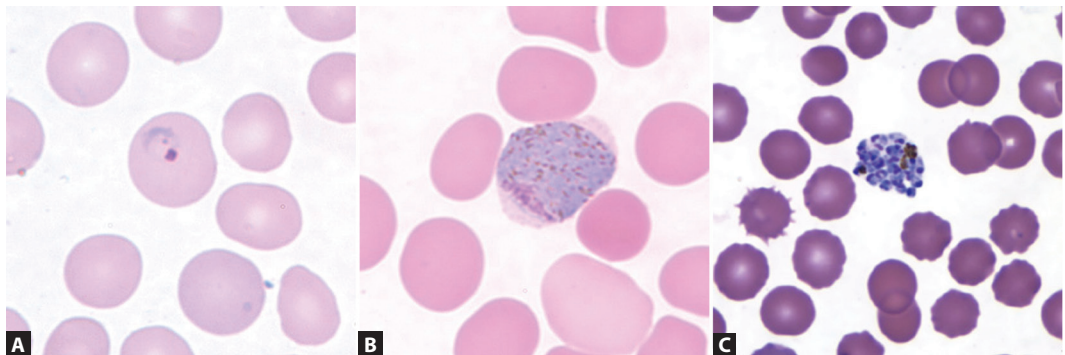
- Previously, the “plus system” was used, which is simple but far less accurate for establishing parasite density in thick blood films. Now it is obsolete
- Currently, the quantification is done by calculating the number of parasites counted compared to number of white blood cells (WBCs) in the thick smear or number of RBCs counted in thin smear (Table 6.7)
- Quantification is helpful for:
  - Assessing the severity of infection

**Table 6.7:** Formula for quantification of malaria parasites by thick smear

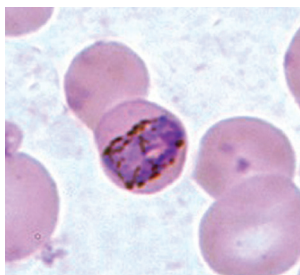
Formula for quantification of malaria parasites by thick smear	
Plus system	+ = 1–10 parasites per 100 oil-immersion thick film fields ++ = 11–100 parasites per 100 oil-immersion thick film fields +++ = 1–10 parasites per single oil-immersion thick film field ++++ = more than 10 parasites per single oil-immersion thick film field
Parasite/ $\mu\text{L}$	
By thick smear	Number of parasites counted per 100 WBCs x Total WBC count (8000)/100
By thin smear	Number of parasites counted per 100 RBCs x Total RBC count /100



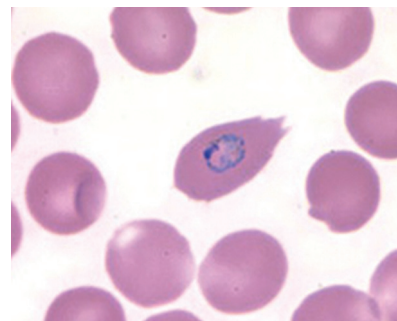
**Figs 6.5A to C:** Thin blood smear showing different forms of *Plasmodium falciparum*  
(A) multiple ring form and accole form; (B) double dot (head phone shaped) ring form; (C) gametocyte  
Source: DPDx Image Library, Centre for Disease Control and prevention (CDC), Atlanta (with permission)



**Figs 6.6A to C:** Thin blood smear showing different forms of *Plasmodium vivax* (A) ring form; (B) gametocyte; (C) schizont  
Source: DPDx Image Library, Centre for Disease Control and prevention (CDC), Atlanta (with permission)



**Fig. 6.7:** Thin blood smear showing ring form of *Plasmodium malariae* (band form)  
Source: DPDx Image Library, Centre for Disease Control and prevention (CDC), Atlanta (with permission)



**Fig. 6.8:** Thin blood smear showing ring form of *Plasmodium ovale*  
Source: DPDx Image Library, Centre for Disease Control and prevention (CDC), Atlanta (with permission)

- Monitoring the response to the treatment.
- Detecting drug resistance of *P. falciparum*

### Fluorescence Microscopy

**Kawamoto technique** is a fluorescent staining method for demonstrating malaria parasites.

Blood smears are prepared on a slide and are stained with acridine-orange and examined under a fluorescence microscope. Nuclear DNA is stained green.

### Quantitative Buffy Coat Examination

The quantitative buffy coat (QBC) malaria test is an advanced microscopic technique for malaria diagnosis. It consists of three basic steps—(1) concentration of blood by centrifugation,

- (2) staining with acridine orange stain and
- (3) examination under ultraviolet (UV) light source (Table 6.8).

### Interpretation

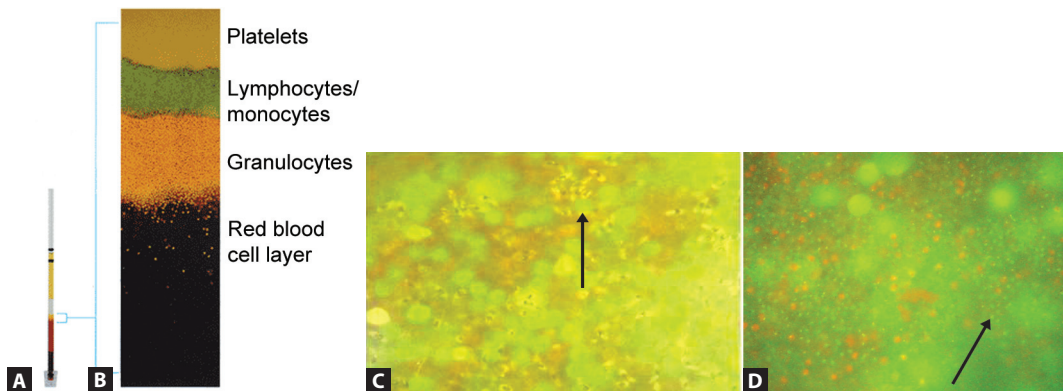
Acridine orange has a property of staining the nuclear DNA fluorescent brilliant green. Normal RBCs don't take up the stain (as they are anucleated). However, parasitized RBCs appear as brilliant green dots. WBCs also take up the stain (Fig. 6.9)

### Advantages

QBC is faster (the entire tube can be screened within minutes), more sensitive (at least as good as a thick film), uses more blood (60  $\mu$ L) than thick smear and quantification is possible (Table 6.8)

**Table 6.8:** Procedure of quantitative buffy coat

- The commercially available quantitative buffy coat (QBC) capillary tube is precoated internally with acridine orange stain
- 60  $\mu$ L of peripheral blood is collected from one end of the tube, which is then closed by a plastic closure. (Fig. 6.9)
- A cylindrical float is inserted to the other end of the QBC tube. The tube is centrifuged at 12,000 rpm for 5 minutes
- The components of the blood are separated according to their densities, forming discrete bands
- Because the cylindrical float occupies 90% of the interior lumen of the tube, it forces all the surrounding blood cells into 40  $\mu$  space between its outside circumference and inside of the tube
- Following centrifugation, the buffy coat region of the QBC tube, i.e. at the RBC/WBC interface is examined under UV light source
- The whole 60  $\mu$ L blood sample can be visualized by rotating the QBC tube under the fluorescent microscope.



**Figs 6.9A to D:** (A) QBC capillary tube; (B) magnified view of QBC capillary tube after centrifugation; (C) crescent shaped gametocyte of *Plasmodium falciparum*; (D) ring forms of *Plasmodium falciparum* seen as fluorescent dots

**Disadvantages**

It is expensive, less specific and speciation is difficult.

**Antigen Detection by Rapid Diagnostic Tests**

Several malarial antigens can be detected like:

- **Parasite lactate dehydrogenase (pLDH):** It is produced by trophozoites and gametocytes of all *Plasmodium* species. Currently available test kits can differentiate pan malarial pLDH common to all species and pLDH specific to *P. falciparum*
- **Parasite aldolase:** Produced by all *Plasmodium* species
- ***Plasmodium falciparum* specific histidine rich protein-2 (Pf-HRP-II):** It is produced by trophozoites and young (but not mature) gametocytes of *P. falciparum*
- Most of the kits are designed to detect a combination of two antigens, one is *P. falciparum* specific antigen (i.e. HRP2 or pLDH specific for *P. falciparum*) and other is a pan malarial antigen (like aldolase or pan malarial pLDH)

- The principle and procedure of the rapid diagnostic tests (RDTs) are described in Table 6.9 and Fig. 6.10.

**Advantages of rapid diagnostic tests**

- Rapid diagnostic tests are simple to perform, don't need extra equipment or trained microscopist (Table 6.9)
- **Sensitivity:** Rapid diagnostic tests are more than 90% sensitive at >100 parasites/ $\mu$ L. But the sensitivity is markedly reduced at <100 parasites/ $\mu$ L
- pLDH is produced by the viable parasites, hence it is used to monitor the response for treatment (microscopy is the best to assess prognosis). However, HRP2 remains positive even after treatment
- HRP2 is a reliable marker to diagnose malaria in pregnancy
- Intensity of the band is directly proportional to the parasitemia and severity of the disease.

**Disadvantages of rapid diagnostic tests**

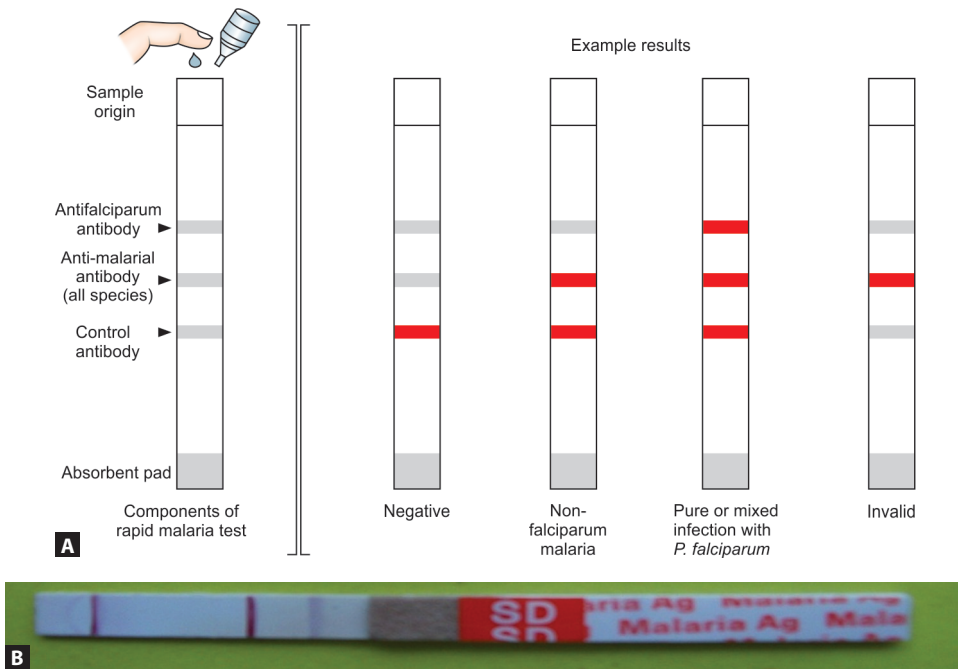
Rapid diagnostic test kits are expensive

- Cannot differentiate between the non *falciparum* malaria species

**Table 6.9:** Principle and procedure of rapid diagnostic tests

- Rapid diagnostic tests (RDTs) are based on lateral flow assay [also called as Immunochromatographic test (ICT)]
- Test kits currently available use a nitro-cellulose membrane containing a sample pad, an absorbent pad and three detection lines coated with:
  - Test line-1: Coated with capture antibodies specific for *Plasmodium falciparum*
  - Test line-2: Coated with capture antibodies common to all *Plasmodium* spp.
  - Control line: Coated with antibody raised in rabbit sera against polyclonal malarial antibody
- **Sample:** 5–50  $\mu$ L of peripheral blood (anticoagulated), serum or plasma is collected according to the manufacturer's instructions
- Blood is mixed with a buffer solution provided by the kit. The buffer solution contains a hemolysing compound that lyses the RBCs to release the malaria antigens
- Buffer solution also contains a polyclonal malarial antibody labelled with colloidal gold (visually detectable marker) which forms antigen antibody complexes with malarial antigen
- Both labelled antigen antibody complexes and unbound polyclonal malarial antibody migrate through the nitro-cellulose membrane by capillary action
- **In positive cases:** The labelled antigen antibody complexes will be immobilized at the corresponding pre deposited lines coated with capture antibody specific for *P. falciparum*, pan malarial capture antibody
- **In both positive and negative cases:** The control band is formed due to binding of the labelled polyclonal malarial antibody to the control antibody. Absence of control band indicates the test is invalid (Fig. 6.10)





**Figs 6.10A and B:** (A) Schematic diagram of rapid diagnostic test kit showing negative, non *falciparum*, pure or mixed infection with *Plasmodium falciparum* and invalid result of malaria; (B) real images of rapid diagnostic test kit

- Gametocytes cannot be detected
- False positive bands appear in rheumatoid arthritis factor positive cases
- The lower limit to detect HRP2 is 40 parasites/ $\mu$ L and pLDH is 100 parasites/ $\mu$ L.

### Antibody Detection

ELISA (enzyme-linked immunosorbent assay), IFA (indirect fluorescent antibody test) and IHA (indirect hemagglutination test) formats are available using soluble malarial antigens. Detection of antibody in serum indicates past malaria infection and is useful for:

- Epidemiological survey in malaria
- Screening of blood bank to identify the infected donors.

### Culture

Culture techniques for malaria are mainly used for preparation of malaria antigens. However, they are not used for diagnosis.

- **Trager and Jensen (1976)** discovered a simple method for continuous culture of *P. falciparum*, which has been extended for the cultivation of other species of malaria
- He used **RPMI 1640** medium (Roswell Park Memorial Institute and 1640 denotes the number of passages) in a continuous flow system mixed with a thin layer of RBC and an overlay medium consists of human serum maintained with 7%  $\text{CO}_2$  and 1–5%  $\text{O}_2$
- All current culture techniques are the modifications of the Trager and Jensen method
- RPMI 1640 medium is the most commonly used and found superior to other media for cultivation of *P. falciparum*
- The other media used are Delbecco's modified Eagle medium (MEM), RPMI 1630, and Medium 199.

### Molecular Diagnosis

- **DNA probe:** Highly sensitive, detects even

**Table 6.10:** Comparison of peripheral smear, quantitative buffy coat and rapid diagnostic tests

Features	Peripheral smear	Quantitative buffy coat	Rapid diagnostic tests
Method	Cumbersome	Easy	Easy
Time	Longer, 60–120 minutes	Faster, 15–30 minutes	Faster, 15–30 minutes
Sensitivity	Detection limit- • 5 parasites/ $\mu$ L in thick film • 200 parasite/ $\mu$ L in thin film	Claimed to be more sensitive, at least as good as a thick film	• > 100 parasites/ $\mu$ L, sensitivity > 90% • < 100 parasites/ $\mu$ L, sensitivity falls
Specificity	Gold standard	False positives—artifacts may be reported as positive by nontrained technicians	False positive in RA factor (rheumatoid arthritis) positive cases
Speciation	Accurate, gold standard	Difficult	Detect <i>Plasmodium falciparum</i> but cannot differentiate non <i>falciparum</i> species
Cost	Inexpensive	Costly equipments and consumables	Kits are costly but no extra equipment required. Good for field study
Experienced Microscopist	Required	Not required, minimal training is sufficient	Not required, minimal training is sufficient

if the parasite count is low less than 10/ $\mu$ L

• **PCR:**

- It can detect a single *P. falciparum* in 20  $\mu$ L of blood using PBRK1 primer
- It is 100 times more sensitive than that of thick blood smear
- Speciation can be done
- Drug resistance genes can be detected
- Useful tool for epidemiological study.

**Other Nonspecific Tests**

These include:

- Normochromic and normocytic hemolytic anemia
- **Leucopenia:** Due to decrease in granulocytes and lymphocytes
- Raised erythrocyte sedimentation rate (ESR)
- Raised serum C-reactive protein
- Prolonged prothrombin and partial thromboplastin time in severe infection
- Decreased antithrombin III levels in mild infection
- Metabolic acidosis
- **Hypoglycemia:** Lower blood glucose levels are associated with higher mortality

- Severe falciparum malaria is also associated with low plasma concentrations of sodium, calcium, magnesium and albumin; and high levels of lactate, creatinine, muscle and liver enzymes, and conjugated & unconjugated bilirubin

- Hypergammaglobulinemia.

Comparison of peripheral smear, quantitative buffy coat and rapid diagnostic tests are described in Table 6.10.

**Treatment**

Various antimalarial drugs are depicted in Table 6.11.

**Uncomplicated Benign Malaria in India**

Chloroquine is still the drug of choice for uncomplicated benign malaria in India. It is given 25 mg/kg divided over 3 days.

Relapse rate of vivax malaria is around 30% in India. Primaquine is given as 0.25 mg/kg daily for 14 days to prevent relapse.

**Complicated or Falciparum Malaria in India**

Treatment of falciparum malaria in India is based on area resistant or sensitive to chloroquine.



**Table 6.11:** Antimalarial drugs and their activity

Class	Drugs	Active against parasitic stages
Quinolines and related compounds	Chloroquine	Asexual RBC stages Gametocytes (except <i>Plasmodium falciparum</i> )
	Quinine	
	Mefloquine	Asexual RBC stages
	Primaquine	Liver stages and hypnozoites, gametocytes
Artemisinin and its derivatives	Artemisinin, artemether and arte-ether	Asexual RBC stages and gametocytes
Hydroxynaphthoquinones	Atovaquone	Asexual RBC stages, Liver stages (only for <i>P. falciparum</i> )
Biguanide derivative	Proguanil	
Diaminopyrimidines	Pyrimethamine	Asexual RBC stages, Liver stages (+/-)
Sulfonamides	Sulfadiazine and sulfadoxine	
Tetracyclines	Tetracycline and doxycycline	Asexual RBC stages (+/-)

Abbreviations: (+/-) indicates doubtful activity; RBC, red blood cell

- Artemisinin combination therapy (ACT) is recommended in chloroquine resistant areas where as chloroquine can be given in sensitive areas
- ACT consists of a combination of artemisinin derivative (Artemisinin or artemether or arte-ether) and a long acting antimalarial drugs like sulfadoxine-pyrimethamine, mefloquine or lumefantrine
- For treatment of the failure of *P. falciparum* cases quinine with combination of doxycycline or tetracycline is recommended
- Chloroquine resistant areas where ACT is recommended—Odisha, Jharkhand, Madhya Pradesh, Chhattisgarh and Andhra Pradesh
- In pregnancy—quinine is recommended in first trimester whereas ACT is given in second and third trimester
- Treatment of unconfirmed cases or mixed infection with *P. falciparum* should be treated as falciparum malaria plus primaquine is given for radical cure.

### Antimalarial Drug Resistance

Antimalarial drug resistance has emerged as one of the greatest challenges facing malaria control today.

### *Falciparum malaria*

Drug resistance in *P. falciparum* is widespread and is described against all the available drugs, however, there are geographical variations.

- **Chloroquine resistant** has been described in all its endemic areas except for limited areas of Central America, Hispaniola and Middle East and Central Asia
- **Sulfadoxine-pyrimethamine resistance** occurs frequently in Africa, South-East Asia and South America
- **Mefloquine resistance** is frequent in some areas of South-East Asia, the Amazon region of South America and sporadically in Africa
- In India, resistance to chloroquine is described from various states; however, resistance to other drugs is not reported yet.

### *Vivax malaria*

Only sporadic cases of resistance to chloroquine and/or primaquine in some areas have been reported.

### *The important factors that contribute to emergence of resistance are*

- Longer half-life of drug
- Mutation of the parasite for resistance: Chloroquine resistance is mediated by multidrug resistance gene or transport gene

or efflux pump mechanisms

- Inadequate and irregular usage of drug
- Poor compliance
- Host immunity.

The development of resistance can be *delayed by combination of drugs*, i.e. combining one drug that rapidly reduces parasite biomass with a partner drug that can remove any residual parasites, e.g., ACT.

### **Mechanism of drug resistance**

**Chloroquine resistance in *Plasmodium falciparum*:** Occurs due to mutations in the genes encoding the transporter proteins such as PfCRT (*P. falciparum* chloroquine transporter) and PfMDR1 (*P. falciparum* multidrug resistance gene 1). These proteins help in chloroquine influx into the parasitic food vacuoles. Such mutation results in impaired transport of chloroquine.

More so, mutation in PfMDR1 gene leads to resistance to other antimalarials like amodiaquine, mefloquine and halofantrine.

**Resistance to antifolates** such as sulfadoxine, pyrimethamine and proguanil is due to point mutation in DHFR (dihydrofolate reductase) gene.

### **WHO Guideline for Assessing Degree of Resistance**

**Antimalarial drug resistance** is defined as the “ability of a parasite strain to survive and/or to multiply despite of the administration and absorption of a drug given in doses equal to or higher than those usually recommended but within tolerance of the subject”.

**In vivo method (2002)** degree of resistance is divided into four categories:

1. **Early treatment failure (ETF):** Development of danger sign or severe malaria (fever > 37.5°C) on day 0–3 and parasitemia on day 3 is 25% higher than day 0 count
2. **Late clinical failure (LCF):** Development of danger sign or severe malaria (fever > 37.5°C) in the presence of parasitemia from

day 4 to day 14 without previous meeting of any criteria of ETF

3. **Late parasitological failure (LPF):** Presence of parasitemia on any day from 7 days to 14 days or 28 days and fever less than 37.5°C without previous meeting of any criteria of early and late treatment failure
4. **Adequate clinical and parasitological response (ACR):** Absence of parasitemia on day 14 or 28 irrespective of fever, without previous meeting of any criteria of early and late treatment failure

**In vitro tests** various methods are also available for antimalarial drug susceptibility testing such as:

- The WHO *in vitro* micro test using RPMI 1640 medium
- ELISA for measurement of HRP2/or pLDH
- Polymerase chain reaction to detect the *P. falciparum* specific drug resistance genes—available for only a few drugs (chloroquine, pyrimethamine, cycloguanil, sulfadoxine and atovaquone).

### **Prophylaxis Against Malaria**

Prophylaxis against malaria includes chemoprophylaxis, vector control strategies and vaccine prophylaxis.

### **Chemoprophylaxis**

Chemoprophylaxis is recommended for travelers going to endemic areas and as a short-term measure for soldiers or police serving in highly endemic areas.

Drugs that are used for chemoprophylaxis of malaria include:

- **Weekly regimen:** Chloroquine 300 mg or proguanil 400 mg, or mefloquine 250 mg
- **Daily regimen:** Doxycycline 100 mg
- Chloroquine and mefloquine weekly regimens should be started 1 week and 2 weeks before the travel respectively and doxycycline daily regimen should be started 1 day before the travel.

### Vector Control Strategies

Vector control is still one of the prime weapons to control malaria in endemic areas.

#### Antiadult measures

- **Residual spraying:** Spraying the houses with residual insecticides such as dichlorodiphenyl trichloroethane (DDT), malathion and fenitrothion is highly effective against adult mosquito
- **Space application** of pesticide in the form of fog or mist by ultra-low volume method of pesticide dispersion
- **Individual protection:** Done by reduction of human-mosquito contact by using insecticide treated bed nets, repellents and protective clothing.

#### Antilarval measures

- **Larvicide:** Use of mineral oil or Paris green has been extensively used to kill mosquito larvae and pupae

- **Source reduction** (to reduce the mosquito breeding site): Includes environmental sanitation, water management and improvement of the drainage system.
- **Biological larvicide:** *Gambusia affinis* (fish) and *Bacillus thuringiensis* (bacteria) can be used to kill the mosquito larva.

### Vaccination for Malaria

Several vaccine trails are done in Africa, Asia and the United States. Despite of intense research, till date, there is no vaccine licensed for human use. The approaches are made targeting the various stages of malaria cycle (Table 6.12). The main problems in malaria vaccine include:

- The vaccine candidates are poor inducer of cell mediated immune response
- Antigenic variation in malarial antigens such as *PfEMP*
- Different immune mechanisms occur in different stages of malaria life cycle.

**Table 6.12:** Vaccine strategies against malaria

<b>Pre-erythrocytic (sporozoites) vaccine</b>
<ul style="list-style-type: none"> <li>• Aims to prevent the entry of the parasite to liver thus preventing the establishment of infection</li> <li>• Useful for people of hypoendemic area</li> </ul>
<ul style="list-style-type: none"> <li>• Trials are going on using vaccine candidates such as:                             <ul style="list-style-type: none"> <li>– <i>PfCSP</i> (circumsporozoite protein repeats) of <i>Plasmodium falciparum</i></li> <li>– LSA: Liver specific antigen 1, 2, 3</li> <li>– SALSA: Sporozoite and liver stage antigen</li> <li>– SSP2: Sporozoite surface protein-2</li> <li>– STARP: Sporozoite threonine and asparagine protein</li> <li>– Duffy: Binding protein of <i>P. vivax</i></li> </ul> </li> </ul>
<ul style="list-style-type: none"> <li>• RTS,S/AS01:                             <ul style="list-style-type: none"> <li>– This is a recent malaria trial started in 2005 in Africa, expected to be finished by 2014-15.</li> <li>– Vaccine candidate consists of the repeat and T-cell epitope in the <i>PfCSP</i> (circumsporozoite protein of <i>Plasmodium falciparum</i>), hepatitis B surface antigen (HBsAg) and a chemical adjuvant (AS01) to boost the immune system response</li> <li>– Infection is prevented by inducing high antibody titers that block the parasite from infecting the liver</li> <li>– It had previously been demonstrated to be safe, well tolerated, immunogenic, and to potentially confer partial efficacy in both malaria-naïve and experienced adults as well as children, further research was considered necessary to improve the effectiveness of the vaccine.</li> <li>– In November 2012, findings from a Phase III trial of RTS,S reported that it provided modest protection against both clinical and severe malaria in young infants.</li> <li>– In October 2013, GlaxoSmithKline (GSK) reported that the RTS,S vaccine reduced the amount of cases amongst young children by almost 50 % and among infants by 25%. GlaxoSmithKline is set to submit an application for a marketing license with the European Medicines Agency (EMA) in 2014.</li> </ul> </li> </ul>

Contd...

Contd...

**Blood stage vaccine/erythrocytic vaccine**

- These vaccines help in preventing the disease thus, are useful for people of hyperendemic areas of malaria.
- Prevention of infection is not required for endemic areas as it is unavoidable and all infected people don't develop disease
- Several trials are there using vaccine candidates such as –
  - Pf EMP (*P. falciparum* erythrocytic membrane protein antigen) vaccine
  - Hsp70: Heat shock protein
  - SERA: Serine rich antigen
  - RESA: Ring infected erythrocyte surface antigen
  - ABRA: Acidic basic repeat antigen
  - HRP2: Histidine rich protein-2
  - Aldolase
  - Merozoite surface protein (MSP 1,2,3)
- SPF 66:
  - This was one of the most intense trials done for malaria vaccine in Columbia in 1976.
  - A cocktail of four antigens (three asexual blood stage antigens and PfCSP) were used.
  - It was only found to be 30% protective among children

**Transmission blocking/anti gametocyte vaccine**

- Aims at inducing antigametocyte antibodies in blood that can be passed to the mosquito while they feed, react with the gametocytic & other sexual stage antigens and interfere with fertilization, thus block the transmission of infection. They don't have a direct effect to the individuals.
- Vaccine candidates used are— Pfs230 and Pfs45/48

**BABESIA**

Babesia is an intraerythrocytic protozoa of animals, causes tick born malaria like illness in cattle and sheep. It rarely affects humans causing opportunistic infection

- *Babesia* is named after a Romanian Scientist, Sir V. Babes who described the causative parasite inside the RBC of cattle and sheep in 1888.
- Later on, Kilbourne (1893, USA) had demonstrated the parasite to cause Texas cattle fever, a tick borne hemolytic disease of cattle
- The first human case was reported in 1957 in a farmer in Yugoslavia
- *Babesia* species are grouped into:
  - Small *Babesia* species (1–2.5  $\mu\text{m}$ ): *B. microti*, *B. gibsoni* and *B. rodhaini*
  - Large *Babesia* species (2.5–5  $\mu\text{m}$ ): *B. divergens* and *B. bovis*.

**Life Cycle**

**Host:** The nymph stage of the deer tick *Ixodes scapularis* is the primary vector (definitive host) of the parasite. Occasionally it is trans-

mitted by blood transfusion. Humans act as intermediate host.

**Mode of transmission:** Man acquires infection by the bite of ticks where the sporozoites enter through the site of bite and are discharged into circulation.

**Asexual Cycle in Man**

Sporozoites enter into RBCs where they transform into trophozoites and then multiply asexually by budding giving rise to two or four daughters pear shaped trophozoites (ring forms in tetrad called as **Maltese cross form**) arranged inside RBCs.

- They feed on hemoglobin but pigments are not produced
- Some of the asexual forms transform into gametocytes.

**Sexual Cycle in Tick**

Following the blood meal, the gametocytes reach the intestine where they multiply sexually and later migrate to salivary gland where they transform into sporozoites.

## Pathogenesis and Clinical Features

The incubation period varies from 1 to 6 weeks.

- Transmission occurs in warm months (May to September)
- **Mild *Babesia microti* illness:** It is characterized by malaise, fatigue, and weakness and fever. Later on the patient develops chills, sweats, headache, myalgia, anorexia, dry cough, arthralgia and nausea
- **Severe *Babesia microti* illness:**
  - Seen when parasitemia exceeds more than 4%
  - Predisposing factors include more than 50 years of age, male, splenectomy, HIV/AIDS, malignancy, and immunosuppression
  - Patient presents as severe anemia (hemoglobin level < 10 g/dL)
  - Complications may occur like acute respiratory distress syndrome, disseminated intravascular coagulation, congestive heart failure, renal failure and splenic infarcts and rupture
- **Infections by *Babesia divergens*, *Babesia bovis* and *Babesia duncani*:** Usually seen in splenectomized and immunocompromised patients. Infection is more severe and fulminant.

## Epidemiology

- Babesiosis is highly endemic in the North Eastern United States like Nantucket Island and also in South Eastern Massachusetts
- It is an emerging infectious disease in other countries. Sporadic cases are reported in Europe and other places
- In India, Babesiosis is not reported yet.

### Laboratory Diagnosis

#### Babesia

- Peripheral blood microscopy—Detects maltese cross form (ring form in tetrad)
- Serology—IFA
- Molecular methods—PCR
- Animal inoculation

## Laboratory Diagnosis

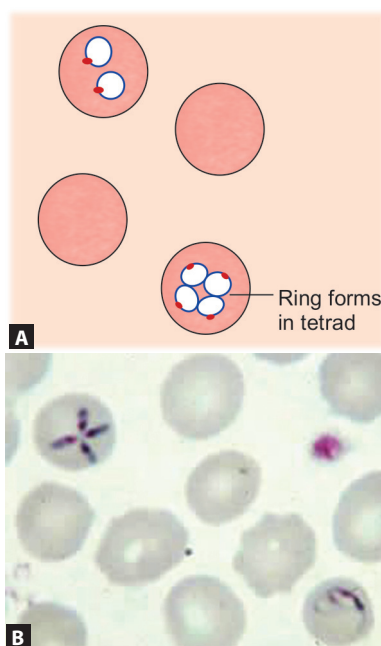
### Peripheral Blood Microscopy

Diagnostic feature is the demonstration of two or four rings inside the RBCs (called as maltese cross forms) in the Giemsa stained thick and thin blood smear (Fig. 6.11).

It is often confused with the multiple ring forms of *P. falciparum*. But can be differentiated by lack of pigments, lack of crescentic gametocytes, and the presence of pear shaped rings (Table 6.13).

### Serology

Indirect fluorescent antibody (IFA) test for *B. microti* is available. IgM titers of 1:64 or more and IgG titers of 1:1024 or more signify active or recent infection. Titers typically decline over 6–12 months. Titers of less than 1:64 suggest complete clearance. Titers that remain



**Figs 6.11A and B:** Giemsa stain blood smear showing maltese cross form (A) schematic diagram; (B) slide (real image)

Source: B- DPDx Image Library, Centre for Disease Control and prevention (CDC), Atlanta (with permission)

**Table 6.13:** Differences between *Babesia* and falciparum malaria

Feature	<i>Babesia</i>	<i>Falciparum malaria</i>
Vector	Tick	Female <i>Anopheles</i> mosquito
Ring forms	Pear shaped and in tetrad (maltese cross form)	Round and may be single or multiple
Gametocyte	Cannot be distinguished from asexual forms	Crescentic gametocyte
Pigments in RBC	Not seen	Seen
Asexual cycle	By budding Schizogony -asynchronous	Binary fission Schizogony—synchronous
Hemolysis	Less severe	More severe
Cerebral features	Not seen	Seen
Parasitaemia	Usually low	Usually high
Risk factor	Immunosuppression	Also seen in immunocompetent individuals
Treatment	Chloroquine not affective Clindamycin plus oral quinine is given	Chloroquine is given in milder and sensitive cases

positive (1:64) suggest persistent low-level parasitemia. Antibodies to *B. microti* do not react with other *Babesia* species.

### Molecular Methods

PCR can be done targeting amplification of 18S rRNA gene. It is useful when microscopy fails (low parasitemia).

### Animal Inoculation

Blood of the patients can be inoculated intra-peritoneally into golden hamsters. After 2–4 weeks, the hamster's blood smear examination is done weekly at least for 6 weeks to demonstrate the parasite. Though cumbersome, it is more sensitive and specific.

Treatment	<i>Babesia</i>
	<ul style="list-style-type: none"> <li>For mild <i>Babesia microti</i> illness: The recommended regimen is oral atovaquone plus azithromycin for 7–10 days</li> <li>For severe <i>Babesia microti</i> illness: Intravascular (IV) clindamycin plus oral quinine should be given for 7–10 days and blood transfusion to be considered if required</li> <li>Other <i>Babesia</i> infection like <i>Babesia divergens</i> and <i>Babesia duncani</i>: Immediate complete RBC exchange transfusion is recommended followed by IV clindamycin plus oral quinine for 7–10 days.</li> </ul>

## EXPECTED QUESTIONS

### I. Write essay on:

- Describe the life cycle, pathogenesis, complications and laboratory diagnosis of *Plasmodium falciparum*?
- Describe the life cycle, clinical feature and laboratory diagnosis of *Plasmodium vivax*?

### II. Write short notes on:

- Cerebral malaria
- Plasmodium ovale*

(c) *Plasmodium malariae*

(d) Pernicious malaria

(e) Prophylaxis of malaria

(f) Black water fever

(g) Babesiosis

(h) Vaccine approaches against malaria

(i) Drug resistance in malaria

### III. Differentiate between:

- Morphological forms of *Plasmodium vivax* and *Plasmodium falciparum*



(b) *Falciparum* malaria and babesiosis

**IV. Multiple choice questions (MCQs):**

**1. Which is the infective form of the malaria parasite to man?**

- (a) Merozoite (b) Sporozoite
- (c) Trophozoite (d) Gametocyte

**2. Which is the infective form of the malaria parasite to mosquito?**

- (a) Merozoite (b) Sporozoite
- (c) Trophozoite (d) Gametocyte

**3. Which stage of the malaria parasite causes relapse?**

- (a) Sporozoite
- (b) Trophozoite
- (c) Merozoite
- (d) Hypnozoites

**4. For infection of mosquito, the blood of human carrier must contain atleast:**

- (a) 12 gametocytes/ $\mu$ L
- (b) 10 gametocytes/ $\mu$ L
- (c) 16 gametocytes/ $\mu$ L
- (d) 18 gametocytes/ $\mu$ L

**5. Which is true about *Plasmodium falciparum*?**

- (a) High level of parasitemia
- (b) It invades erythrocytes of all ages
- (c) Its erythrocytic schizogony takes place in the capillaries of internal organs
- (d) All of the above

**6. Crescent-shaped or banana-shaped gametocytes are seen in infection with:**

- (a) *Plasmodium vivax*
- (b) *Plasmodium falciparum*
- (c) *Plasmodium ovale*
- (d) *Plasmodium malariae*

**7. Maurer's dots in red blood cells are seen in infection with:**

- (a) *Plasmodium vivax*
- (b) *Plasmodium falciparum*
- (c) *Plasmodium malariae*
- (d) *Plasmodium ovale*

**8. Appearance of fever paroxysm every 72 hours (Quartan periodicity of malaria) is seen in infection with:**

- (a) *Plasmodium vivax*
- (b) *Plasmodium falciparum*
- (c) *Plasmodium malariae*
- (d) *Plasmodium ovale*

**9. Babesiosis is transmitted by bite of:**

- (a) *Anopheles*
- (b) Sandfly
- (c) Mite
- (d) Tick

**10. Maltese cross form is seen in?**

- (a) Babesiosis
- (b) *Plasmodium ovale*
- (c) *Plasmodium malariae*
- (d) *Toxoplasma*

**Answers**

1. b    2. d    3. d    4. a    5. d    6. b    7. b    8. c    9. d    10. a



# 7 Sporozoa—II (Opportunistic Coccidian Parasites)

## Chapter Outline

- Introduction
- *Toxoplasma gondii*
- *Cryptosporidium parvum*
- *Cyclospora cayetanensis*
- *Isospora belli*
- *Sarcocystis* species
- Expected questions

## ■ INTRODUCTION

- Coccidian parasites can be divided into three orders—(1) Eimeriida, (2) Haemosporida and (3) Piroplasmida. The latter two are described in Chapter 6
- **Order Eimeriida contains five genera:** *Toxoplasma*, *Cryptosporidium*, *Cyclospora*, *Isospora* and *Sarcocystis* (Chapter 6, Table 6.1)
- *Toxoplasma* is an intracellular parasite that can cause congenital infections and also opportunistic infections (encephalitis) in HIV (human immunodeficiency virus) infected patients
- *Cryptosporidium*, *Cyclospora* and *Isospora* are acid fast parasites that can cause opportunistic infections (diarrhea) in HIV infected patients
- *Sarcocystis* is a rare parasite infecting man and forms cystic lesions in muscles.

## ■ TOXOPLASMA GONDII

*Toxoplasma gondii* is an obligate intracellular parasite affecting a wide range of mammals and birds including humans.

- Though human infection is very common affecting nearly one-third of world's population; clinical manifestations are relatively rare, mostly restricting to opportunistic infections in immunocompromised persons and congenital infection in fetus
- Charles Nicolle and Louis Manceaux (1908) were the first to discover *T. gondii* in Tunisia from a North African rodent called as *Ctenodactylus gundi*
- The name *Toxoplasma* is derived from a Greek word "*Toxon*" meaning arc or bow referring to the curved shape of the trophozoites (tachyzoites).

## Morphology

It exists in three morphological forms—two asexual forms (tachyzoite and tissue cyst) and a sexual form (oocyst).

### Tachyzoite

It is an actively multiplying form (trophozoite), usually seen in acute infection.

- **Crescent shaped**, having a pointed anterior end and a blunt posterior end
- It measures approximately 6  $\mu\text{m}$  in length and 2  $\mu\text{m}$  in breadth; contains several **dense granules** and a round nucleus situated between center and posterior end
- They can infect all mammalian (nucleated) cells except red blood cells (RBCs)
- At the anterior end, the tachyzoites contain special organelles like rhoptries, and micronemes which are crucial for the adhesion and invasion into the host cell (Fig. 7.1A)
- Inside the host cell, tachyzoites are surrounded by a parasitophorous vacuole within which they divide asexually by a process called as **internal budding** or **endodyogeny** by which daughter trophozoites are formed within the parent cell. They often form **rosettes** surrounding the host nucleus
- Host cell becomes distended by the proliferating tachyzoites and appears as **pseudocyst**. (Fig. 7.1B). Later on, the host cell ruptures releasing the tachyzoites that infects other adjoining cells.

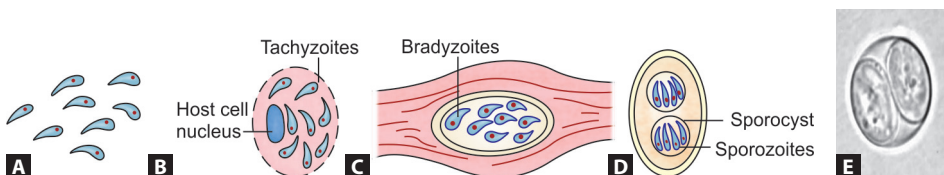
### Tissue Cyst

It is the resting stage of the parasite, usually seen in chronic infections.

- The parasite multiplies within the host cells and produces a round to oval cyst containing many crescent shaped slowly multiplying trophozoites called as **bradyzoites**, surrounded by a cyst wall
- Tissue cysts vary in size (Fig. 7.1C):
  - Younger ones that measure 2–5  $\mu\text{m}$  in size and contain few bradyzoites
  - Older tissue cysts may reach more than 100  $\mu\text{m}$  size and contain several thousand bradyzoites
- **Bradyzoites:**
  - Measure 7  $\mu\text{m}$  in length and 1.5  $\mu\text{m}$  in breadth
  - More slender, crescent shaped with a nucleus situated posteriorly
  - Contains several strongly periodic acid Schiff stain (PAS) positive amylopectin granules
  - Multiply slowly
  - Seen in chronic infection
  - More resistant to gastric juice
- The cyst wall of the tissue cyst is eosinophilic and weakly PAS positive
- Conversion of the tachyzoites to bradyzoites can be triggered by many factors like interferon- $\gamma$  (IFN- $\gamma$ ), nitric oxide (NO), heat shock proteins, pH, and temperature changes
- Most common site of the tissue cysts—muscles and brain (can be found in any organs)
- They appear spherical in the brain and oval inside the muscle tissue.

### Oocyst

Oocyst is the sexual form of the parasite found in cats and other felines.



**Figs 7.1A to E** *Toxoplasma gondii* (schematic diagram); (A) tachyzoites; (B) pseudocyst; (C) tissue cyst; (D) sporulated oocyst; (E) sporulated oocyst in cat's feces (saline mount)

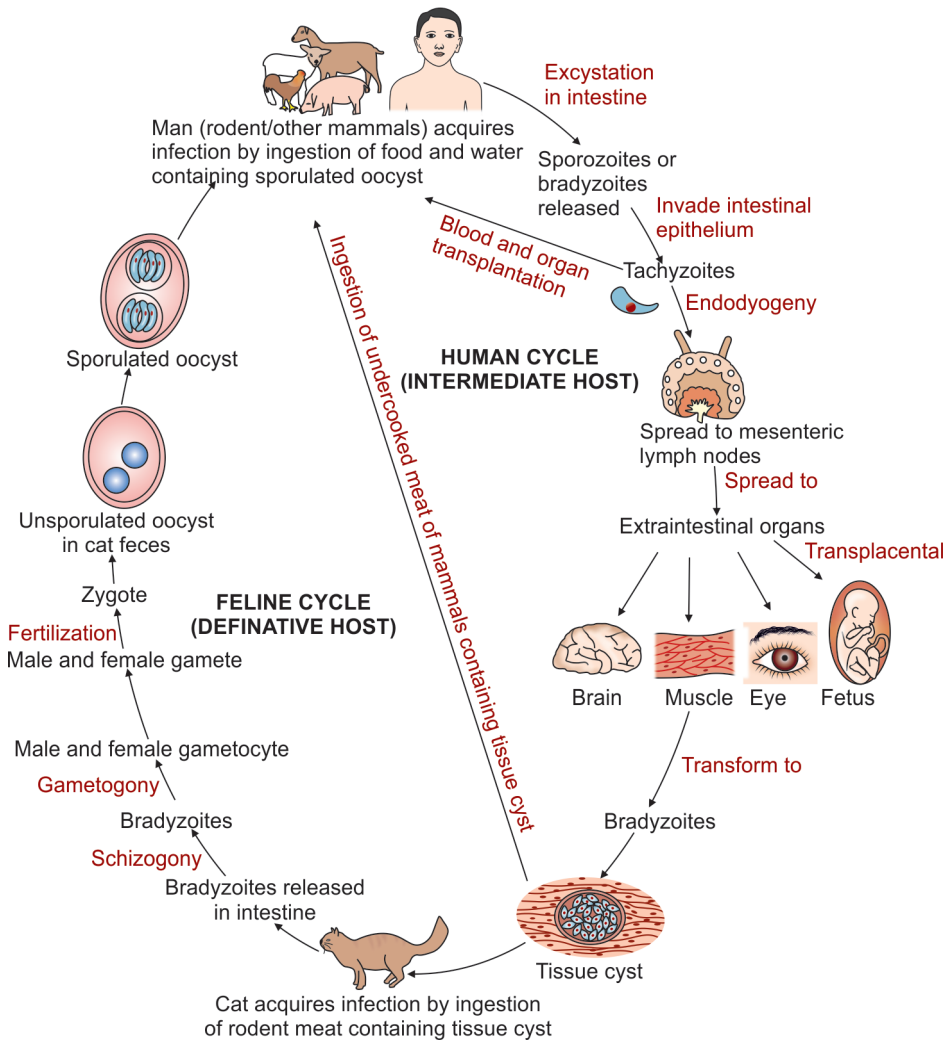
Source: E- DPDx Image Library, Centre for Disease Control and prevention (CDC), Atlanta (with permission)

- It measures 10–12  $\mu\text{m}$  in size, surrounded by a refractile and resistant double layered colorless cyst wall (Fig. 7.1D)
- Unsporulated oocyst excreted in cat's feces is noninfectious (Fig. 7.1E). In the environment, they transform into sporulating oocyst that contains two sporocysts ( $8\ \mu\text{m} \times 6\ \mu\text{m}$ ) each containing four elongated sporozoites ( $6\text{--}8\ \mu\text{m} \times 1\text{--}2\ \mu\text{m}$ ).

### Life Cycle (Fig. 7.2)

**Host:** The life cycle involves two hosts:

1. **Definitive hosts** are cat and other felines; where the sexual cycle takes place
2. **Intermediate hosts** are man and other mammals (goat, sheep, pig, cattle and certain birds); where the asexual cycle takes place.



**Fig. 7.2:** Life cycle of *Toxoplasma gondii*

### Asexual Cycle or Exoenteric Cycle (The Human Cycle)

**Transmission and infective form:** *T. gondii* is unique among the protozoa as all the three morphological forms can transmit the infection. Transmission to man occurs by:

- Ingestion of sporulated oocysts (infective form) from contaminated soil, food, or water (most common route)
- Ingestion of tissue cyst containing bradyzoites (infective form) from undercooked meat
- By blood transfusion, needle stick injuries, organ transplantation, transplacental transmission or laboratory accidents. Tachyzoites are the infective form.
- **Transform into tachyzoites:** In the intestine, sporozoites are released from sporulated oocyst and bradyzoites are released from the tissue cyst. They invade the intestinal epithelium and transform into tachyzoites.
- **Transform into tissue cyst:** Tachyzoites multiply actively by endodyogeny and spread locally to the mesenteric lymph node. Subsequently, they also spread to distant extraintestinal organs like brain, skeletal and cardiac muscles, eye, liver, etc. where they transform into bradyzoites which multiply slowly to form tissue cysts.

### Sexual Cycle or Enteric Cycle (The Feline Cycle)

Cat and other felines (definitive host) acquire infection by ingestion of tissue cysts in the meat of rodents and other animals.

- Bradyzoites are released from the tissue cysts, which invade the intestinal epithelium, undergo several cycles of asexual generations (schizogony) before the sexual cycle begins
- Sexual cycle (gametogony) begins when the parasite differentiates to form male and female gametocytes which then transform into male and female gametes respectively

- Fertilization of male and female gamete results in formation of zygote which later gets surrounded by a thin, resistant rigid wall to form oocyst
- Oocysts are released in cat's feces which are unsporulated and noninfective. The maturation takes place 2–3 days later, in the humid environment. The mature sporulated oocyst containing two sporocysts is infectious to man for about 1 year (Fig. 7.1 D).

### Pathogenicity and Clinical Features

Toxoplasmosis is one of the most common parasitic zoonotic infections affecting a wide range of mammals and birds. Its prevalence in humans varies from 5–75% and depends on various risk factors like:

- The geographical area (cold area, hot arid climatic conditions, high altitudes are associated with a low prevalence)
- **Age:** It commonly affects older age and fetus
- Exposure to cat and cat's feces
- **Food habits:** Ingestion of uncooked cat and other animal meat (seen in countries like France)—at higher risk
- **Immune status:** Patients associated with HIV, malignancies and other immunocompromised conditions are at high risk
- Patients undergoing blood transfusion, and organ transplantations are at higher risk.

### Toxoplasmosis in Immunocompetent Patients

In the immunocompetent host, both the humoral and the cellular immune responses control the infection. The various mechanisms include activated macrophages, production of parasiticidal antibody, production of IFN- $\gamma$ , and stimulation of CD8<sup>+</sup> cytotoxic T lymphocytes.

- Hence, acute toxoplasmosis in the immunocompetent host is usually asymptomatic and self-limited
- **Lymphadenopathy:** The most common manifestation of acute toxoplasmosis is

cervical lymphadenopathy. Other lymph nodes may also be affected like sub occipital, supraclavicular and inguinal nodes

- Other symptoms include headache, malaise, fatigue and fever
- Rare complications are maculopapular rash, pneumonia, myocarditis and encephalopathy
- Acute infection usually resolves within several weeks, although the lymphadenopathy may persist for some months.

### **Toxoplasmosis in Immunocompromised Patients**

In contrast, in the immunocompromised host (patients associated with HIV, malignancies) or in fetus, the clinical manifestations are more severe due to the lack of the immune system to control the infection.

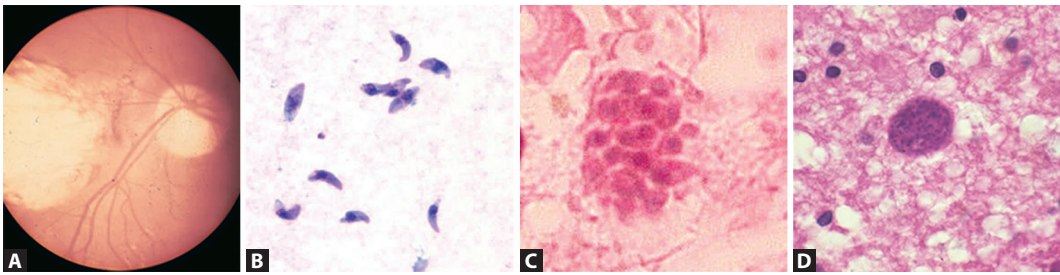
- The tachyzoites are disseminated to a variety of organs, particularly lymphatic tissue, skeletal muscle, myocardium, retina, placenta and the central nervous system (CNS)
- At these sites, the parasite infects host cells, replicates, leading to cell death and focal necrosis surrounded by an acute inflammatory response
- **Toxoplasmosis in patients with HIV:**
  - Toxoplasmosis is one of the common opportunistic parasitic infections in patients with AIDS (15–40%)
  - Infection occurs either due to reactivation of latent infection (more common) or as a newly acquired infection from an exogenous source such as blood or transplanted organs
  - It mainly targets CNS leading to *Toxoplasma* encephalitis (TE)
  - ***Toxoplasma* encephalitis:**
    - Most common areas involved in TE are the brainstem, basal ganglia, pituitary gland and corticomedullary junction
    - TE develops when the CD4+ T cell count falls below 100/μL

- Pathogenesis is due to the direct invasion by the parasite leading to necrotizing encephalitis and also due to secondary pressure effects on the surrounding area of the CNS
- Patients may present with altered mental status, seizures, sensory abnormalities, cerebellar signs and focal neurologic findings including motor deficits, cranial nerve palsies and visual-field loss
- Apart from CNS infections, other manifestations include pulmonary infections and chorioretinitis.

### **Congenital Toxoplasmosis**

Mother acquiring *Toxoplasma* infection in pregnancy is usually asymptomatic. However she can transmit the infection to the fetus.

- **Gestational age** is the main factor influencing the fetal outcome. As the gestation proceeds, the chance of transmission increases but the severity of the infection declines
  - If the mother becomes infected during the first trimester, the incidence of transplacental infection is lowest (15%), but the disease in the neonate is most severe
  - If maternal infection occurs during the third trimester, the incidence of transplacental infection is maximum (65%), but the infant is usually asymptomatic at birth
  - If the mother is infected before pregnancy, then the fetus is mostly uninfected except when the mother is immunocompromised
- Initially though asymptomatic, but the persistence of infection in the new born child can result in severe disease
- **Ocular involvement:** Most frequently it causes chorioretinitis leading to profound visual impairment. Other ocular manifestations include blurred vision, scotoma, photophobia, strabismus and glaucoma. (Fig.7.3A)



**Figs 7.3A to D: *Toxoplasma gondii*** (A) Severe, active retinochoroiditis seen in Toxoplasmosis; (B) Giemsa stain showing comma shaped tachyzoites in the smear; (C) Histopathology of brain shows pseudocyst containing numerous tachyzoites; (D) Tissue cyst containing bradyzoites (section of brain stained with hematoxylin and eosin)  
 Source: A, B and D- DPDx Image Library, Centre for Disease Control and prevention (CDC), Atlanta (with permission); C- Public Health Image Library, ID# 575/ Dr. Edwin P. Ewing, Jr Centre for Disease Control and prevention (CDC), Atlanta (with permission)

### Laboratory Diagnosis *Toxoplasma gondii*

- Direct microscopy (Detect tachyzoites in blood and tissue cyst in tissue biopsy):
    - Giemsa, PAS, silver stains, immunoperoxidase stain
    - Direct fluorescent antibody test
  - Antibody detection
    - Sabin feldman dye test
    - Detection of IgG in serum—ELISA, IFA
    - IgG avidity test
    - Detection of IgM in serum—ELISA, IFA and IgM-ISAGA
    - Differential absorption test
    - Detection of IgA—double sandwich ELISA
  - Detection of *Toxoplasma* antigen—ELISA
  - Molecular diagnosis—PCR
  - Animal inoculation—intraperitoneal inoculation into mice
  - Tissue culture—murine alveolar and peripheral macrophage cell line.
  - Imaging methods—CT and MRI to detect TE
- Other manifestations include still birth, intracerebral calcification, psychomotor disturbance, microcephaly and hydrocephaly
  - **“TORCH” infection:** *Toxoplasma* is included as one of the component (T) of **“TORCH”** infection, a term used to denote the agents causing congenital infections. Other components are: (R) *Rubella*, (C) *Cytomegalovirus*, (H) *Herpes*

*simplex virus*, (O) Others which includes *Treponema pallidum* (syphilis), *Varicella*, etc

- The incidence of congenital toxoplasmosis is approximately 1 per 1000 live births
- It is an important cause of repeated abortion and infertility. Hence, routine antenatal screening for *Toxoplasma* antibodies is advised in many advanced countries.

### Laboratory Diagnosis

#### Direct Microscopic Examination

- **Specimens:**  
 The specimens frequently examined are peripheral blood, body fluids, lymph node aspirate, bone marrow aspirate, cerebrospinal fluid (CSF) and bronchoalveolar lavage for HIV infected patients, biopsy material from spleen, liver and brain. These specimens are stained with Giemsa, PAS, silver stains, immunoperoxidase stain
- **Direct fluorescent antibody test (DFA):**  
 Tachyzoites can be detected by using fluorescein conjugated antibody against *T. gondii* surface antigens
- Comma-shaped tachyzoites are detected in the smear made from blood, body fluid and tissue and it indicates acute infection. (Figs 7.3B and C)
- Tissue cyst containing strongly PAS positive bradyzoites can be detected in various



tissues like brain or muscle. (Fig 7.3D)  
This denotes the presence of infection but cannot differentiate acute and chronic infection.

### Antibody Detection

Several methods are employed for detecting specific anti *T. gondii* antibodies like Sabin-Feldman dye test, enzyme-linked immunosorbent assay (ELISA), indirect fluorescent antibody test (IFA), indirect hemagglutination test (IHA) and latex agglutination test.

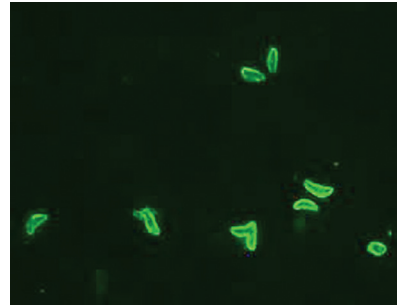
#### Sabin-Feldman dye test

This is the gold standard antibody detection method, usually done in the reference laboratories. Other serological tests are evaluated taking this test as standard.

- It is a complement mediated neutralization test that requires live tachyzoites
- In this test, live tachyzoites are incubated with complement and test serum. Subsequently alkaline methylene blue dye is added and mixture is reincubated
- *Toxoplasma* antibodies in the test serum bind to the antigens present on live tachyzoites which are subsequently killed as a result of complement mediated lysis.
- Killed tachyzoites are thin, distorted and colorless (not stained)
- The dilution of the test serum at which 50% of the tachyzoites are thin, distorted and colourless (i.e. killed) is reported as antibody titer of the test serum
- The dye test is highly sensitive and specific with no false positives reported so far
- Drawbacks of this test:
  - Difficulty in maintaining the live tachyzoites
  - It detects immunoglobulin G (IgG) antibodies, hence cannot differentiate recent or past infection.

#### Other antibody tests

Diagnosis of acute infection with *T. gondii* can be established by simultaneous detection



**Fig. 7.4:** Indirect fluorescent antibody test showing comma shaped tachyzoites (Tachyzoites coated smear + human antibodies to *Toxoplasma gondii* in serum+ fluorescein labelled antihuman immunoglobulin G = fluorescence)

Source: DPDx Image Library, Centre for Disease Control and prevention (CDC), Atlanta (with permission)

of IgG and IgM antibodies to *Toxoplasma* in serum.

- **Detection of IgG in serum:** Both ELISA and IFA formats (Fig. 7.4) are available to detect IgG antibodies. IgG appears as early as 2–3 weeks after the infection, peaks at 6–8 weeks and declines slowly to a baseline level that persists for life, hence it cannot differentiate acute or past infection. More so, it cannot be used to diagnose congenital infection (as IgG crosses placenta)
- **IgG avidity test:** The avidity of IgG antibody with its antigen increases with time and this can be useful in differentiating recent and past infection. Low IgG avidity indicates recent infection where as a strong avidity indicates past infection
- **Detection of IgM in serum:** It indicates acute infection. Double-sandwich IgM-ELISA, IgM-IFA and IgM- immunosorbent agglutination assay (IgM-ISAGA) are available which are sensitive and specific with fewer false-positive results. Presence of IgM antibodies in fetus indicates congenital infection
- **Differential absorption test:** When a mixture of IgG and IgM is present, 6-mercapto-purine can be used that absorbs IgM from



the mixture so that the remaining antibody after the absorption is IgG

- The presence of **circulating IgA** favors the diagnosis of an acute infection. The double-sandwich IgA-ELISA is more sensitive than the IgM-ELISA for detecting congenital infection in the fetus.

### Detection of *Toxoplasma* Antigens

ELISA is available to detect specific *Toxoplasma* antigens in blood or body fluids or amniotic fluid. Detection of antigen indicates acute infection. This is also useful to diagnose congenital infection.

### Molecular Diagnosis

Polymerase chain reaction (PCR) can be employed to detect *Toxoplasma* specific DNA from various clinical samples like blood or body fluids or amniotic fluid. PCR is highly sensitive, specific; can be used to diagnose TE or congenital infections in resource—poor settings.

Real-time PCR is more sensitive, rapid and can provide quantitative results.

### Animal Inoculation

*T. gondii* can be isolated from mice by intraperitoneal inoculation of the clinical samples into the healthy (*T. gondii* free) laboratory maintained mice. Mice die in 7–10 days and peritoneal fluid and spleen aspirate smears show tachyzoites. If death doesn't occur, then the mice are observed for 6 weeks and tail blood is screened for *Toxoplasma* antibodies.

### Tissue Culture

*T. gondii* can be isolated by inoculating into murine alveolar and peripheral macrophage cell line.

### Imaging Methods

Computed tomography (CT) scan or magnetic resonance imaging (MRI) of brain can be

done to demonstrate multiple ring enhancing lesions in basal ganglia or corticomedullary junction to diagnose TE in HIV patients.

### Cerebrospinal Fluid Abnormalities

Evaluation of CSF of patients with TE shows an elevation of intracranial pressure, lymphocytosis, and a slight increase in protein concentration, occasional increase in the gamma globulin level and a normal glucose level.

### Diagnosis of Congenital Toxoplasmosis

Congenital toxoplasmosis can be diagnosed by detecting:

- *Toxoplasma* antigens in amniotic fluid
- *Toxoplasma* specific genes by PCR
- IgM antibodies in fetal blood by ELISA or IFA
- IgA antibodies in fetal blood. Double-sandwich IgA-ELISA is more sensitive than the IgM-ELISA
- Isolation of the parasite by animal inoculation or tissue culture
- IgG antibodies can cross placenta, so it cannot differentiate congenital infection from maternal transfer. However, maternal IgG antibodies disappear after 6 months after birth. So, its persistence beyond 6 months after birth suggests congenital infection
- Ultrasound of fetus at 20–24 weeks of gestation is useful for detecting the lesions of congenital infection.

### Diagnosis of Toxoplasmosis in Immunocompromised Patients

Antibodies are produced at a very low level and irregularly in immunocompromised patients; hence, antibody detection methods are not reliable. All other diagnostic modalities can be employed in immunocompromised patients.

### Diagnosis of Ocular Toxoplasmosis

The serum antibody titer may not correlate with the presence of active lesions in the

Treatment	Toxoplasmosis
	<p><b>Immunocompetent patients</b></p> <p>Immunocompetent patients with only lymphadenopathy do not require specific therapy unless they have persistent, severe symptoms.</p> <p>Patients with ocular toxoplasmosis are usually treated for 1 month with pyrimethamine plus either sulfadiazine or clindamycin and sometimes with prednisolone.</p> <p><b>Congenital toxoplasmosis</b></p> <p>Neonates with congenital toxoplasmosis are treated with daily oral pyrimethamine (1 mg/kg) and sulfadiazine (100 mg/kg) with folinic acid for 1 year.</p> <p><b>Immunocompromised patients</b></p> <p>Toxoplasmosis is rapidly fatal in immunocompromised patients. If not treated, it may progress to encephalitis. So treatment is essential.</p> <p><b>(i) Primary prophylaxis</b></p> <p>Acquire immunodeficiency syndrome (AIDS) patients with <i>Toxoplasma</i> infection, having CD4+ T lymphocyte count of less than 100/μL should receive prophylaxis against TE.</p> <ul style="list-style-type: none"> <li>● Trimethoprim-sulfamethoxazole (cotrimoxazole) is the drug of choice</li> <li>● Dapsone-pyrimethamine, atovaquone with or without pyrimethamine can be given as alternate</li> <li>● Prophylaxis can be discontinued in patients who have responded to antiretroviral therapy (ART) and whose CD4+ T lymphocyte count has been more than 200/μL for 3 months.</li> </ul> <p><b>(ii) Secondary prophylaxis (Long-term maintenance therapy)</b></p> <p>Required for HIV positive patients who are previously treated for toxoplasmosis.</p> <ul style="list-style-type: none"> <li>● Should be started if the CD4+ T lymphocyte count decreases to less than 200/μL</li> <li>● However, it can be discontinued if the patient is asymptomatic, and have a CD4+ T lymphocyte count of more than 200/μL for at least 6 months.</li> </ul>

fundus, particularly in cases of congenital toxoplasmosis.

- In general, a positive IgG titer in serum along with typical lesions establishes the diagnosis
- Antibody production in ocular fluid can also be used for diagnosis
- Antigen detection or PCR can be done for the diagnosis of ocular toxoplasmosis.

## Prevention

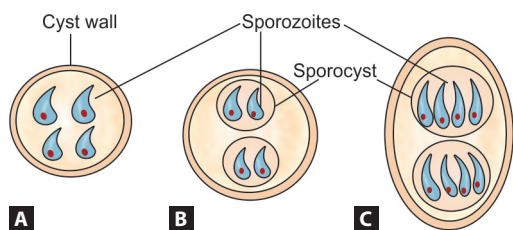
The various methods recommended to prevent toxoplasmosis include:

- Consumption of thoroughly cooked meat
- Proper hygiene maintenance and hand cleaning of people handling cats and other felines
- Regular prenatal and antenatal screening to detect *Toxoplasma* infection in women of child bearing age
- Avoiding cat's feces (oocyst) contaminated materials (like a cat's litter box)
- Screening of blood banks or organ donors for antibody to *T. gondii*.

## CRYPTOSPORIDIUM PARVUM

*Cryptosporidium* is an intestinal coccidian parasite affecting various animals and men.

- It causes self limiting acute diarrhea in immunocompetent healthy individuals; where as it is an opportunistic pathogen in immunocompromised patients (including HIV infected patients), causing chronic persistent life threatening diarrhea
- Tyzzer (1907) was the first to describe it in gastric crypts of laboratory mice. Subsequently it was found to affect many animals like rats, guinea pigs, pigs, horses, etc. The first human case was reported in 1976
- It belongs to the family Cryptosporidiidae. It is different from other coccidian parasites in such a way that it doesn't go deep into the host cells, but is confined to an **intracellular extra cytoplasmic location**. All the sexual and asexual stages of development take place within a **parasitophorous vacuole** that lies just below the cell membrane of



**Figs 7.5A to C:** Sporulated oocysts (schematic diagram) of (A) *Cryptosporidium*; (B) *Cyclospora*; (C) *Isospora*

the brush border epithelium of the small intestine

- *Cryptosporidium parvum* is the most common species affecting man. Other species infect wide range of mammals (*C. felis*, *C. canis* and *C. muris*), fishes (*C. nasorum*), birds (*C. meleagridis*, *C. baileyi*) and reptiles (*C. crotali*).

## Morphology

### Oocyst

It is the infective form to man as well as the diagnostic form excreted in the feces.

- It is round, small, 4–6  $\mu\text{m}$  in size, surrounded by a cyst wall and bears four sporozoites (Fig. 7.5)
- Each sporozoite is crescentic shaped with pointed anterior end, blunt posterior end and a nucleus located posteriorly
- Two types of oocysts are demonstrated—(1) thick walled and (2) thin walled
  - **Thick wall oocyst** contains two electro-dense cyst wall—outer uniformly thick, moderately coarse layer and an inner fine granular layer with a suture point at one pole. In between the two walls, lies an electroluscent middle zone containing two oocyst membranes
  - **Thin walled oocysts** are surrounded by a single layered membrane
- The oocysts are acid fast in nature but don't stain by iodine
- They are extremely resistant to routine chlorination, heat and other disinfectants.

## Life Cycle (Fig. 7.6)

*C. parvum* completes its life cycle (both sexual and asexual stages) in single host (man or other animals).

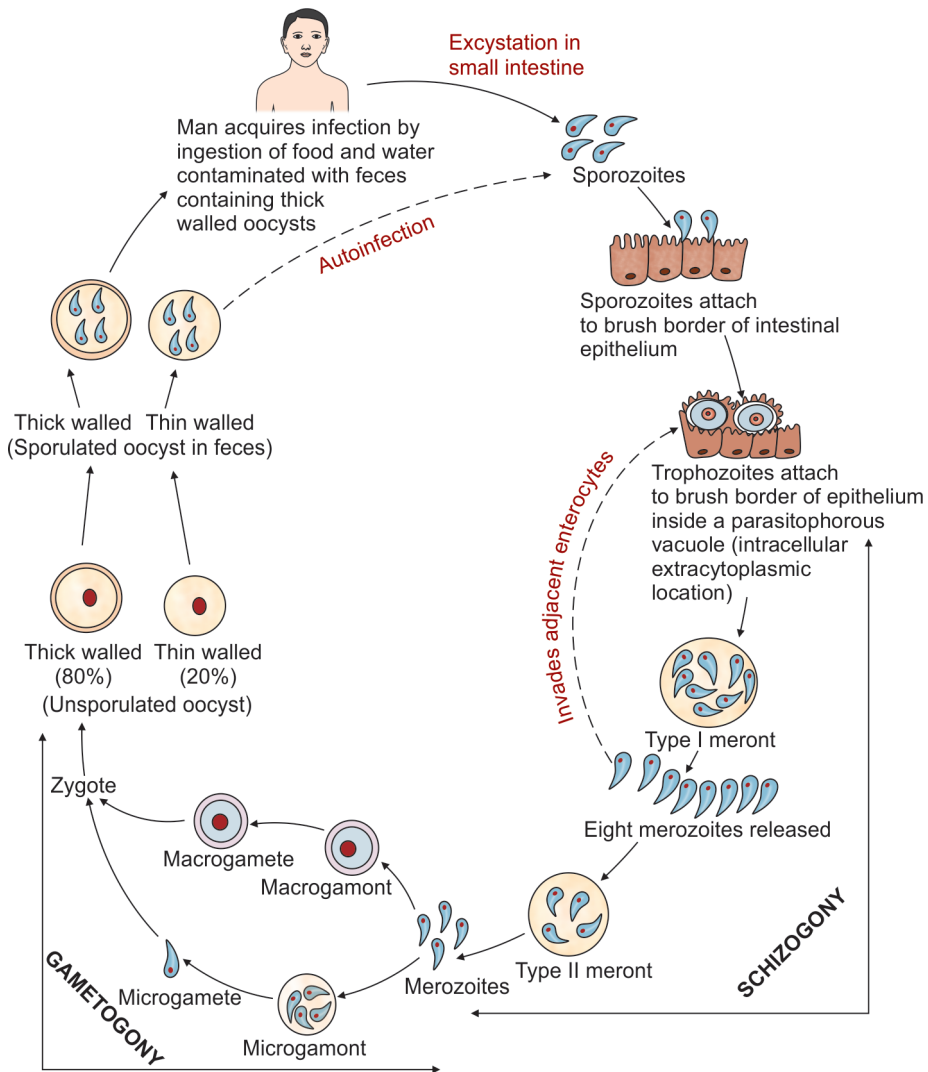
**Infective stage:** Sporulated oocyst is the infective form of the parasite. Thick walled oocyst is infectious to other persons, whereas the thin walled oocysts can cause autoinfection (through contaminated fingers).

**Mode of Transmission:** Man acquires infection by:

- Ingestion of food and water contaminated with feces containing thick walled oocysts
- **By autoinfection:** Thin walled oocyst can infect the same host

## Development in Man

- **Excystation:** In the small intestine, the suture present in the inner wall of the oocyst gets dissolved and four slender crescent shaped sporozoites are released from each oocyst. Various factors like pancreatic enzymes and bile salts help in excystation
- **Invasion:** Sporozoites invade the brush border epithelium of the small intestine and lie inside a parasitophorous vacuole near the microvilli surface, within which all the stages of development take place
- **Schizogony:**
  - The sporozoites subsequently differentiate into trophozoites which then undergo asexual multiplication (schizogony) to produce type I meronts
  - Each type I meront undergoes schizogony to release eight merozoites, which then again invade the adjacent enterocytes and undergo repeated schizogony to produce type II meronts
  - Four merozoites are released by the schizogony of each type II meront
- **Gametogony:**
  - The merozoites undergo gametogony and transform into sexual forms (microgamont and macrogamont)
  - Each microgamont releases 16 micro-



**Fig. 7.6:** Life cycle of *Cryptosporidium parvum*

gametes while only one macrogamete is produced from each macrogamont

- **Sporogony:**

- Fertilization takes place between microgamete and macrogamete to produce the zygote
- Subsequently, about 80% of zygote transform into highly resistant double layered thick walled oocyst and remaining 20% transform into single layered thin walled oocyst

- Within the host cell, the oocysts undergo sporogony to produce four sporozoites
- Sporulated oocysts are excreted in the feces. Thick walled oocyst infects the new hosts where as the thin walled oocysts infect the same host (autoinfection)

- **Prepatent period:** It is the period from the time of ingestion of oocyst to completion of the life cycle and release of newly developed oocyst in human feces (approximately 4–22 days).

## Epidemiology

Cryptosporidiosis is a zoonotic disease.

### Prevalence Rate of Cryptosporidiosis

In immunocompetent people, the prevalence in developing countries like India varies from 2.4 to 15%; where as in the western countries it is 1.4–6%

In immunocompromised hosts (HIV positive patients), the prevalence is 12–46% in developing countries (46% in Haiti) and 7–21% in developed countries.

### Factors that contribute to the disease include

- Low infective dose of *C. parvum* (10–100 oocysts can initiate the infection)
- Large multiplication capacity ( $> 10^{10}$ ) in single host
- Small size of the oocyst (4–6  $\mu\text{m}$ )
- Resistant to the available drugs and disinfectants
- Large animal and human reservoir
- Lack of appropriate immune response
- Poor sanitary conditions
- Travel to underdeveloped countries
- Zoonotic contact
- Peak age of infection: Infants and children.

## Pathogenesis and Clinical Features

- **Attachment:** Sporozoites attach to the brush border epithelium of the small intestine with the help of a unique protein called as **CP47** (47 kDa *C. parvum* protein)
- **Penetration:**
  - Discharges from the apicomplex (rhoptries, micronemes and dense granules) present in the anterior end of the sporozoites help in invasion
  - Following penetration, the parasite forms a parasitophorous vacuole near the microvilli surface of the host cells (intracellular extracytoplasmic location)
- Then, the parasite activates the host cell kinase signaling pathway that liberates

proinflammatory cytokines like tumor necrosis factor (TNF)- $\alpha$ , interleukine (Ic)-8, prostaglandins, etc

- Cytokines released from the inflammatory site can activate the phagocytes; attract fresh leukocytes which in turn liberate soluble factors
- These factors increase intestinal secretion of chloride and water and decrease the sodium absorption coupled to glucose transport. But sodium-glutamine transport is not affected. So, glutamine based ORS (oral rehydration solution) are more effective in treatment.

### Cryptosporidiosis in Immunocompetent Hosts

- Usually the infection is asymptomatic
- Sometimes, patient develops self-limiting watery nonbloody diarrhea
- Other features like abdominal pain, nausea, anorexia, fever, and/or weight loss may be present
- Symptoms develop after an incubation period of 1 week and subside within 1–2 weeks
- *C. parvum* accounts for 2–6% of cases of traveler's diarrhea.

### Cryptosporidiosis in Immunocompromised Hosts

- Disease is more severe in immunocompromised hosts especially in patients with AIDS having CD4+ T cell counts less than 100/ $\mu\text{L}$
- It produces a chronic, persistent remarkably profuse diarrhea (1–25 L/day), leading to significant fluid and electrolyte loss (resembling cholera and diarrhea)
- Severe weight loss, wasting and abdominal pain may be seen
- Autoinfection by thin walled oocyst is key factor for the chronic diarrhea which maintains the infection
- Involvement of sites other than small



intestine like pharynx, stomach, large intestine and respiratory tract is quite common in HIV positive patients

- Involvement of the biliary tract can cause papillary stenosis, sclerosing cholangitis, or cholecystitis and can manifest as mid-epigastric or right-upper-quadrant pain.

#### Laboratory Diagnosis

*Cryptosporidium parvum*

- Direct microscopy (Stool examination)—shows round 4–6  $\mu\text{m}$  size oocyst
  - Direct wet mount
  - Wet mount after concentration technique
  - Acid fast staining
  - Direct fluorescent antibody staining
- Antigen detection from stool—ICT, ELISA
- Antibody detection from serum—ELISA
- Molecular diagnosis—PCR
- Histopathology of intestinal biopsy specimen

### Laboratory Diagnosis

#### Direct Microscopy (Stool Examination)

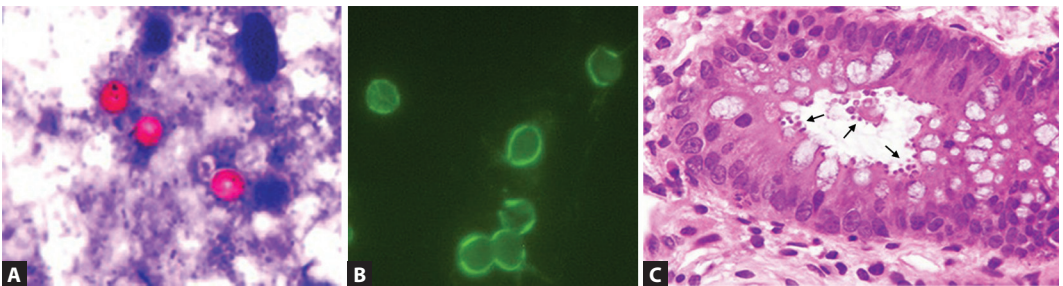
- **Sample collection:** Three consecutive stool samples should be collected. Rarely (in the HIV positive patients), sputum, bronchial wash, duodenal or jejunal aspirate can be collected
- **Direct wet mount:** Direct wet mounting from the mucus plug of the stool sample is done to demonstrate highly refractile, round, double walled 4–6  $\mu\text{m}$  size oocyst

- **Concentration technique:** If the oocyst load is less, then various techniques are used to concentrate the stool sample. They are two types of stool concentration techniques:

1. Flootation technique like Sheather's sugar floatation technique (widely used for coccidian parasites), zinc sulfate floatation technique or saturated salt floatation technique
2. Sedimentation technique like formalin ether or formalin ethyl acetate sedimentation technique

- **Staining procedures:**

- **Acid fast staining:** The oocysts of *C. parvum* are acid fast to 1% sulfuric acid or acid alcohol and appear as round, 4–6  $\mu\text{m}$  red color oocyst against blue back ground. The sensitivity of acid fast staining is low and it requires a minimum concentration of more than 50,000 oocysts/mL of stool. (Fig. 7.7A)
- Commonly used modified acid fast staining methods are:
  - Kinyoun's method (cold acid fast staining)
  - Rapid safranin methylene blue method
  - Carbol fuchsin negative staining method
- **Direct fluorescent antibody staining** is done to detect *C. parvum* oocyst by using fluorescent labelled monoclonal



**Figs 7.7A to C:** *Cryptosporidium* species (A) acid fast stain shows red color oocyst against blue back ground; (B) direct fluorescent antibody staining shows brilliant green fluorescent oocysts; (C) hematoxylin and eosin stain of intestinal biopsy shows numerous oocysts at the luminal surface of the intestinal crypt (marked by arrows)

Source: A, B and C- Giovanni Swierczynski, Bruno Milanese! "Atlas of human intestinal protozoa Microscopic diagnosis" (with permission)

antibody directed against cyst wall antigens. This is more sensitive (10 times) and specific than acid fast staining. It is also useful to detect oocyst from water and other environmental samples. Currently, this method is considered as the gold standard test for cryptosporidiosis. (Fig. 7.7B).

### Antigen Detection from Stool

ELISA has been developed to detect *C. parvum* specific coproantigen from stool, shows a sensitivity ranging from 66% to 100% with excellent specificity.

Immunochromatographic test (ICT) is also available for simultaneous detection of antigens of *C. parvum*, *Giardia* and *E. histolytica*.

### Antibody Detection

ELISA is used to detect *C. parvum* specific antibodies (IgM and IgG) in patient's serum for seroepidemiological purpose.

Indirect fluorescent antibody test is also available detecting *C. parvum* specific antibodies against oocyst antigens.

### Molecular Diagnosis

PCR is available to detect specific *C. parvum* genes from both clinical and environmental samples.

PCR is more sensitive, takes less time and can differentiate the *C. parvum* genotypes which plays an important role in outbreak situations.

### Histopathology

Various developmental stages of the parasite can be demonstrated from the intestinal biopsy specimens. (Fig. 7.7C).

### Other Methods

- Low CD4 -T lymphocyte count (especially in HIV positive patient)
- Fecal leukocyte marker—lactoferrin is increased in 75% of cases indicating increase pus cells in feces.

Treatment	Cryptosporidiosis
<ul style="list-style-type: none"> <li>• Mild cases are self limited, requires fluid replacement like ORS, with lactose-free glutamine supplemented diet</li> <li>• Severe cases: Nitazoxanide is given to adults (500 mg twice daily for 3 days). Paromomycin can be given as an alternate. Macrolide antibiotics including spiramycin, azithromycin and clarithromycin have some activity against <i>Cryptosporidium</i> species.</li> </ul>	

### Prevention

- Requires minimizing exposure to infectious oocysts in human or animal feces
- Proper hand washing, use of submicron water filters, improved personal hygiene are some of the efforts to prevent transmission.

## CYCLOSPORA CAYETANENSIS

### History

*Cyclospora cayetanensis* is the most recently described coccidian parasite as human intestinal pathogen. It is named by Schneider in 1881 and human infection was described by Ashford in 1979.

### Life Cycle

Humans are the only known host. Man gets infection by ingestion of food and water contaminated with sporulated oocyst in soil.

Life cycle is not fully understood, but believed to be similar to that of *C. parvum* except (Table 7.1):

- The oocysts released in the human feces are unsporulated
- The sporulation of oocyst takes place in the soil (environment) whereas in *C. parvum*, the sporulation of oocyst takes place in the human intestine
- **Morphology of sporulated oocyst:** mature oocyst is round, 8–10  $\mu\text{m}$  size, contains two sporocysts, each containing two sporozoites (Fig. 7.5C).



**Table 7.1:** Differences between *Cryptosporidium*, *Cyclospora* and *Isospora*

Property	<i>Cryptosporidium</i>	<i>Cyclospora</i>	<i>Isospora</i>
Infective form	Sporulated oocyst	Sporulated oocyst	Sporulated oocyst
Diagnostic form	Sporulated oocyst	Unsporulated oocyst	Unsporulated oocyst
Outbreaks	Common	Occasional	Occasional
Oocyst size	4–6 µm	8–10 µm	23–36 µm
Oocyst shape	Round	Round	Oval
Sporulated oocyst contain	Four sporozoites	Two sporoblast, each having two sporozoites	Two sporoblast, each having four sporozoites
Acid fastness	Uniformly acid fast	Variable acid fast	Uniformly acid fast
Autofluorescence	No, but can be stained with fluorescent dye	Autofluorescence ++	Autofluorescence +/-
Sporulation of the oocyst	Occurs inside the host cells (enterocytes)	Occurs in soil (environment)	Occurs in soil (environment)
Treatment	Nitazoxanide	Cotrimoxazole	Cotrimoxazole

## Clinical Features

- It causes self-limiting diarrhea resembling *C. parvum* infection
- Disease is more severe with biliary tract involvement in immunocompromised (HIV positive patients).

## Epidemiology

- Disease is prevalent in Central America and South Asia
- More cases are reported from Haiti (11% of AIDS related diarrhea), children of Nepal (32%) and travelers coming to India, Pakistan and Morocco
- However, it is less common in African countries.

### Laboratory Diagnosis *Cyclospora*

- Stool examination—Shows round oocysts
  - Wet mount examination
  - Acid fast stain—shows variably acid fast oocysts
  - UV epifluorescence microscopy—shows autofluorescence oocysts
- Molecular diagnosis—rt-PCR
- Serology (antibody detection)
- Histopathology of intestinal biopsies

## Laboratory Diagnosis

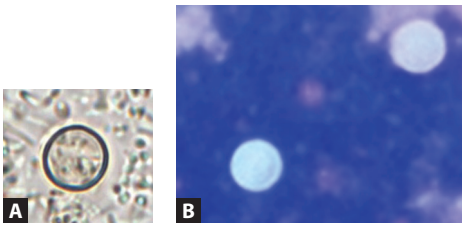
### Stool Examination

Stool examination is done similar to that for cryptosporidiosis. Multiple stool specimens are examined by direct microscopy (Fig. 7.8) or stained by acid fast stains or fluorescent stains

- *Cyclospora* oocysts are approximately twice the size of *Cryptosporidia* oocysts. It is round, 8–10 µm size and **variably acid fast** (i.e. 50% of oocyst are acid fast, rest are non acid fast) (Fig. 7.9)
- **Auto-fluorescence** of the oocysts under ultraviolet epifluorescence microscopy is both rapid and sensitive, although not specific (Fig. 7.8B)
- Additional stains includes auramine, safranin and lactophenol cotton blue.

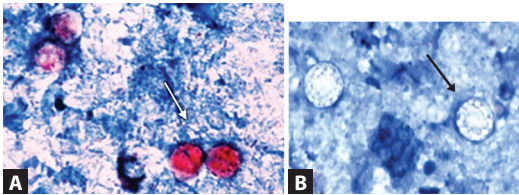
### Molecular Diagnosis

Species-specific real-time polymerase chain reaction (rt-PCR) assays have been developed detecting low concentrations of oocysts in stool. Though not widely available, but it is more sensitive than conventional diagnostic methods. Flow cytometry has been proposed as an alternate method of diagnosis.



**Figs 7.8A and B:** *Cyclospora* species (A) saline mount preparation showing unsporulated oocyst; (B) epifluorescence microscopy showing autofluorescent oocysts

Source: (A) Dr Anand Janagond, Associate professor, Velammal Medical College, Madurai, Tamilnadu, (B) Giovanni Swierczynski, Bruno Milanesi. "Atlas of human intestinal protozoa Microscopic diagnosis" (with permission)



**Figs 7.9A and B:** *Cyclospora* species modified acid fast stain shows variable acid fast oocyst (A) acid fast oocysts, (B) non acid fast oocysts

Source: Giovanni Swierczynski, Bruno Milanesi. "Atlas of human intestinal protozoa microscopic diagnosis" (with permission)

### Serology

Antibodies to *Cyclospora* can be detected, but serologic tests are not commercially available.

### Histopathology

Biopsy specimens from the intestine show villous atrophy, acute and chronic inflammatory changes in the lamina propria. Inside the enterocytes, *Cyclospora* is supranuclear in location, whereas *Cryptosporidium* is located on the surface of the enterocytes.

## ISOSPORA BELLI

### Introduction

Though more than 200 *Isospora* species are identified, but *Isospora belli* is the only species

that infects man. No other animal reservoir is known.

- It belongs to the family Sarcocystiidae
- It was first described by Virchow in 1860 and was named by Wenyon (1923).

### Morphology

#### Oocyst

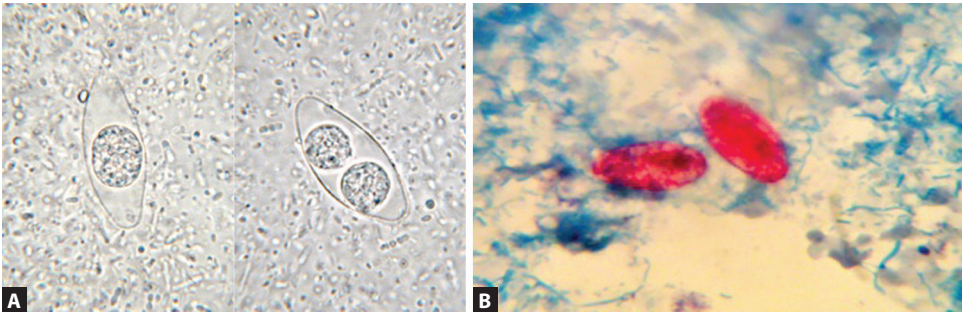
The sporulated oocyst is oval/elliptical, 23 to 36  $\mu\text{m} \times 12$  to 17  $\mu\text{m}$  in size, contains two sporocysts, each with four sporozoites. The oocyst is surrounded by a thin, smooth, two layered cyst wall (Fig. 7.5C).

### Life Cycle

Man gets infection by ingestion of food and water contaminated with sporulated oocyst in soil.

- In the proximal small intestine, eight sporozoites are released from each oocyst. They invade the duodenal and jejunal epithelium and transform into trophozoites
- Trophozoites multiply and transform into schizont that undergoes asexual multiplication (schizogony) to produce merozoites
- Merozoites again attack fresh enterocytes to repeat the asexual cycle. Some of the merozoites transform into microgametocyte and macrogametocyte (**gametogony**)
- Eventually, they form macrogametes and microgametes which fuse to form the zygote (**fertilization**)

Treatment	Cyclosporiasis
	<ul style="list-style-type: none"> <li>• Cyclosporiasis is treated with cotrimoxazole (trimethoprim 160 mg/sulfamethoxazole 800 mg twice daily for 7 days). HIV-infected patients may experience relapses and may require long-term suppressive maintenance therapy</li> <li>• Patients who cannot tolerate cotrimoxazole may be treated with ciprofloxacin or nitazoxanide.</li> </ul>



**Figs 7.10A and B:** *Isospora belli* (A) saline mount preparation shows left—unsporulated oocyst and right—sporulated oocyst; (B) modified acid fast stain shows unsporulated oocyst

Source: A- Giovanni Swierczynski, Bruno Milanese. "Atlas of human intestinal protozoa Microscopic diagnosis" (with permission); B- Anand Janagond, Associate professor, Velammal Medical College, Madurai, Tamilnadu (with permission)

- Zygotes secrete the cyst wall and develops into immature oocysts, excreted in the feces
- In the soil, the sporulation occurs within 3–4 days and immature oocyst transform into sporulated oocyst which bears two sporocysts each containing four sporozoites.

#### Laboratory Diagnosis *Isospora belli*

- Stool examination (by wet mount, acid fast stain)—detects oval oocysts
- Molecular diagnosis—PCR
- Histopathology of tissue sections from small bowel

### Epidemiology

Isosporiasis is found worldwide but predominantly in tropical and subtropical climates, especially in South America, Africa, and Southeast Asia including India.

It is frequently associated in AIDS patients, prevalence ranging from 3% (USA) to 37% (Zambia). However, it is rare in HIV infected children (different from cryptosporidiosis).

### Clinical Feature

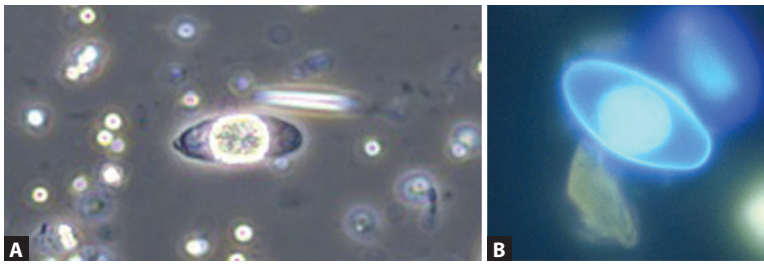
Acute infections can begin abruptly with fever, abdominal pain, and watery nonbloody diarrhea and can last for weeks or months.

- Disease is less severe and outbreaks are less common compared to cryptosporidiosis
- In immunocompromised or HIV positive patients, disease is more severe resembling cryptosporidiosis; with chronic, profuse watery diarrhea and extraintestinal infections such as involvement of biliary tract.

### Laboratory Diagnosis

Laboratory methods are similar to that for cryptosporidiosis.

- Stool examination—diagnosis can be established by demonstration of characteristic oval oocyst in patient's stool by:
  - Saline wet mounting of stool (Fig. 7.10A)
  - **Acid fast stained smears:** The oocyst is uniformly acid fast, oval/elliptical, 23–36  $\mu\text{m} \times 12$ –17  $\mu\text{m}$  in size, surrounded by a thin, smooth, two layered cyst wall (Fig. 7.10B)
  - Other stains like lactophenol cotton blue and safranin can be used
  - **Fluorescent stained smears:** By auramine rhodamine stain (Fig. 7.11)
  - **Autofluorescence** can be seen under 330–380 nm ultraviolet filter. However, this property is not consistent like in *Cyclospora*
  - Phase contrast microscopy is also useful (Fig. 7.11)



**Figs 7.11A and B:** *Isospora belli* unsporulated oocyst under (A) phase contrast microscopy; (B) fluorescent stained smears

Source: Giovanni Swierczynski, Bruno Milanese. "Atlas of human intestinal protozoa Microscopic diagnosis" (with permission)

- If the oocyst load is less, then stool samples are concentrated by Sheather's sugar floatation technique
- Examination of small bowel specimens (e.g., duodenal aspirates) may be helpful if stool examination is negative
- **Other tests:**
  - Peripheral blood eosinophilia
  - Charcot-Leyden crystals in stool
  - Low CD4- T cell count (in HIV infected patients)
- **Molecular methods:** PCR using *I. belli* specific primers is highly sensitive and specific but is use for routine diagnosis which requires further study
- **Histopathologic examination:** Tissue sections from the small bowel of infected patients reveal villous atrophy, crypt hyperplasia and inflammatory cells (eosinophils) infiltration of lamina propria. Asexual and sexual stages of the parasite can be identified within the parasitophorous vacuoles of the enterocytes.

Treatment	<i>Isospora belli</i>
	twice daily for 7 days followed by suppressive therapy three times weekly
	<ul style="list-style-type: none"> <li>• Nitazoxanide has also been used successfully.</li> </ul>

## SARCOCYSTIS SPECIES

*Sarcocystis* is a zoonotic parasite. Though more than 120 species of *Sarcocystis* have been reported infecting a wide range of domestic and wild animals but the frequency of human infection is relatively low.

- It was first described in the skeletal muscle of a house mouse in 1843 in Switzerland
- There are two types of human sarcocystosis:
  1. **Intestinal sarcocystosis:** Caused by *S. hominis* and *S. suihominis*
  2. **Muscular sarcocystosis:** Caused by unidentified species of *Sarcocystis* collectively known as *S. lindemanni*.

## Morphology

It exists in three morphological forms.

## Oocyst

Oocysts are found usually in the intestine of the definitive host. They sporulate within the lamina propria of the intestinal epithelium

- The sporulated oocyst is elongated, oval, colorless thin walled ( $< 1\mu\text{m}$ ), measures  $13\text{--}19\mu\text{m}$  in *S. hominis* and  $10\text{--}13\mu\text{m}$  in *S. suihominis* respectively

Treatment	<i>Isospora belli</i>
	<ul style="list-style-type: none"> <li>• Cotrimoxazole (160 mg trimethoprim/800mg sulfamethoxazole) is the treatment of choice. It is administered four times daily for 10 days</li> <li>• Patients with HIV infection usually require longer courses but have more chance of relapse</li> <li>• Alternatives treatment: Pyrimethamine (75 mg/day) together with folinic acid (10 to 25mg/day), or ciprofloxacin (500 mg</li> </ul>

- It contains two elongated sporocysts and each sporocyst contains four elongated sporozoites.

### Sporocyst

From the sporulated oocyst, sporocysts are released and are excreted in the feces of definitive host. It is the infective form to the intermediate host. It is oval 9–16  $\mu\text{m}$  size and contains four elongated sporozoites.

### Sarcocyst

Sarcocysts (muscular cysts) are found in the cardiac and skeletal muscles (of diaphragm, oesophagus) of the intermediate host

- It is elongated, measures 100–325  $\mu\text{m}$  size (may be few mm long), found longitudinally along the muscle fibre
- It has a thick cyst wall and is always surroun-

ded by a parasitophorous vacuole within the cytoplasm of the muscle cells

- The cyst is divided into many compartments that contain numerous banana shaped **bradyzoites** or metrocytes (7–16  $\mu\text{m}$  long) containing prominent PAS (periodic acid Schiff stain) positive amylopectin granules.

### Life Cycle (Fig. 7.12)

Unlike other coccidian parasites, *Sarcocystis* has an obligatory two-host (prey-predator) life cycle.

- As a rule:
  - Sexual cycle takes place in the intestine of the carnivorous/predator animal (definitive host)
  - Asexual cycle takes place in the muscle and other tissues of the herbivorous/prey animal (intermediate host)

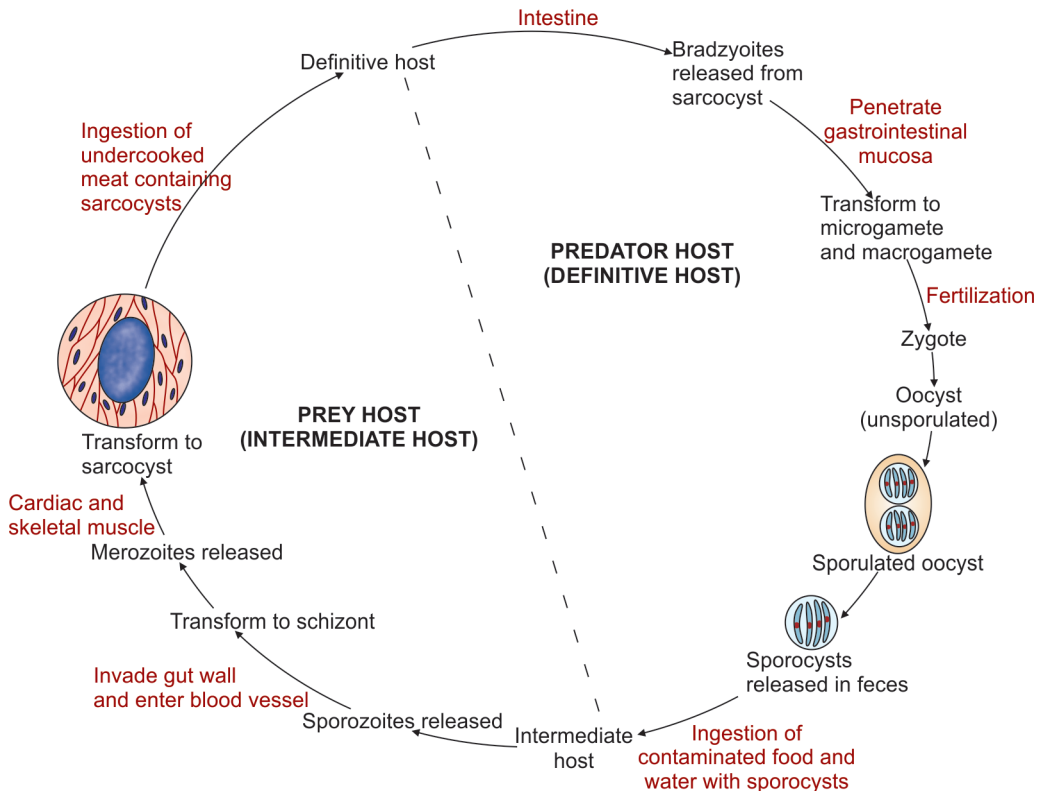


Fig. 7.12: Life cycle of *Sarcocystis* species



- Definitive and intermediate hosts are generally species specific:
  - Intestinal sarcocystosis in man:** Caused by *S. hominis* and *S. suis hominis*. Man acts as a definitive host. Cattle and pigs serve as intermediate hosts for *S. hominis* and *S. suis hominis* respectively
  - Muscular sarcocystosis in man:** Caused by *S. lindemanni*. Man acts as an intermediate host. Dogs and cats serve as definitive hosts.

### Intestinal Sarcocystosis

#### The human cycle

Man (definitive host) gets infection by ingestion of raw or undercooked beef (*S. hominis*) or pork (*S. suis hominis*) containing sarcocysts.

- Bradyzoites are released from sarcocysts and penetrate the intestinal mucosa, multiply and transform into microgamete (male) and macrogamete (female)
- Fertilization occurs and zygote is formed which later on transform into an oocyst
- Subsequently, the oocyst undergoes maturation to form sporulated oocysts which bear two sporocysts each containing four sporozoites
- Sporocysts are released from the sporulated oocysts in the human feces and are infective to the intermediate host (i.e. cattle or pig).

#### The pig/cattle cycle

The intermediate host becomes infected by ingestion of food or water contaminated with sporocysts.

- In the gut lumen, four sporozoites are released from each sporocyst which directly invades the intestinal blood vessels, transform into schizonts
- Two generations of schizonts are formed within the vascular endothelium
- Merozoites released from the schizonts, invade the cardiac and skeletal muscle and transform into sarcocysts containing numerous bradyzoites
- The cycle gets repeated by ingestion of raw or undercooked pork or beef containing sarcocysts by the definitive host (man).

### Muscular Sarcocystosis

Men (intermediate host) acquire infection by ingestion of food and water contaminated with sporocysts excreted in the feces of dogs and cats.

- Sporozoites released from the sporocysts invade the gut vessels, transform into two generations of schizonts. Merozoites released from the schizonts invade the cardiac and skeletal muscle and transform into sarcocysts
- The life cycle in cats and dogs is similar to that of human cycle of intestinal sarcocystosis.

### Clinical Features

#### Intestinal Sarcocystosis

- It is usually asymptomatic but patient may develop nausea, vomiting, abdominal pain and diarrhea
- Symptoms appear early after ingestion of beef (3–6 hours) than pork (24 hours)
- Various studies have shown a natural prevalence of 2–10% throughout the world, including India (14 cases due *S. suis hominis* were reported from Indian children).

#### Muscular Sarcocystosis

- It is also usually asymptomatic
- Symptoms depend on the size of the muscle cysts that varies from 50 µm to 5 cm
- Larger cysts can cause muscle pain, weakness in muscle or rarely focal myositis and eosinophilic myositis
- Myocarditis and pericarditis are rare findings
- So far, 46 confirmed cases (35 skeletal and 11 cardiac) of human muscular sarcocystosis have been reported from the world (which includes 11 cases from India).

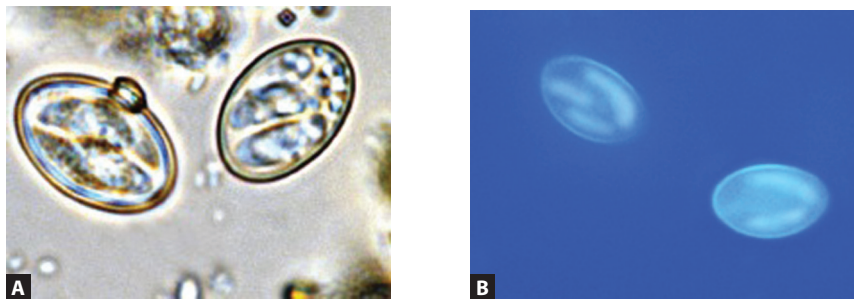
### Laboratory Diagnosis Sarcocystis

#### Intestinal sarcocystosis

- Stool microscopy (wet mount)-detects sporocysts

#### Muscular sarcocystosis

- Histological Examination of muscle biopsy—detects sarcocysts
- Serum antibodies—by Western blot



**Figs 7.13A to B:** *Sarcocystis* sporocysts containing sporozoites (A) saline mount; (B) autofluoresce under UV light-sporozoites are clearly seen

Source: (A and B) Giovanni Swierczynski, Bruno Milanese."Atlas of human intestinal protozoa Microscopic diagnosis". (with permission)

**Laboratory Diagnosis**

**Intestinal Sarcocystosis**

It is diagnosed by stool fecal examination demonstrating the sporocysts or sporulating oocysts of *Sarcocystis* (Fig. 7.13A).

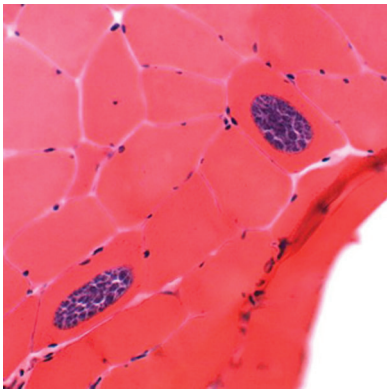
- Speciation is not possible as the oocysts of all the species are morphologically similar
- The sporocysts are excreted in the feces of the infected patient as long as 14–18 days and 11–13 days after ingestion of uncooked beef and pork respectively
- Flotation methods are used to concentrate the stool
- *Sarcocystis* sporocysts exhibit autofluoresce under UV light (Fig. 7.13B).

**Muscular Sarcocystosis**

**Histological examination**

Histological examination of muscle biopsy can be done to demonstrate the sarcocysts in cardiac and skeletal muscle (Fig. 7.14)

- They measure 100–325 µm in size, contain numerous PAS positive bright red bradyzoites measuring 7–16 µm long
- An active infection is characterized by immature sarcocysts associated with an inflammatory response, whereas mature sarcocysts without any inflammation indicates past infection
- Myositis and myonecrosis, tissue eosinophilia, and inflammatory changes may be



**Fig. 7.14:** *Sarcocysts* in skeletal muscle biopsy

Source: DPDx Image Library, Centre for Disease Control and prevention (CDC), Atlanta (with permission)

seen in cases of eosinophilic myositis

**Serology**

Detecting antibodies using Western blot suggests past exposure, but is not diagnostic of acute disease.

Treatment	Sarcocystosis
<ul style="list-style-type: none"><li>• No specific treatment for <i>Sarcocystis</i> infection is known. Infection, if symptomatic, is generally self-limited</li><li>• Cotrimoxazole, furazolidone and albendazole are used but their efficacy is doubtful</li><li>• Corticosteroids may provide symptomatic relief in cases of eosinophilic myositis.</li></ul>	



### EXPECTED QUESTIONS

#### I. Write essay on:

- (a) Classify the coccidian parasites? Describe the life cycle, pathogenesis and laboratory diagnosis of *Toxoplasma gondii*?
- (b) Enumerate the opportunistic parasitic infections in patients with AIDS. Describe the life cycle, pathogenesis and laboratory diagnosis of *Cryptosporidium parvum*?

#### II. Write short notes on:

- (a) Cyclosporiasis
- (b) Muscular sarcocystosis
- (c) Isosporiasis
- (d) Sabin-Feldman dye test
- (e) Congenital toxoplasmosis

#### III. Multiple choice questions (MCQs):

##### 1. Oocysts of *Toxoplasma gondii* are excreted in the feces of:

- (a) Cat                      (b) Sheep
- (c) Cattle                (d) Humans

##### 2. Congenital toxoplasmosis is more severe in which trimester of pregnancy?

- (a) First                    (b) Second
- (c) Third                  (d) During delivery

##### 3. Most common manifestation of *Toxoplasma gondii* in immunocompetent adult:

- (a) Lymphadenopathy
- (b) Chorioretinitis
- (c) Myocarditis
- (d) Encephalitis

##### 4. Most common manifestation of *Toxoplasma gondii* in immunocompromised adult:

- (a) Lymphadenopathy
- (b) Chorioretinitis
- (c) Myocarditis
- (d) Encephalitis

##### 5. Most common manifestation of congenital toxoplasmosis:

- (a) Lymphadenopathy
- (b) Chorioretinitis
- (c) Myocarditis
- (d) Encephalitis

##### 6. Sporulated oocyst of *Isospora belli* contains:

- (a) One sporocyst and two sporozoites
- (b) One sporocyst and four sporozoites
- (c) Two sporocysts and four sporozoites
- (d) Two sporocysts and eight sporozoites

##### 7. Sporulated oocyst of *Cyclospora cayetanensis* totally contains:

- (a) One sporocyst and two sporozoites
- (b) One sporocyst and four sporozoites
- (c) Two sporocysts and four sporozoites
- (d) Two sporocysts and eight sporozoites

##### 8. Which statement is false about *Cryptosporidium parvum*?

- (a) Developmental stages of the parasite occur inside a parasitophorous vacuole
- (b) High infective dose
- (c) Large number of animal reservoir
- (d) It causes diarrhea in AIDS patients

##### 9. Intermediate host for *Sarcocystis suihominis* is:

- (a) Pig                      (b) Dog
- (c) Man                    (d) Cattle

##### 10. For muscular sarcocystosis, man acts:

- (a) Intermediate host
- (b) Definitive host
- (c) Only host
- (d) Paratenic host

### Answer

1. a      2. a      3. a      4. d      5. b      6. d      7. c      8. b      9. a      10. a

# 8 Miscellaneous Protozoa

## Chapter Outline

- Microsporidium species
- Balantidium coli
- Blastocystis hominis
- Expected questions

## MICROSPORIDIUM SPECIES

### Classification

Microsporidia are eukaryotic, spore forming obligate intracellular parasite infecting a broad range of vertebrates and invertebrates.

- In humans, they are opportunistic pathogens affecting HIV positive patients
- Microsporidia have a unique character of entering into the host cell via a polar tube within a spore.

**Taxonomical classification:** Previously they were under sporozoa. Recent reports suggest that they resemble fungus (Table 8.1).

**Classification based on their habitat:** Microsporidia include over 150 genera comprising 1200 species. However, only eight genera com-

prising fourteen species are found to infect man (Table 8.2).

### Morphology of Spores

It is highly resistant extracellular form (survives in the environment) and also is the infective stage.

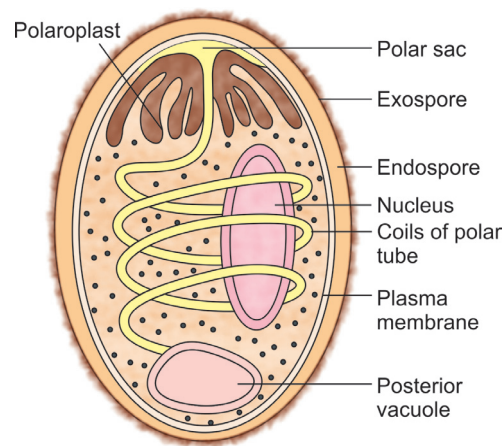
- It is oval, variable size ranging from 1.5–5  $\mu\text{m}$  depending on the genera (Fig. 8.1)
- It has a double layered cyst wall. Outer layer (exospore) is proteinaceous and electron dense. Inner layer (endospore) is chitinous and electron-lucent
- Inner side of the cyst wall is lined by plasma membrane
- Cytoplasm contains various organelles like coiled polar tube, polar sac, polaroplast,

**Table 8.1:** Taxonomical classification of Microsporidia

Kingdom	Phylum	Class	Order	Genus
Fungi	Microspora	Microsporea	Microsporidia	<ul style="list-style-type: none"><li>• <i>Enterocytozoon</i></li><li>• <i>Encephalitozoon</i></li><li>• <i>Pleistophora</i></li><li>• <i>Trachipleistophora</i></li><li>• <i>Brachiola</i></li><li>• <i>Nosema</i></li><li>• <i>Vittaforma</i></li><li>• <i>Microsporidium</i></li></ul>

**Table 8.2:** Classification of Microsporidia according to their habitat

Genus	Species	Habitat and infections
<i>Enterocytozoon</i>	<i>E. bienewisi</i>	Small intestine: Enteric infection Rarely cause nasal polyp, infections of bile duct and bronchus
<i>Encephalitozoon</i>	<i>E. intestinalis</i>	Small intestine: Enteric infection
	<i>E. cuniculi</i>	Small Intestine: Enteric infection Eye: Corneal and conjunctival epithelium Rarely: Hepatitis, peritonitis and renal infection (UTI)
	<i>E. hellem</i>	Eye: Corneal and conjunctival epithelium
<i>Pleistophora</i>	<i>P. ronneae</i>	Skeletal muscle (myositis)
<i>Trachipleistophora</i>	<i>T. hominis</i>	Eye: Corneal and conjunctival epithelium, Rarely muscle and renal infection
	<i>T. anthropophthera</i>	Brain
<i>Brachiola</i>	<i>B. vesicularum</i>	Skeletal muscle
	<i>B. connori</i>	Eye: Corneal stroma Smooth and cardiac muscle
	<i>B. algerae</i>	Muscle
<i>Nosema</i>	<i>N. ocularum</i>	Eye: Corneal stroma
<i>Vittaforma</i>	<i>V. corneae</i>	Eye: Corneal stroma Rarely, UTI
<i>Microsporidium</i>	<i>M. ceylonensis</i>	Eye: Corneal stroma
	<i>M. africanum</i>	Eye: Corneal stroma



**Fig. 8.1:** Morphology of Microsporidia spore (schematic diagram)

- nucleus and a posterior vacuole
- Coiled polar tube has a spring like tubular extrusion mechanism by which the infective

material, **sporoplasm** is injected into the host cell

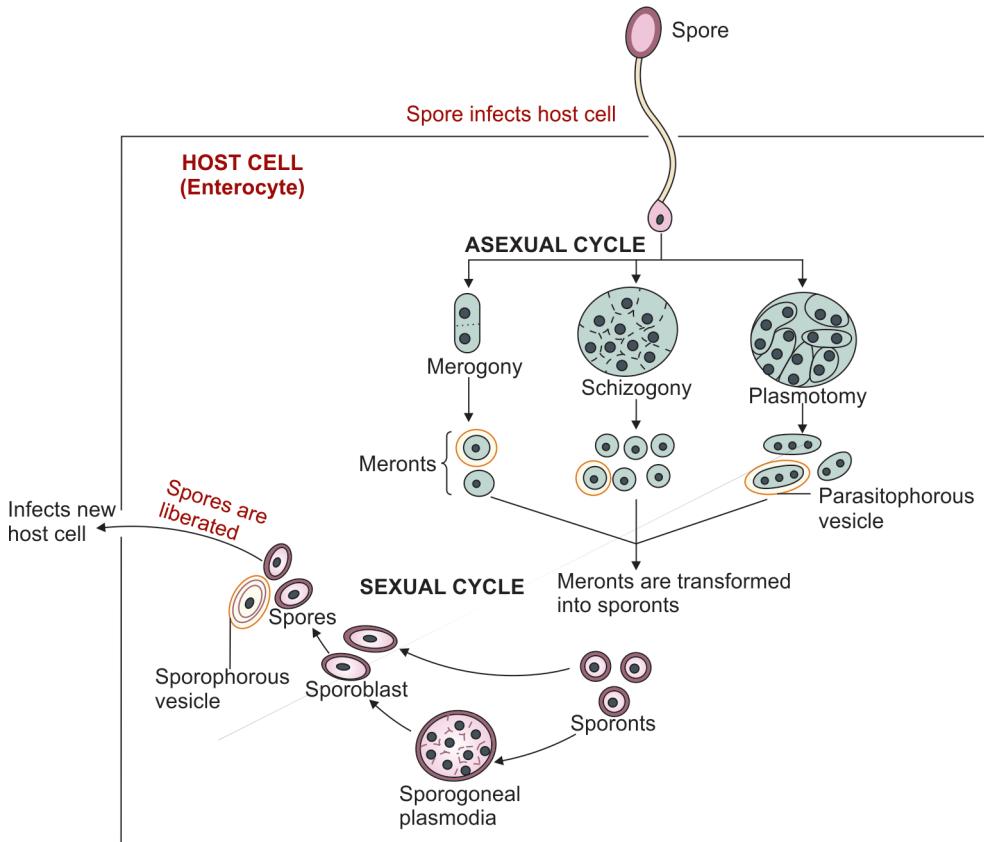
- The polar tube ends anteriorly into a **polar sac** (Fig. 8.1)
- Near the anterior pole, **polaroplast** is situated on both the side of the polar tube, which is a component of the extrusion apparatus.

**Life Cycle (Fig. 8.2)**

**Mode of transmission:** Humans acquire infection by ingestion (or rarely inhalation or ocular contact) of spores of microsporidia.

**Extrusion of Sporoplasm**

- The infective material of the spore (sporoplasm) is injected into the host cell (**enterocyte**)
- The polar tube comes out of the spore as a long flexible cylindrical structure and



**Fig. 8.2:** Life cycle of Microsporidia

injects the sporoplasm by the extrusion mechanism (helped by the polar sac, polaroplast, raised pH and calcium ion) into the host cell in two ways:

1. By punching a hole in the host cell plasma membrane, e.g., *Enterocytozoon*
2. Or by the expansion of the host cell plasma membrane to cover the emerging sporoplasm, e.g., *Encephalitozoon*.

### Asexual Cycle

Inside the host cell, the sporoplasm multiplies to generate a number of meronts.

- Multiplication occurs either by merogony (binary fission) or schizogony (multiple fission) or plasmotomy (division of cytoplasm without their relation to nuclei to

produce multinucleated offspring)

- Meronts are round to elongated. They remain free in the host cell cytoplasm (in most species) or lie inside a parasitophorous vacuole (e.g., *Encephalitozoon*).

### Sexual Cycle (Sporogony)

Finally, the meronts develop into sporonts; which then eventually get surrounded by a double layered cyst wall and directly transform into sporoblasts or may become multinucleated to form sporogoneal plasmodia that later transform into sporoblasts.

- Sporoblasts undergo sporogony and develop into spores
- Spores are present either free in the host cytoplasm or enclosed by a

sporophorous vesicle (e.g. *Pleistophora* and *Trachipleistophora*)

- Most of the species, the spores are liberated by lysis of the host cell except in *Encephalitozoon hellem*, where the spores germinate without host cell lysis.

### Pathogenesis and Clinical Feature

Microsporidia mainly cause opportunistic infections in patients with acquired immunodeficiency syndrome (AIDS) or in any other patients with immunosuppression like recipients of organ transplant. Various clinical presentations are described in Table 8.3.

### Epidemiology

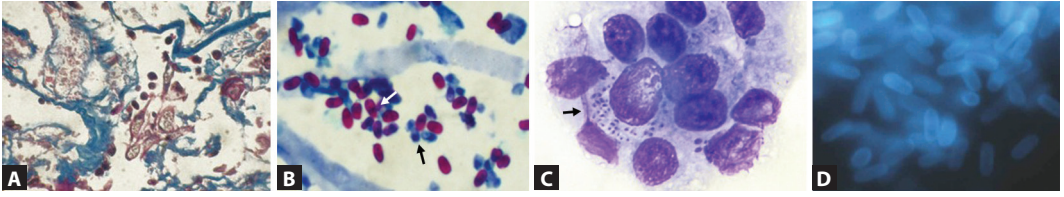
Though, the first human case of microsporidian infection was reported in 1959,

but it is being increasingly recognized as opportunistic infectious agent worldwide since the advent of HIV AIDS.

- The largest number of cases have been reported in AIDS patients from North America, western Europe and Australia where the prevalence ranges from 2% to 50% or higher
- In addition, it has also been reported in patients receiving organ transplants, elderly debilitated persons
- In India, few clusters of cases are reported so far. The first case of enteric microsporidiosis was reported in 2001 (Sehgal et al.) and ocular microsporidiosis was reported in 2003 (S. Sharma et al.)
- In a study done at PGI, Chandigarh (Saigal K. et al., 2012), Microsporidia were the most common parasites detected (15%) in the

**Table 8.3:** Clinical presentations of Microsporidia

<b>Various clinical presentations of Microsporidia</b>	
<b>Enteric infection</b>	
• Immunocompromised individuals:	<ul style="list-style-type: none"> <li>– Mainly caused by <i>Enterocytozoon bienersi</i> followed by <i>Encephalitozoon intestinalis</i> and <i>Encephalitozoon cuniculi</i></li> <li>– Patients are usually coinfectd with coccidian parasites like <i>Cryptosporidium</i>, <i>Isospora</i> and <i>Cyclospora</i></li> <li>– Common features are chronic diarrhea, malabsorption and wasting</li> </ul>
• Immunocompetent individuals:	<ul style="list-style-type: none"> <li>– <i>Enterocytozoon bienersi</i> and <i>Encephalitozoon intestinalis</i> have been reported as a cause of traveler's diarrhea</li> <li>– Infections in chronically debilitated elderly people</li> </ul>
<b>Ocular infection</b>	
• Immunocompromised individuals:	<ul style="list-style-type: none"> <li>– Involves conjunctival and corneal epithelium (epithelial keratopathy and conjunctivitis)</li> <li>– Agents: <i>Encephalitozoon cuniculi</i>, <i>E. hellem</i> and <i>Trachipleistophora hominis</i></li> </ul>
• Immunocompetent individuals:	<ul style="list-style-type: none"> <li>– Involves deep corneal stroma (stromal keratitis), may lead to corneal scar and ulcer</li> <li>– Agents: <i>Nosema oculorum</i>, <i>Vittaforma corneae</i>, <i>Microsporidium ceylonensis</i>, <i>Microsporidium africanum</i> and <i>Brachiola connori</i></li> </ul>
<b>Musculoskeletal infections</b>	
• Agents:	<i>Pleistophora</i> , <i>Brachiola vesicularum</i> and rarely <i>Trachipleistophora hominis</i>
• Features include	focal myositis with muscle weakness, myalgia and fever
<b>Disseminated infections</b>	
• <i>Enterocytozoon bienersi</i> :	Most common Microsporidia to involve multiple organs
• <i>Encephalitozoon intestinalis</i> :	Rhinitis, sinusitis, cholangitis, bronchitis
• <i>Encephalitozoon cuniculi</i> :	Hepatitis, peritonitis, renal infection (UTI)
• <i>Vittaforma corneae</i> and <i>Trachipleistophora hominis</i> :	UTI
• <i>B. connori</i> :	Smooth and cardiac muscle infection



**Figs 8.3A to D:** Microsporidia spores (A) Masson's trichrome stain; (B) acid fast stain shows red stained mature spores and blue unstained immature or degenerating spores; (C) duodenal biopsy (Giemsa stain) shows numerous spores inside the enterocyte (marked by arrows); (D) Calcofluor white stain shows oval fluorescing spores

Source: A, B and D- Sharma S et al. Indian J Med Microbiol. 2005; 23(2) 80–91 (with permission); C- Giovanni Swierczynski, Bruno Milanese. "Atlas of human intestinal protozoa Microscopic diagnosis" (with permission)

stool samples of HIV infected patients, *E. intestinalis* being the most common species.

#### Laboratory Diagnosis Microsporidiosis

- Light microscopy for the spore detection—by modified trichrome stain, modified acid fast stain, Gram stain (Brown-Brenn modification), Giemsa, PAS
- Fluorescence microscope—detects spores
- Electron microscopy—detects spores
- Cell culture—In Vero, RK13 and MRC-5 cell lines
- Antibody assays—IFA, ELISA, western blot
- Antigen assays—DAF
- Molecular methods—PCR
- In-situ hybridization

and appear red with darkly stained band at the tip (Fig. 8.3B)

- **Gram stain (Brown-Brenn modification):** Microsporidia spores stain gram positive
- **Other stains:** Giemsa stain (Fig. 8.3C), periodic acid Schiff stain (PAS) and Gram chromotrope stain can be used.

#### Fluorescence Microscope

Fluorochrome stain like Calcofluor white (Fig. 8.3D) and Uvitex 2B stain can be used.

#### Electron Microscopy

Transmission electron microscopy is considered as the **gold standard** method for the definitive diagnosis of microsporidiosis (Fig. 8.4).

- It is highly specific, but lacks sensitivity, time consuming, labor-intensive and expensive
- Microsporidia can be identified to the genus and species level based on ultra fine structure of the spores (number of coils in polar tubes), method of division and nature of the host cell parasite interface (whether grow directly or inside a parasitophorous vacuole).

#### Cell Culture

Microsporidia have been successfully cultivated in a number of mammalian cell lines including monkey and rabbit kidney cells (Vero and RK13), human fetal lung fibroblasts (MRC-5)

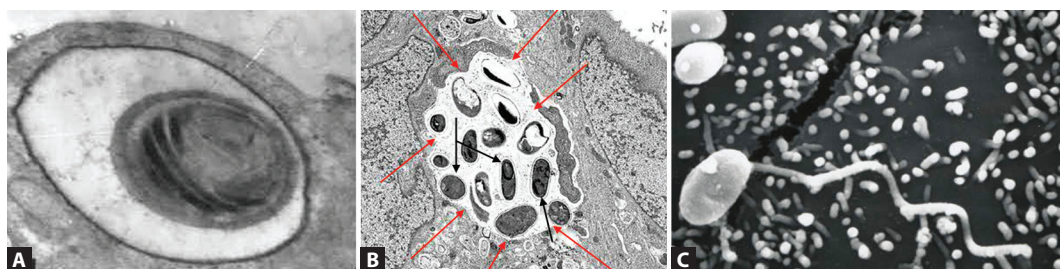
- Its use in routine clinical diagnosis is limited as it is time consuming and laborious

### Laboratory Diagnosis

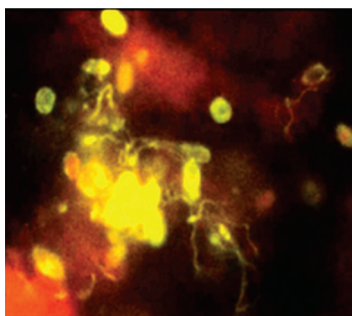
#### Light Microscopy for the Spore Detection

- **Samples:** Various samples can be collected like stool, small intestinal contents (collected by Entero-test) corneal smear or small intestinal biopsies, sputum, urine, etc
- **Modified trichrome stain (MTS):** It is the recommended stain for Microsporidia (Fig. 8.3A)
  - Microsporidia appear as red oval refractile spores against a blue background
  - Various modification of MTS are Weber green MTS, Ryan blue MTS and Kokoskin hot method of MTS
- **Modified acid fast stain (using 1% acid alcohol):** Microsporidia spores are acid fast





**Figs 8.4A to C:** (A) Transmission electron microscopic picture of Microsporidia spore depicting number of coils of the polar tube; (B) transmission electron micrograph of *Encephalitozoon intestinalis* depicting developing forms inside a parasitophorous vacuole (marked by red arrows) with mature spores (marked by black arrows); (C) scanning electron micrograph shows microsporidian spore with an extruded polar tubule inserted into a eukaryotic cell  
Source: A- Sharma S et al. Indian J Med Microbiol. 2005; 23(2) 80–91 (with permission); B and C- DPDx Image Library, Centre for Disease Control and prevention (CDC), Atlanta (with permission)



**Fig. 8.5:** Direct antibody fluorescent test showing fluorescing spores of microsporidia

Source: Sharma S et al. Indian J Med Microbiol. 2005; 23(2) 80–91 (with permission)

- However, it is useful for antigen preparation and drug susceptibility test.

## Serology

### Antibody assays

Various methods like immunofluorescence, immunoperoxidase, enzyme-linked immunosorbent assay (ELISA) and western blot are used to detect antibodies. They are not very useful as they lack specificity and give false positive results in unrelated infections

### Antigen assays

Direct antibody fluorescent test (DAF) is available for detecting the antigens on

Microsporidia spores by using fluorescent tagged monoclonal antibodies (Fig. 8.5).

## Molecular Methods

Several polymerase chain reaction (PCR) based methods have been developed, targeting different genes like small subunit and large subunit gene of ribosomal ribonucleic acid (rRNA) and intergenic spacer region (ISR) gene for diagnosis and speciation of Microsporidia infecting humans.

## In-situ Hybridization

In situ hybridization has been established for the detection of *E. bienersi* in humans by using probes directed against the small subunit rRNA of *E. bienersi*, present directly in the biopsies specimens.

It is time-consuming, not been described for other species and its sensitivity and specificity have not been evaluated.

## Treatment

- Albendazole is effective for the treatment of enteric, muscular and ocular microsporidiosis. It is given 400 mg twice daily for 2–4 weeks. Relapse may be seen in some cases.
- Other alternate drugs which are tried include:
  - › Octreotide
  - › Nitazoxanide

- Fumagillin
  - Thalidomide
- **Nutritional therapy:** To reduce malabsorption in case of enteric microsporidiosis
- Topical agents can be applied for the corneal lesions like topical itraconazole, metronidazole and topical propamidine
- Control of AIDS by antiretroviral therapy (ART) is important to reconstitute the immune system and to prevent remissions.

### BALANTIDIUM COLI

*Balantidium coli*, is the largest protozoan and the only ciliated parasite of humans.

Though it was observed by A.V. Leeuwenhoek earlier while examining a dysentery stool but the proper description was given later by Malmsten (Sweden) in man in 1856.

**Taxonomy:** It belongs to the Phylum Ciliophora, Class Litostomatea, Order Vestibuliferida and Family Balantidiidae.

**Habitat:** It resides in the large intestine of man, pig (main reservoir) and other animals.

### Morphology

It exists in two forms—(1) trophozoite (found in dysenteric stool) (2) cyst (found in carriers and chronic cases). Both the forms are binucleated having a large macronucleus and a small micronucleus.

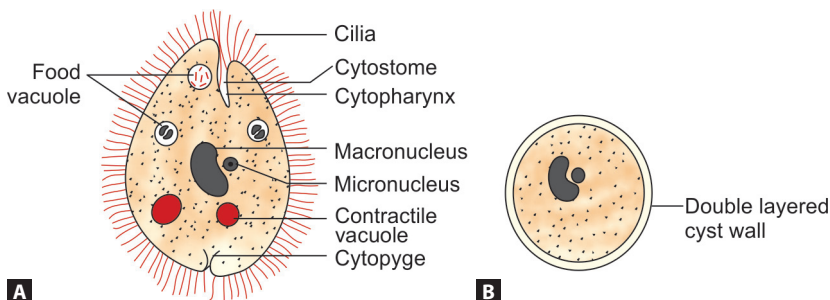
### Trophozoite

It is found in the active stage of the disease and considered as the invasive form.

- It is oval shaped, 30–300  $\mu\text{m}$  in length and 30–100  $\mu\text{m}$  in breadth
- The whole body is covered with a row of tiny delicate **cilia** (organ of locomotion)
- **Cilia** present near to the mouth part appear to be longer and called as “**adoral cilia**”
- Anterior end is narrow and the posterior end is broad
- Anterior end bears a groove (**peristome**) that leads to a mouth (**cytostome**) followed by a short funnel shaped gullet (**cytopharynx**) extending up to one-third of the body
- There is no anus (Fig. 8.6A)
- Posterior end is broad, round and bears an excretory opening called a **cytopyge**
- The cytoplasm is divided into outer clear ectoplasm and inner granular endoplasm
- The endoplasm contains:
  - **Two nuclei:** large kidney shaped macronucleus in the center and a small micronucleus lies in the concavity of the macronucleus
  - **Two contractile vacuoles:** lie side by side or one above the other. They maintain the proper osmotic pressure inside the cell
  - **Numerous food vacuoles:** It contains food particles like debris from host gut, bacteria, starch grains, fat droplets and occasional red blood cells (RBCs), etc. Digestion of the food particles takes place here.

### Cyst

It is round, measures 40–60  $\mu\text{m}$  in size, surr-



**Figs 8.6A and B:** Morphology of *Balantidium coli* (schematic diagram) (A) trophozoite; (B) cyst

ounded by a thick and transparent cyst wall.

- It also contains two nuclei (macronucleus and micronucleus) and vacuoles
- Cilia may be seen in younger cyst but on maturation, cilia are absorbed and movement ceases (Fig. 8.6B).

### Life Cycle (Fig. 8.7)

**Host:** Life cycle is completed in a **single host**.

- Pig is the **natural host**
- Man is the **accidental host**.

**Infective form:** Cyst

**Mode of transmission:** Man gets infection by ingestion of food and water contaminated with cysts.

### Development in Large Intestine

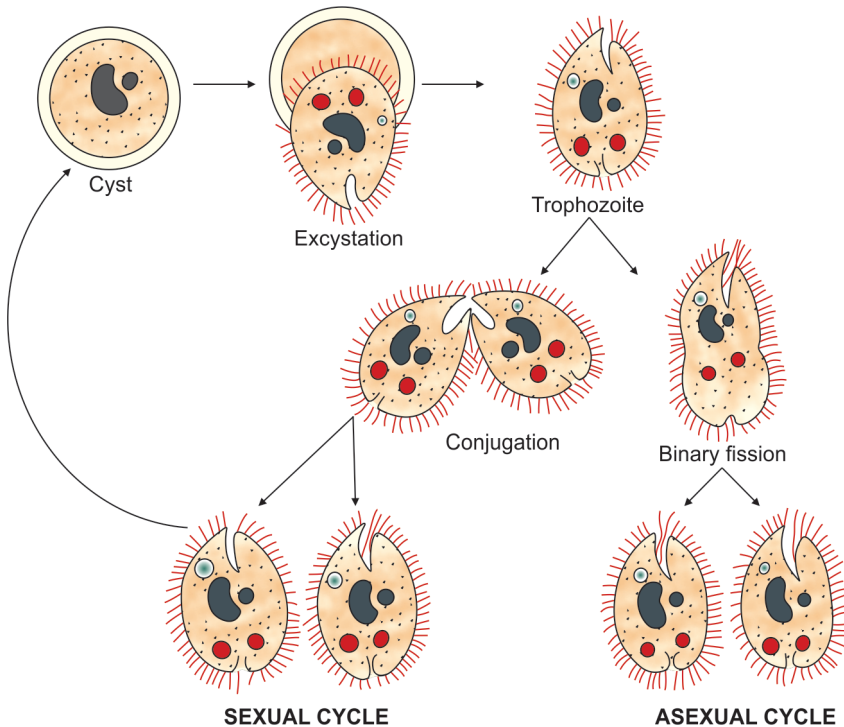
- **Excystation:** Probably occurs in the small intestine but multiplication takes place in the large intestine

- A single trophozoite is formed from each cyst
- Trophozoites are the feeding stage of the parasite; they multiply either in the gut lumen or enter the sub mucosa of the large intestine
- Trophozoites divide by both sexual and asexual methods:

➤ **Asexual reproduction:** Trophozoites divide by binary fission. Micronucleus divides first followed by the macronucleus and finally a transverse septum is formed that separates the cytoplasm into two halves (Fig. 8.7)

➤ **Sexual reproduction:** Trophozoites also replicate sexually (**syngamy**) by conjugation

- Two trophozoites come in contact with each other at their anterior ends and exchange the nuclear material for few moments after which they detach



**Fig. 8.7:** Life cycle of *Balantidium coli*

- There is no increase in numbers of trophozoites (Fig. 8.7)
- Both trophozoites and cysts are excreted in the feces
- Trophozoites disintegrate but the cysts are resistant and are infective to man and pig.

## Clinical Feature

### Asymptomatic Carriers

Majority of infections lead to asymptomatic carriers; they harbor the cysts and spread the infection.

### Chronic Disease

These patients have periods of increased bowel movements (mucoous or rarely bloody) with alternate periods of constipations. Organism load is less and requires repeated stool examination.

### Acute Disease

This stage is similar to acute amoebic dysentery:

- Trophozoites invade the gut submucosa and form multiple tiny superficial ulcers with necrotic base and undermined edge
- Microscopically, cluster of trophozoites are found in submucosa along with inflammatory cells (predominantly lymphocytic)
- Patients have frequent diarrhea with profuse mucus and blood. Other features include fever, nausea, vomiting and abdominal pain.

### Complications

Complications are seen in immunocompromised and malnourished people.

- These include perforation of the large intestine, involvement of appendix, peritonitis, severe dehydration leading to renal failure
- Extraintestinal manifestations may be rarely seen like liver abscess, pleuritis and pneumonia, etc.

### Epidemiology

*B. coli* is worldwide in distribution particularly

in tropical and subtropical countries where pig to human contact is more.

- Highest prevalence (20%) has been reported from the mountain districts of West Irian (Indonesia)
- So far only one outbreak of **balantidiasis** in humans is reported from Pacific Island of Truk in 1973
- In India, balantidiasis is quite rare.

### Laboratory Diagnosis

#### Balantidium coli

- Stool Examination—detects trophozoites and cysts
- Histopathology
- Culture

## Laboratory Diagnosis

### Stool Examination

Repeated stool examination should be done as the parasite is excreted intermittently.

- Trophozoites are detected in acute disease (dysenteric stool)
- Trophozoites are easy to identify by its rotatory motility, large size kidney shaped macronucleus and presence of cilia (Fig. 8.8A)
- Cysts are seen in chronic cases or carriers
- Cyst is round, measures 40–60  $\mu\text{m}$  in size, surrounded by a cyst wall and has two nuclei.

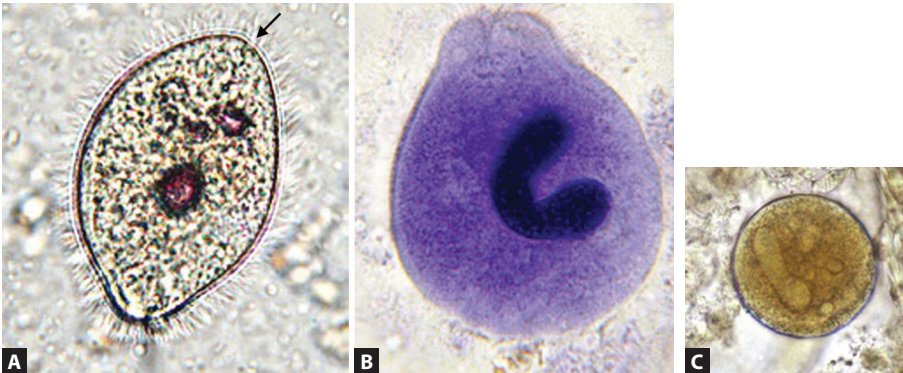
### Histopathology

Histopathological staining of the biopsy tissue or scrapping of the ulcers taken by sigmoidoscopy reveals cluster of trophozoites, cysts and lymphocytic infiltration found in submucosa (Figs 8.8B and C).

### Culture

The culture media like Boeck and Drbohlav egg serum media and Balamuth's media that support the growth of *Entamoeba histolytica* can be used for cultivation of *B. coli*. Culture is rarely necessary as the parasite is easily detected by stool microscopy or histopathology.





**Figs 8.8A to C:** *Balantidium coli* (A) saline wet mount preparation shows trophozoite with cilia; (B) Mayer's hematoxylin stain shows trophozoite with prominent macronucleus; (C) Iron hematoxylin stain shows cyst with prominent macronucleus

Source: Giovanni Swierczynski, Bruno Milanese "Atlas of human intestinal protozoa Microscopic diagnosis" (with permission)

## Prevention

**Balantidiasis** can be prevented by:

- Treatment of carriers shedding the cysts
- Hygienic rearing of pigs and prevention of pig to human contact
- Prevention of contamination of food or water with pig and human feces.

## BLASTOCYSTIS HOMINIS

### Habitat

*Blastocystis hominis* is single-celled anaerobic protozoan parasite resides in the gastrointestinal tract (GIT) of many animals including humans

It was considered as a commensal (most common commensal protozoa of GIT); however, recently its pathogenic role is described.

### Taxonomic Status

Taxonomic status was uncertain:

- It was initially described as harmless intestinal yeast due to its yeast-like glistening appearance
- Zierdt (1991) reclassified it under Sporozoa (based on presence of endoplasmic reticulum, Golgi complex, and mitochondrion and sensitivity to antiprotozoal drugs)

### Treatment

### Balantidium coli

- Tetracycline is the drug of choice. It is given 500 mg four times a day for 10 days
- Alternatively, metronidazole can be given. It is given 750 mg three times a day for 5–7 days
- No relapse or drug resistance is reported so far
- Treatment of carriers is also recommended to prevent the spread of the disease.

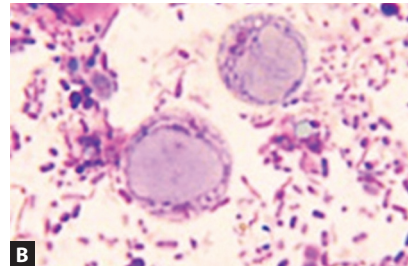
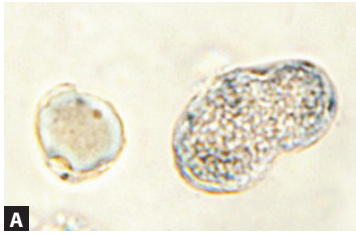
- Boreham (1996) had classified as amoeba (because of various morphological forms)
- Recently, according to Cavalier and Smith's six kingdom classification, *B. hominis* was placed under kingdom Chromista, subkingdom Chromobiota, infrakingdom Heterokonta (stramenopiles), phylum Bigyra and class Blastocystea.

### Pathogenicity

The pathogenicity of *Blastocystis* species is also debatable. Many still consider it as a gut commensal.

Common symptoms associated with the infection are diarrhea, nausea, abdominal cramps, flatulence, excessive gas and anal itching

Few cases of blastocystis infection appear to be associated with irritable bowel syndrome,



**Figs 8.9A and B:** *Blastocystis hominis* (A) saline mount shows left—vacuolar, right—granular form; (B) Giemsa stain shows two vacuolar form

Source: Giovanni Swierczynski, Bruno Milanese."Atlas of human intestinal protozoa Microscopic diagnosis" (with permission)

traveler's diarrhea and patients with AIDS.

### Laboratory Diagnosis

*B. hominis* shows great morphological variations. It occurs in four forms—(1) vacuolar, (2) granular, (3) amoeboid and (4) cystic.

- **Vacuolar form** is the most common form seen in fecal specimen and culture (Fig. 8.9).

It is 4–15  $\mu\text{m}$  size, spherical, having a central vacuole surrounded by thin cytoplasm and a nucleus.

- Granular forms are common in older cultures.

#### Treatment

#### Blastocystis hominis

- Metronidazole is found to be effective.

## EXPECTED QUESTIONS

### I. Write short notes on:

- Life cycle of Microsporidia
- Infection caused by Microsporidia
- Laboratory diagnosis of Microsporidia
- Balantidiasis
- Blastocystis hominis*

### II. Multiple choice questions (MCQs):

#### 1. Microsporidia spores are better stained by which of the following stain?

- Albert stain
- H and E stain
- Modified trichrome stain (MTS)
- Iodine stain

#### 2. Gold standard method for the diagnosis of Microsporidiosis?

- Electron microscopy
- Modified trichrome stain (MTS)
- Direct antibody fluorescent test (DAF)
- ELISA

#### 3. The main reservoir of *Blantidium coli*:

- Cattle
- Man
- Sheep
- Pig

#### 4. The largest protozoa parasitizing human intestine?

- Trichomonas hominis*
- Balantidium coli*
- Entamoeba coli*
- Isospora*

#### 5. Which of the following bears two nuclei named as macronucleus and micronucleus?

- Balantidium coli*
- Dientamoeba fragilis*
- Isospora*
- Entamoeba coli*

## Answer

1. c    2. a    3. d    4. b    5. a



# Section 3

---

## Helminthology

- Chapter 9** Introduction to Helminths
- Chapter 10** Cestodes
- Chapter 11** Trematodes or Flukes
- Chapter 12** Nematodes—I (Intestinal Nematodes)
- Chapter 13** Nematodes—II (Nematodes of Lower Animals that Rarely Infect Man)
- Chapter 14** Nematodes—III (Somatic Nematodes)



# 9 Introduction to Helminths

## Chapter Outline

- General characteristics
- Morphology
- Life cycle
- Expected questions

## GENERAL CHARACTERISTICS

Helminths are elongated flat or round worm like parasites measuring few millimeters to meters.

- They are eukaryotic multicellular and bilaterally symmetrical
- They belong to two phyla (Table 9.1)
  - Phylum Platyhelminths (flat worms)—it includes three classes:

**Table 9.1:** Differences between cestodes, trematodes and nematodes

Properties	Cestodes	Trematodes	Nematodes
Shape	Tape-like and segmented	Leaf-like and unsegmented	Elongated, cylindrical and unsegmented
Head end	Suckers present, some have attached hooklets	Suckers present No hooklets	No sucker, no hooklets. Some have well developed buccal capsule
Alimentary canal	Absent	Present but incomplete	Complete from mouth to anus
Body cavity	Absent	Absent	Present
Sexes	Monoecious	Monoecious (except schistosomes)	Diecious
Life cycle	Requires two hosts (except <i>Hymenolepis</i> and <i>Diphyllbothrium</i> )	Requires three hosts (except <i>Schistosoma</i> )	Requires one host (except filarial worms and <i>Dracunculus</i> )
Larva forms	Cysticercus, hydatid cyst, coenurus, cysticercoid, coracidium, plerocercoid and proceroid	Cercaria, metacercaria, redia, miracidium and sporocyst	Rhabditiform larva, filariform larva and microfilaria

- Class: Cestoidea (tapeworms)
- Class: Trematodea (flukes or digeneans)
- Class: Monogenea (ectoparasite of fishes, don't infect man)
- Phylum: Nemathelminths.

The classification of all the medically important helminths according to their habitat in man is depicted in Table 9.2.

## MORPHOLOGY

In general, helminths exist in three morphological forms—(1) adult form (or the worm), (2) larval form and (3) eggs.

### Adult Form

#### Phylum Platyhelminths

- Shape is tape like (in cestodes) or leaf like (in trematodes)
- They have a definite head end called as **suckers**
- They lack body cavity
- Alimentary canal is absent in cestodes but incomplete (rudimentary) in trematodes
- They are monoecious or hermaphrodite (i.e. both the sexes are present in the same worm), except in *Schistosoma* (diecious).

#### Phylum Nematoda

- They are evolutionary more developed than Platyhelminths
- They possess a definite body cavity (space between body wall and alimentary canal)
- Alimentary canal is completed starting from mouth leading to esophagus, intestine and ending at anus
- They are diecious, i.e. male and female worms are separate
- The nervous system and excretory system are rudimentary and there is no circulatory system.

### Larval form

There are various larval forms of helminths found in man and other hosts.

- **In cestodes:** Cysticercus, hydatid cyst, coenurus, cysticercoid, coracidium, proceroid and plerocercoid forms
- **In trematodes:** Cercaria, metacercaria, redia, miracidium and sporocyst
- **In nematodes:** Rhabditiform larva, filariform larva and microfilaria.

### Eggs

Based on their reproduction, helminths can be classified into the following:

**Table 9.2:** Classification of helminths based on habitat

Cestodes	Trematodes	Nematodes
<b>Intestinal cestodes</b> <ul style="list-style-type: none"> <li>• <i>Diphyllobothrium</i> spp.</li> <li>• <i>Taenia solium</i> and <i>Taenia saginata</i> causing intestinal taeniasis</li> <li>• <i>Hymenolepis</i> spp.</li> <li>• <i>Dipylidium</i> spp.</li> </ul>	<b>Blood trematodes</b> <ul style="list-style-type: none"> <li>• <i>Schistosoma</i></li> </ul> <b>Hepatic trematodes</b> <ul style="list-style-type: none"> <li>• <i>Fasciola hepatica</i></li> <li>• <i>Clonorchis</i> spp.</li> <li>• <i>Opisthorchis</i> spp.</li> </ul>	<b>Intestinal nematodes</b> <ul style="list-style-type: none"> <li>• <b>Large intestine</b> <ul style="list-style-type: none"> <li>– <i>Trichuris trichiura</i></li> <li>– <i>Enterobius vermicularis</i></li> </ul> </li> <li>• <b>Small intestine</b> <ul style="list-style-type: none"> <li>– <i>Ascaris lumbricoides</i></li> <li>– <i>Ancylostoma duodenale</i></li> <li>– <i>Necator americanus</i></li> </ul> </li> </ul>
<b>Somatic/tissue cestodes</b> <ul style="list-style-type: none"> <li>• <i>Taenia solium</i> causing cysticercosis</li> <li>• <i>Taenia multiceps</i></li> <li>• <i>Echinococcus</i> spp.</li> <li>• <i>Spirometra</i> spp.</li> </ul>	<b>Intestinal trematodes</b> <ul style="list-style-type: none"> <li>• <i>Fasciolopsis buski</i></li> <li>• <i>Heterophyes</i> spp.</li> <li>• <i>Metagonimus</i> spp.</li> <li>• <i>Watsonius</i> spp.</li> <li>• <i>Gastrodiscoides</i> spp.</li> </ul> <b>Lung trematodes</b> <ul style="list-style-type: none"> <li>• <i>Paragonimus westermani</i></li> </ul>	<b>Tissue Nematodes</b> <ul style="list-style-type: none"> <li>• Filarial worm <ul style="list-style-type: none"> <li>– <i>Wuchereria bancrofti</i></li> <li>– <i>Brugia malayi</i></li> <li>– <i>Loa loa</i></li> <li>– <i>Onchocerca</i> spp.</li> <li>– <i>Mansonella</i> spp.</li> </ul> </li> <li>• <i>Trichinella spiralis</i></li> <li>• <i>Dracunculus medinensis</i></li> </ul>

- **Oviparous:** Most of the helminths (cestodes, trematodes and many nematodes) are oviparous, i.e. after fertilization, the adult worm lay eggs
- **Viviparous:** Only few nematodes directly discharge the larval forms after fertilization (e.g. filarial worm, *Dracunculus* and *Trichinella*)
- **Ovoviviparous:** They lay egg containing larva that immediately hatches out (e.g. *Strongyloides*)
- Various helminths have distinct morphology of eggs which can be used to differentiate the helminths (**Details are discussed in the respective chapters**).

## LIFE CYCLE

Life cycle of helminths gets completed in one or more hosts.

- Cestodes complete their life cycle in two

hosts (definitive host and intermediate host) except *Hymenolepis* (requires only one host—man) and *Diphyllobothrium* requires three hosts (one definitive host—man, and two intermediate hosts—First, cyclops and second, fish)

- Most of the trematodes require three hosts (one definitive host—man, and two intermediate hosts—first snail and second aquatic plant or fish) except schistosomes (need two hosts, definitive host—man and intermediate host—snail)
- Nematodes complete their life cycle in one host (man) except filarial worms (need two hosts, definitive host—man and intermediate host—mosquito) and *Dracunculus* (need two hosts, definitive—host man and intermediate host—cyclops).

**Pathogenesis, clinical manifestations, epidemiology, laboratory diagnosis and treatment of various helminths are discussed in the respective chapters.**

## EXPECTED QUESTIONS

### I. Write short notes on:

- Various larval forms of helminths found in man
- List out general properties of nematodes

### II. Differentiate between:

- Cestodes and trematodes
- Trematodes and nematodes

# 10 Cestodes

## Chapter Outline

- General characteristics of cestodes
  - Classification of cestodes
  - Morphology of cestodes
- Pseudophyllidean cestodes
  - Diphylobothrium species
  - Spirometra species
- Cyclophyllidean cestodes
  - Taenia species
  - Echinococcus species
  - Hymenolepis nana
  - Dipylidium caninum
- Expected questions

## GENERAL CHARACTERISTICS OF CESTODES

### ■ CLASSIFICATION OF CESTODES

#### Systemic Classification

Cestodes belong to Phylum—Platyhelminths, Class Cestoidea and Subclass Eucestoda (Table 10.1).

**Table 10.1:** Classification of medically important Cestodes

Order	Family	Genus
Pseudophyllidea	Diphylobothriidae	<i>Diphylobothrium</i> <i>Spirometra</i>
Cyclophyllidea	Taeniidae	<i>Taenia</i> <i>Echinococcus</i>
	Hymenolepididae	<i>Hymenolepis</i>
	Dipylidiidae	<i>Dipylidium</i>

#### Classification Based on the Habitat of the Cestodes

##### Intestinal Cestodes

##### (Adult Worm Residing in Human Intestine)

- *Diphylobothrium* species
- *Taenia solium* and *Taenia saginata* causing intestinal taeniasis
- *Hymenolepis* species
- *Dipylidium* species.

##### Somatic/Tissue Cestodes

##### (Larvae in Human Muscles/Organs)

- *Taenia solium* causing cysticercosis
- *Taenia multiceps*
- *Echinococcus* species
- *Spirometra* species



## MORPHOLOGY OF CESTODES

In their life cycle, they exist in three morphological forms:

1. Adult worm
2. Egg
3. Larva

### Adult Worm

Adult worm is usually found in the intestine of men and animals (Fig. 10.1).

### Shape

Cestodes are long, segmented, flattened dorso-ventrally, tape like worms hence also called as tapeworms.

### Size

Cestodes vary from few milimeter to several meter. *Hymenolepis nana* is the smallest tapeworm (1–4 cm) where as *Diphyllobothrium* is the longest Cestode measuring 10 meters or more.

### Body Structure

Adult worm consists of three parts:

1. Head or scolex
2. Neck
3. Strobila (body or trunk).

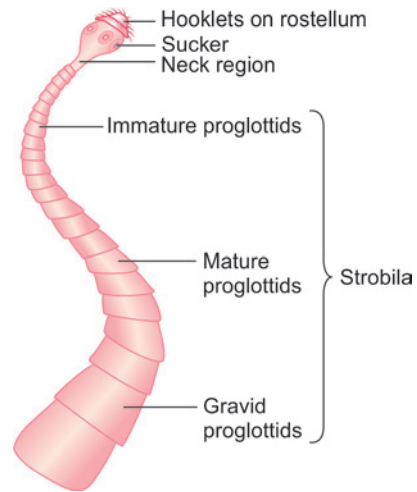
#### Head or scolex

It is the organ of attachment.

- In Cyclophyllidean cestodes, the scolex bear four cup like muscular suckers (or *acetabula*). In some species like *T. solium* and *H. nana*, scolex has a beak like apical protrusion called as **rostellum**, which may be armed with hooklets. (These species are called as **armed tapeworms**)
- In Pseudophyllidean cestodes, the scolex doesn't possess suckers but it bears a pair of longitudinal groove called as **bothria** by which it attaches to small intestine.

#### Neck

Next to head, the portion is called as **neck** from which the segments (proglottids) arise.



**Fig. 10.1:** Adult worm of cestode (schematic diagram)

### Strobila

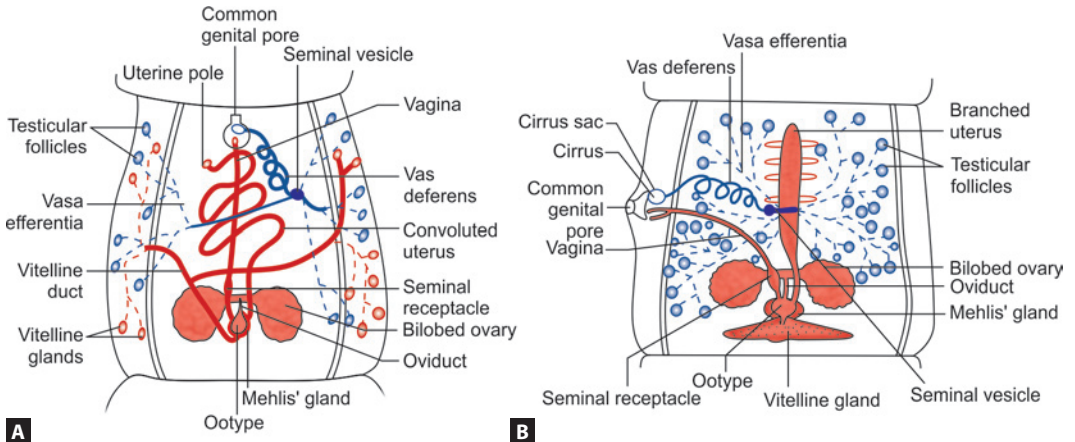
This is the body or trunk of the cestodes, which is surrounded by a body wall called as **tegument**.

- It consists of a number of segments (or proglottids). The length of the tapeworm varies based on the number of segments
- Proglottids bear the reproductive organs (both male and female); there are three types of proglottids—(1) immature, (2) mature and (3) gravid segments
  - **Immature segments:** Male and female reproductive organs are not differentiated
  - **Mature segments:** Contain male and female organs in the same segment, male organ appear first (Fig. 10.2)
  - **Gravid segments or fertilized segments:** Following fertilization, the uterus gets filled with eggs. Other organs are atrophied.

### Female Reproductive Organs

Present on the ventral side and consists of:

- **A bilobed ovary:** Present in the middle and posteriorly
- **Oviduct:** Arises from ovary, joins with spermatic duct and opens into the ootype



**Figs 10.2A and B:** Mature proglottids (schematic diagram) of (A) Pseudophyllidean cestodes, (B) Cyclophyllidean Cestodes

- **Ootype:** It is the chamber where fertilization takes place. There may be self fertilization or cross fertilization between the segments
- **Vagina:** A tube that connects genital pore to the ootype through which the sperm enters. At its inner end, it contains seminal receptacle (for storage of sperm) and spermatid duct
- **Uterus:** Straight tube arises from the ootype where the eggs are stored after fertilization in the gravid females. Its end may be opened (in pseudophyllideans) or closed as blind sac (in cyclophyllideans)
- **Vitelline gland (vitellaria) and Mehlis' gland** are present near the ootype. They occur as single mass (in cyclophyllideans) or scattered mass (in pseudophyllideans). They release their secretion through their ducts into the ootype.

### Male Genital Organs

Present on the dorsal side and consists of:

- **Testes:** They exist as multiple follicles (except in *Hymenolepis* which are three in number). Sperms are released to vasa efferentia which join together to form vas deferens
- **Vas deferens:** It is a convoluted tube, opens in the common genital pore. It bears a

seminal vesicle and ends in the common genital pore as a swollen muscular and protrusible organ called as **cirrus** (equivalent of penis) surrounded by a **cirrus sac**.

### Nervous System

It is rudimentary, consists of brain like structure (central ganglion, lateral and rostellar ganglia connected by central nerve ring) present in the scolex from which the longitudinal nerve trunks arise and pass through all the segments and joined by transverse nerves in each segment.

### Excretory System

It is also rudimentary and present in each segment. It consists of two lateral canals (dorsal and ventral) connected by transverse canals in each segment. The excretory canals are built up of **flame cells** (terminal cells) and **canal cells**.

### Circulatory System

There is no circulatory system and no body cavity.

### Body Wall (or Tegument)

It is made up of three layers—outer microvillus like structure called as **microtrichia**, middle

**basal plasma membrane** and inner **muscular layer** (outer circular and inner longitudinal muscle coats).

## Eggs

Eggs are released into the uterus following fertilization and fill the gravid proglottids (Fig. 10.3).

- **Pseudophyllidean cestodes:** Eggs are ovoid, operculated, surrounded by a single layer called as **egg shell** (or capsule), inside which the embryo is present containing hooklets (three pairs). Membrane lining the embryo is **ciliated**. The eggs when laid first in the feces, are not embryonated. Maturation takes place later in water (Fig. 10.3)
- **Cyclophyllidean cestodes:** Eggs are round to oval, covered by two layers—an outer egg shell (or capsule) filled with yolk material (thin, so might be lost) and an inner thick radially striated embryophore surrounding the embryo. Eggs are embryonated from the beginning, contains six hooklets but the lining membrane is not ciliated (Figs 10.3 B and C).

## Larva

Embryonated eggs undergo further development to form larva (Fig. 10.4).

- **Pseudophyllidean cestodes:** Larva is solid without any sac. They are:
  - › **Coracidium:** First stage larva of *Diphyllobothrium*
  - › **Proceroid:** Second stage larva of *Diphyllobothrium*
  - › **Plerocercoid:** Third stage larva of *Diphyllobothrium*
  - › **Sparganum:** Larval stage of *Spirometra*
- **Cyclophyllidean Cestodes:** Larvae contain bladder like sacs. They are:
  - › **Cysticercus:** Larval stage of *Taenia*
  - › **Hydatid cyst:** larval stage of *Echinococcus*
  - › **Coenurus:** Larval stage of *Multiceps*
  - › **Cysticercoid:** Larval stage of *Hymenolepis*.

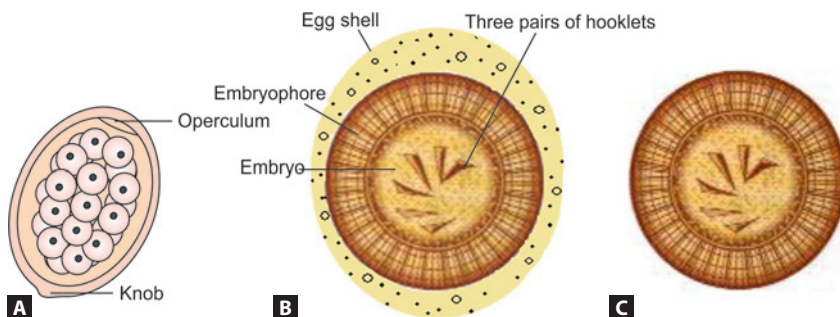
## Life Cycle

Cestodes complete their life cycle in two hosts (definitive host and intermediate host) except:

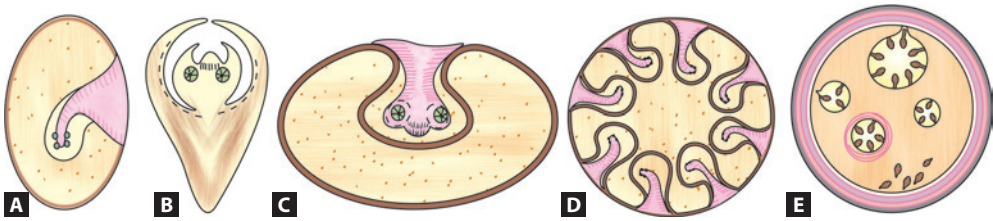
- *Hymenolepis* (requires only one host—man)
- *Diphyllobothrium* requires three hosts (one definitive host—man and two intermediate hosts—cyclops and fish).

Pathogenesis, clinical features, laboratory diagnosis and treatment of Cestodes are discussed in detail later individually.

Differences between pseudophyllidean cestodes and cyclophyllidean cestodes have been discussed in the Table 10.2.



**Figs 10.3A to C:** Eggs of Cestodes (A) Pseudophyllidean cestodes; (B) Cyclophyllidean cestodes; (C) Cyclophyllidean cestodes after the loss of egg shell



**Figs 10.4A to E:** Larvae of Cyclophyllidean cestodes: (A) cysticercus bovis; (B) cysticercoid (C) cysticercus cellulosae; (D) coenurus; (E) hydatid cyst

**PSEUDOPHYLLIDEAN CESTODES**

**DIPHYLLOBOTHRIUM SPECIES**

*Diphyllobothrium latum*, is the largest cestode found in human intestine

- It is also known as **fish tapeworm** or **human broad tapeworm** (proglottids are broader than longer, *latum* means broader)
- Its life cycle was described by Rosen in 1917
- Few species other than *D. latum* can rarely infect humans like *D. dendriticum*, *D. pacificum* and *D. nihonkaiense* etc.

**Classification**

*D. latum* belongs to the **Order-Pseudophyllidea** and **Family-Diphyllobothriidae** (Table 10.1).

**Epidemiology**

- *D. latum* is mainly endemic in temperate countries like Europe (Baltic countries like Russia and Finland), Japan, South America and Scandinavia
- **India:** *D. latum* is very rare in India. Three cases of diphyllobothriasis are reported so far from Southern India (Vellore 1998 and Pondicherry 2007, Karimnagar 2011).

**Habitat**

The adult worm of *D. latum* resides in the small intestine (jejunum and ileum) of humans.


**Morphology**

**Adult Worm**

*D. latum* is the **longest tapeworm** infecting man, measuring up to 10 meters or more with

**Table 10.2:** Differences between Pseudophyllidean cestodes and Cyclophyllidean cestodes

	<i>Pseudophyllidean cestodes</i>	<i>Cyclophyllidean cestodes</i>
Scolex	Bears two grooves (bothria)	Bears four suckers (Some species bear rostellum with hooklets)
Uterus	Convolutd (rosette shaped), un-branched, opens at the uterine pole	Branched and closed as a blind sac, No uterine pole
Genital pore	Situated ventrally in the midline	Situated laterally
Vitelline gland	Scattered throughout the segment	Single mass behind ovary
Eggs	Covered by one layer - egg shell Freshly passed eggs in feces are unembryonated. Eggs are operculated and the embryo is ciliated.	Covered by two layer—egg shell and embryophore Embryonated from the beginning Eggs are not operculated and the embryo is not ciliated.
Larval form	Solid	Contains bladder like sac



**Figs 10.5A to B:** Adult worm of *Diphyllbothrium latum* (A) scolex; (B) strobila

over 3,000 proglottids. It consists of head, neck and body (strobila).

### Head or scolex

It is spoon shaped, bears two longitudinal grooves called as **bothria** (one on ventral and other on dorsal surface) by which it attaches to the small intestine. There are no suckers and rostellum (Fig. 10.5A).

### Neck

It is situated next to scolex and represents the growing end, from which the proglottids arise. It is unsegmented and longer than the head.

### Strobila

- There are more than 3,000 segments divided into immature, mature and gravid segments (in that order starting from neck) (Fig. 10.5 B)
- The mature segment is broader (10–20 mm) than longer (2–4 mm) and contains the male and the female reproductive organs. Female organs consist of bilobed ovary, coiled and rosette shaped uterus, vitelline gland scattered throughout the segment and a vagina. Genital pore is situated mid-ventrally. Male organs consist of testes (follicles), vas deferens and cirrus (Fig. 10.2 A)
- **Gravid segment:** Uterus is filled with eggs which are discharged periodically through the uterine pole
- Some terminal gravid segments become shrunken and empty due to constant discharge of eggs and break off from the body and passed in the feces. (This is known as **pseudoapolyosis**).

### Eggs

- Fertilized eggs are oval, measuring 70  $\mu$ m length and 50  $\mu$ m width (Fig. 10.6)
- Eggs are operculated at one end and bear a knob at the other end (Fig. 10.3 A)
- When freshly passed in the feces, they are unembryonated, surrounded by egg shell
- Embryonated egg contains a hexacanth **oncosphere** lined by a ciliated membrane.

### Larva

There are three larval stages:

1. First stage larva (coracidium)
2. Second stage larva (proceroid)
3. Third stage larva (plerocercoid)

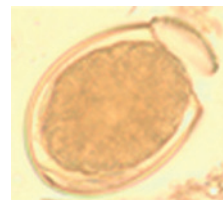### Life Cycle (Fig. 10.7)

**Host:** Humans are the definitive host. Dogs, cats and foxes are the other rare definitive hosts. There are two intermediate hosts:

1. **First intermediate hosts:** Fresh water copepods mainly of the genera *Cyclops* and *Diaptomus*
2. **Second intermediate hosts:** Fresh water fishes (pike, salmon, perch and trout)

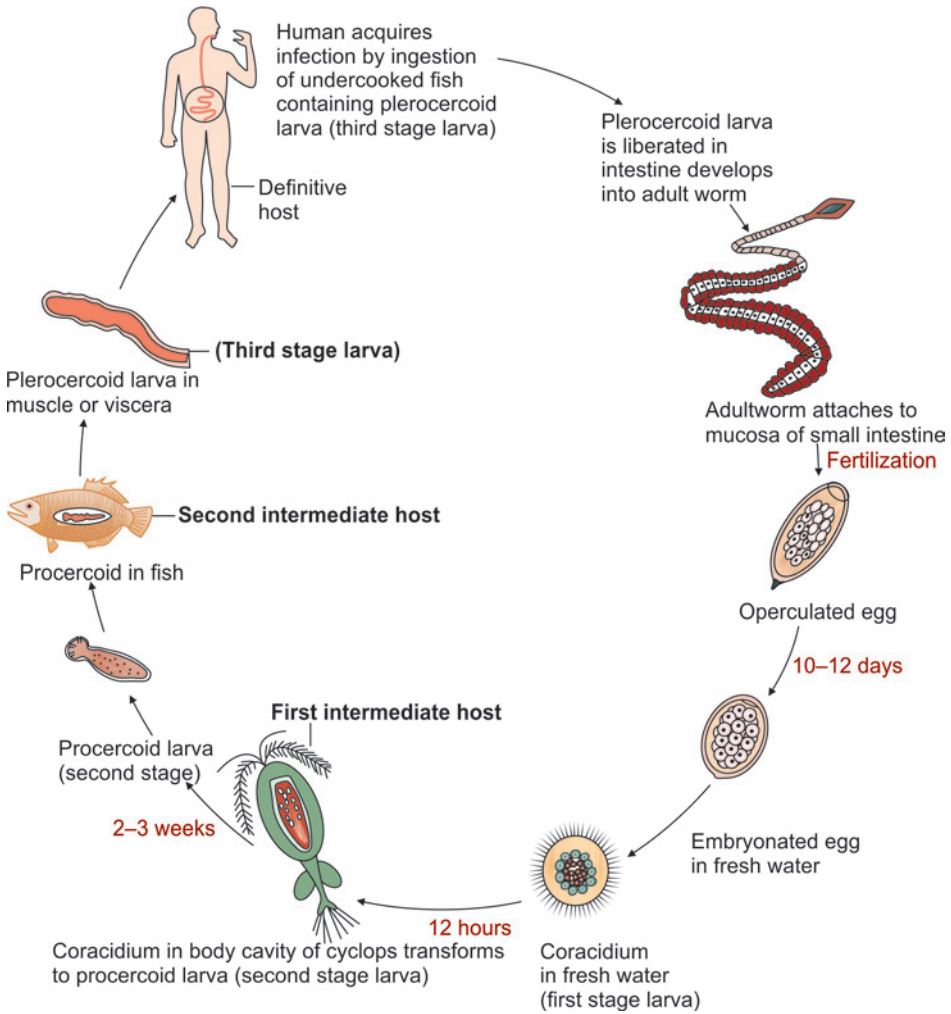
**Infective form:** Third stage plerocercoid larvae

**Modes of transmission:** Humans get infection by ingestion of undercooked fresh water fish containing third stage plerocercoid larva.



**Fig. 10.6:** Egg of *Diphyllbothrium latum*





**Fig. 10.7:** Life cycle of *Diphyllobothrium latum*

### Development in Definitive Host (Intestine)

The plerocercoid larvae undergo further development to form adult worms which attach to the small intestine by the help of bothria. Adult worms become sexually mature in 4 weeks, fertilization takes place and they begin to lay eggs. Millions of eggs are released every day (Fig. 10.7).

### Development in Fresh Water

- **Embryonation and formation of L1 larva (coracidium):** Eggs are unembryonated

when freshly passed in the feces, but become embryonated after 8-12 days in fresh water at 16-20°C. This ciliated embryo is released through the operculum of the egg into fresh water, which is known as the first stage larva (**coracidium**).

- **Development in first intermediate host ( $L_1$  to  $L_2$  transformation):** The coracidium swims in water and survives only for 12 hours within which it has to be ingested by small copepods (*Cyclops* and *Diaptomus*). It loses cilia and penetrates the intestine; enters the body cavity of copepods where

it transforms within 2–3 weeks into 0.5 mm long, second stage **proceroid larva** (infective stage to the fresh water fish)

- **Development in second intermediate host ( $L_2$  to  $L_3$  transformation):** The fresh water fishes are infected by ingestion of copepods containing proceroid larva. The proceroid penetrates the intestine of fish; migrate to muscle, liver and fat of the fish where it transforms within 1–2 weeks into an elongated 10–20 mm  $\times$  2–3 mm size,  $L_3$  stage (**plerocercoid larva**). This stage is infective to man and the cycle is repeated
- **Paratenic host:** If small fishes are eaten by a big suitable fish, then the plerocercoid penetrates the intestine of the bigger fish and survives without further development. This type of host is called as **paratenic host** (A host in which the parasite survives without any development and is not essential for its life cycle).

### Pathogenesis and Clinical Features

- Most of *D. latum* infections are asymptomatic.
- Minor manifestations may include abdominal discomfort, diarrhea, vomiting, weakness and weight loss or rarely acute abdominal pain and intestinal obstruction, **cholangitis** or **cholecystitis** (may be produced by migrating proglottids)
- **Vitamin  $B_{12}$  deficiency:** The adult worm absorbs large quantities of vitamin  $B_{12}$  and interferes with ileal  $B_{12}$  absorption
  - Vitamin  $B_{12}$  deficiency leads to development of **megaloblastic anemia** and some people may exhibit neurologic sequelae like paresthesia
  - This effect has been noted only in Scandinavia, where up to 2% of infected patients, especially the elderly, have megaloblastic anemia
  - Larger worms with close proximity to stomach can absorb more vitamin  $B_{12}$ .

#### Laboratory Diagnosis

*Diphyllobothrium latum*

- Stool examination—eggs and proglottids seen
- Blood examination shows megaloblastic anemia— $\uparrow$ MCV,  $\uparrow$ MCH, Macrocytes

### Laboratory Diagnosis

#### Stool Examination

The diagnosis is made readily by the detection of the:

- Characteristic eggs in the stool – surrounded by egg shell and an operculum at one end and a knob at the other end. (Fig. 10.6).
- Proglottids (with a characteristic coiled uterus) may be discharged in the stool.

#### Blood Examination

- Eosinophilia mild to moderate
- Evidence of megaloblastic anemia
  - Increased mean corpuscular volume (MCV > 95 fl)
  - Increased mean corpuscular hemoglobin (MCH)
  - Normal mean corpuscular hemoglobin concentration (MCHC = 32–36 g/dL)
  - Macrocytes (enlarged RBCs) are present.

#### Treatment

*Diphyllobothrium latum*

- Praziquantel (5–10 mg/kg once) is highly effective (drug of choice)
- Niclosamide is given alternatively
- Parenteral vitamin  $B_{12}$  should be given if  $B_{12}$  deficiency is manifested.

### Prevention

- Proper cooking of fish (10 minutes at 50°C)
- Deep freezing (–10°C for 24 hours)—for the people who eat raw fish.

### SPIROMETRA SPECIES

*Spirometra* and *Diphyllobothrium* species other than *D. latum* (that are not normal human parasites) can accidentally infect man



and cause a disease called as **sparganosis**.

- Disease is so named because; it is caused by the plerocercoid larva ( $L_3$  stage) of these parasites which is called as **sparganum**
- Genus *Spirometra* belongs to Diphylobothriidae family. Medically important members are *S. mansonoides*, *S. theileri* and *S. erinacei*.

### Life Cycle and Pathogenesis

**Host:** Its life cycle is similar to *D. latum*. Only hosts are different:

- **Definitive hosts:** Dogs and cats
- **First intermediate host:** Cyclops
- **Second intermediate host:** Frogs snakes and birds.

**Infective form:** Plerocercoid larva ( $L_3$  stage) called as sparganum.

**Mode of Transmission:** Man acts as an accidental host and gets infected by:

- Ingestion of undercooked reptiles and birds containing plerocercoid larva  $L_3$  (sparganum). Here, man acts as definitive host
- Or ingestion of cyclops containing proceroid larva ( $L_2$ ) which gets transformed into sparganum in human intestine. Here, man acts as second intermediate host
- Or by local application of raw infected flesh of any 2<sup>nd</sup> intermediate host as poultice containing sparganum. Here, man acts as definitive host.

### Sparganosis

Disease caused by sparganum larva is called as **sparganosis**.

- The sparganum ( $L_3$  larva) penetrates the intestinal wall and migrates to subcutaneous tissues, muscles, eyes and visceral organs like brain and lymphatics
- Here, the sparganum gets encysted to form painful fibrous nodules measuring 2 cm associated with pruritus and urticaria
- Ocular sparganosis is a serious manifestation and presented as painful edematous swelling of the eyelids (usually upper lids) with lacrimation and pruritus

- Lymphatic involvement can lead to elephantiasis
- **Aberrant sparganosis:** Caused by *Spirometra proliferum*. It is a rare tapeworm larva that grows by budding and continuous branching. The spargana are recovered from subcutaneous tissue, muscle, intestine wall, etc. The normal tissue organization is lost. The adult form of this parasite is not known.

### Epidemiology

Human sparganosis is rare. Cases are reported from China, Japan and Southeast Asia like Thailand and less often from America and Australia

In India, sparganosis is extremely rare. A case of cerebral sparganosis was reported from Hyderabad in 2003 and a case of sparganosis of kidney was reported from UP in 2011.

### Laboratory Diagnosis

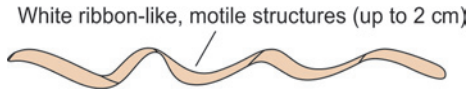
Diagnosis of sparganosis is made by surgical removal of the nodules and demonstration of the elongated worm like sparganum larva

- The sparganum is motile, elongated, white and opaque measuring few centimetres, resembles narrow tapeworm proglottids. (Fig. 10.8)
- It can be distinguished from other bladder like larval forms of tissue cestodes by absence of suckers and hooklets.

Treatment	Spirometra
<ul style="list-style-type: none"> <li>• Definite treatment is the surgical removal of the nodule</li> <li>• Drugs are not affective, however, praziquantel is recommended.</li> </ul>	

### Prevention

Human sparganosis can be prevented by filtering and boiling of drinking water, and eating the properly cooked flesh.



**Fig. 10.8:** Morphology of sparganum larva

## CYCLOPHYLLIDEAN CESTODES

### TAENIA SPECIES

*Taenia* species cause two types of manifestations in humans—**intestinal taeniasis** and **cysticercosis**.

#### Classification

*Taenia* belongs to Order: Cyclophyllidea, family Taeniidae (Table 10.1). Several species are known to infect man (Table 10.3).

- Two important members are:
  - *T. saginata* (also called as **beef tapeworm**) causes **intestinal taeniasis** in man
  - *T. solium* (also called as **pork tapeworm**) causes both **intestinal taeniasis** and **cysticercosis** in man.

#### History

Cysticercosis is an ancient disease, has also been described in ancient Indian medical book, the Charaka Samhita.

- It was first described in pigs by Aristophanes and Aristotle in third century BC, latter it was noticed in humans by Parunoli in 1550

- Neurocysticercosis was first reported in a coolie from Madras, died due to seizure (Armstrong 1888)
- In 1912, Krishnaswamy was the first to report the cases of muscle pains and subcutaneous nodules with abundant cysticerci in muscles, heart and brain through autopsy.

#### Habitat

The adult worms of *T. saginata* and *T. solium* reside in the small intestine (jejunum and ileum) of humans, where as the larva of *T. solium* (cysticercus cellulosae) reside and form cystic lesions in the muscle, brain and eyes.

#### Morphology

It exists in three forms—(1) adult worm, (2) egg and (3) larva.

#### Adult Worm

The adult worm consists of head (scolex), neck and strobila (body) (Figs 10.1 and 10.9).

- The description of the adult worm is similar to any cyclophyllidean cestodes (given in detail earlier)
- The important features of *T. saginata* and *T. solium* are slightly different to each other and are given in Table 10.4 and Fig. 10.10.

#### Head/scolex

The scolex bears four cup like muscular

**Table 10.3:** *Taenia* species infecting humans

<i>Taenia species</i>	<i>Definitive host</i>	<i>Intermediate host</i>	<i>Organ affected</i>	<i>Disease</i>
<i>T. saginata</i>	Man	Cattle	Intestine	Intestinal taeniasis
<i>T. solium</i>	Man	Pig	Intestine	Intestinal taeniasis
<i>T. solium</i>	Man	Man	Muscle, central nervous system (CNS) and eye	Cysticercosis
<i>T. saginata asiatica</i>	Man	Pig	Liver	Intestinal taeniasis
<i>T. multiceps</i>	Dog	Sheep and rarely man	CNS	Coenurosis

suckers (or acetabula) which helps in attachment (Figs 10.10 A and B).

- In *T. solium*, the scolex has a beak like apical protrusion called as **rostellum**. The rostellum is armed with two rows of hooklets (hence called as **armed tapeworm**).

### Neck

Situated next to the head. It is the narrow growing region from which the proglottids arise. Neck is longer in *T. saginata*.

### Strobila

Strobila is the trunk or body, consists of many segments (or proglottids). Segments are of three types—(1) immature, (2) mature and (3) gravid.


The mature segment contains the male and the female reproductive organs (Fig. 10.11).

Female organs consist of ovary, branched and closed uterus, ootype, single mass of vitelline gland and laterally situated genital pore. Male organs consist of testes (follicles), vas deferens and cirrus (Fig. 10.2B).

### Eggs

Following fertilization eggs are released into the uterus and fill the gravid proglottids.

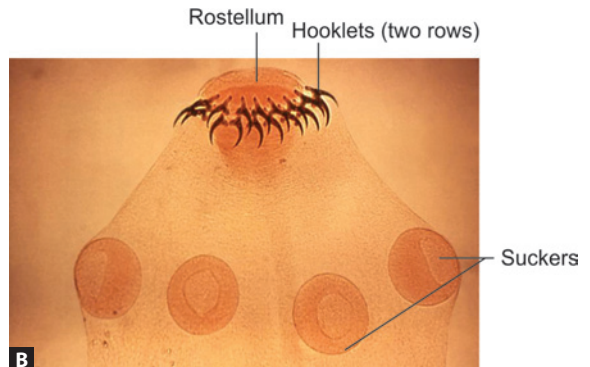
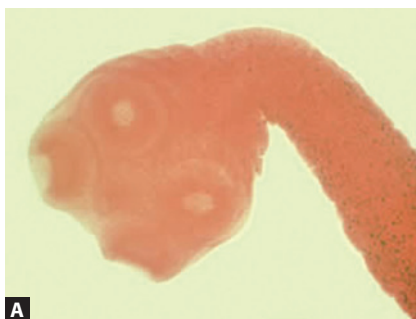- *Taenia* eggs are round, 30–40  $\mu\text{m}$  size, covered by two layers (Figs 10.3B,C and 10.12)



**Fig. 10.9:** Adult worm of *Taenia* spp.

Courtesy: HOD, Microbiology,  
Meenakshi medical college, Chennai

- An outer egg shell (or capsule) filled with yolk material (thin, so might be lost) and an inner embryophore (brown, thick walled and radially striated) surrounding the embryo
- The embryo or oncosphere contains three pair of hooklets
- Eggs of *T. saginata* and *T. solium* are indistinguishable from each other (except, *T. saginata* eggs are acid fast), and are infective to cattle and pigs respectively

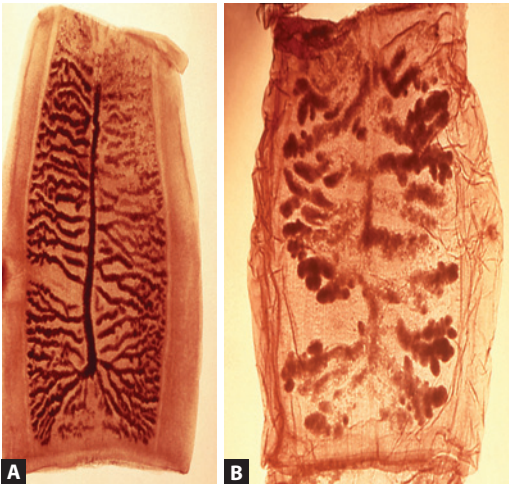


**Figs 10.10A and B:** Carmine stained scolex of (A) *T. saginata* and (B) *T. solium*

Source: A- DPDx Image Library, Centre for Disease Control and prevention (CDC), Atlanta (with permission); B- Public Health Image Library, ID#: 5262, Centre for Disease Control and prevention (CDC), Atlanta (with permission)

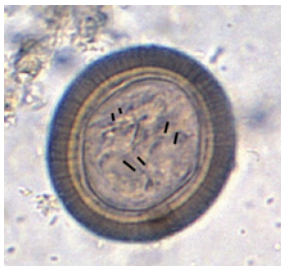**Table 10.4:** Differences between *Taenia saginata* and *Taenia solium*

Features	<i>Taenia saginata</i>	<i>Taenia solium</i>
<b>Adult worm</b>		
Length	4–6 meters or more	2–4 meters
Head/scolex	<ul style="list-style-type: none"> <li>• Large and quadrangular</li> <li>• Four suckers present which may be pigmented</li> <li>• No rostellum, No hooklets</li> </ul>	<ul style="list-style-type: none"> <li>• Small and globular</li> <li>• Four suckers present—not pigmented</li> <li>• Bears rostellum with two rows of hooklets</li> <li>• Hence called as armed tapeworm</li> </ul>
Neck	Longer	Shorter
<b>Proglottids</b>		
No. of Proglottids	1,000–2,000	800–1,000
Uterus	Bears in 15–20 lateral branches	Bears in 7–13 lateral branches
Lobes of Ovary	Two, No accessory lobe	Three—two lobes with an accessory lobe
Testes	300–400 follicles	150–200 follicles
Vaginal sphincter	Present	Absent
Measurement	Gravid segment—20mm × 5mm	Gravid segment—12mm × 6mm
Expulsion of segments	Expelled singly in the feces	Expelled in chain of 5–6 segments
Eggs per segment	80,000 eggs per gravid segment	40,000 eggs per gravid segment
<b>Larva</b>		
	Cysticercus bovis present in cattle's muscle, but not in man	Cysticercus cellulosae present in pig's muscle and also in man (muscle, eye and brain)
<b>Egg</b>		
	Acid fast	Non-acid fast
<b>Life cycle</b>		
Disease	Causes intestinal taeniasis	Causes intestinal taeniasis & cysticercosis
Host	Definitive host: Man Intermediate host: Cattle	For intestinal taeniasis- <ul style="list-style-type: none"> <li>• Definitive host: Man</li> <li>• Intermediate host: Pig</li> </ul> For Cysticercosis- <ul style="list-style-type: none"> <li>• Both definitive and intermediate host: Man</li> </ul>
Infective form	Larva (cysticercus bovis)	For intestinal taeniasis—Larva (cysticercus cellulosae) For cysticercosis—egg
Diagnostic form	Egg	For intestinal taeniasis—egg For cysticercosis—larva (cysticercus cellulosae deposited in tissue)
Mode of transmission	Ingestion of contaminated beef	For intestinal taeniasis—ingestion of contaminated pork For cysticercosis <ul style="list-style-type: none"> <li>• Contaminated food and water</li> <li>• Autoinfection</li> </ul>



**Figs 10.11A and B:** Carmine stained mature proglottids of (A) *T. saginata* and (B) *T. solium*

Source: A ID#: 10857, B ID#: 5262: Public Health Image Library, Centre for Disease Control and prevention (CDC), Atlanta (with permission)



**Fig. 10.12:** Egg of *Taenia* spp. in saline mount

Source: 10.12 Public Health Image Library, ID#: 906, Dr. Mae Melvin, Centre for Disease Control and prevention (CDC), Atlanta (with permission)

- Some time, eggs of *T. solium* are infective to man (to cause cysticercosis).

### Larva

Cysticercus is the larval stage of *Taenia*. It contains a muscular organ with bladder like sac. It is called as:

- Cysticercus cellulosae in *T. solium*
- Cysticercus bovis in *T. saginata*

Larval stage of *T. saginata* and *T. solium* is infective to man (to cause intestinal taeniasis).

### Life Cycle of *Taenia saginata* (Fig. 10.13)

**Host:** Men act as the **definitive** and cattle serve as the **intermediate host**.

**Infective stage:** Cysticercus bovis (larval stage) is the infective stage to men while eggs are infective to cattle.

### The Human Cycle

**Mode of transmission:** Man acquires the infection by ingestion of undercooked beef containing encysted larval stage (cysticercus bovis).

**Larva transforms to adult:** The larva hatch out in small intestine, the scolices evaginate and anchor to the intestinal wall by suckers and gradually develop into the adult worms.

- Adult worms become sexually mature in 10–14 weeks, fertilization occurs (self or cross fertilization within the segments) and eggs are formed & later released to the feces. Eggs are infective to cattle
- Sometime, the older gravid segments break off and are released in the feces. They are quite mobile and migrate in the feces.

### The Cattle Cycle

**Mode of transmission:** Eggs are ingested by cows and buffaloes while grazing the field.

**Eggs transform to larvae:** In the duodenum, the embryophore surrounding the egg ruptures, releasing the oncosphere. With the help of hooklets, the oncospheres penetrate the intestine, and reach the skeletal muscle via blood where they transform into bladder like larvae (cysticercus bovis) which get encysted and deposited as cysts. This takes 10–15 weeks of time.

**Cysticercus bovis:** Small 6–9 mm, round, grayish white bladder like worm containing opaque invaginated scolex without hooklets (Fig. 10.13).

### Life Cycle of *Taenia solium* (Fig. 10.14)

Life cycle of *T. solium* depends on the disease it causes.

When it causes intestinal taeniasis, the life cycle is exactly similar to that of *T. saginata* except:

- The intermediate host is pig (hence called as pork tapeworm)
- Men harboring the adult worm excrete the eggs in feces which can infect the same individual by autoinfection
- In pigs, the development time is shorter (7–9 weeks).

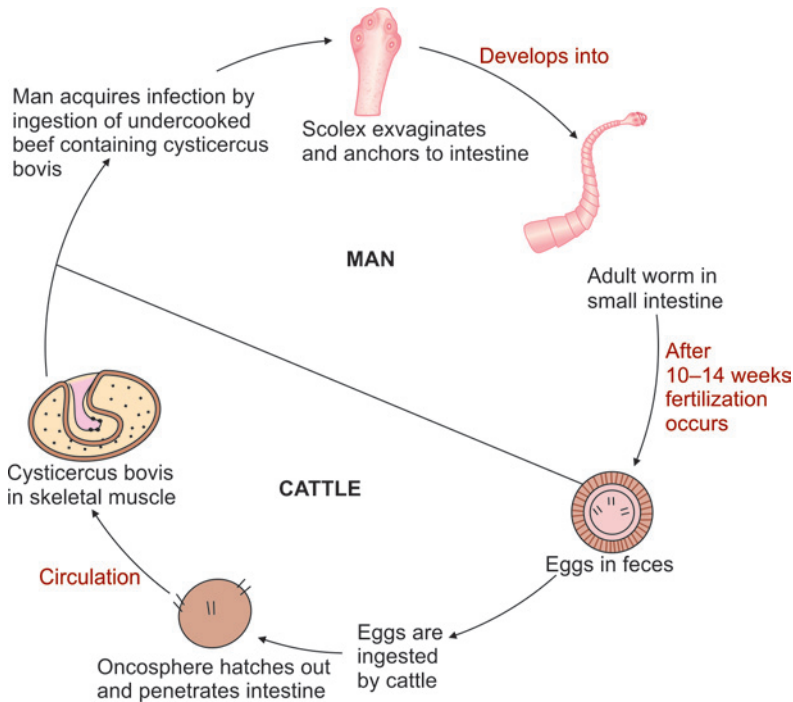
But when it causes cysticercosis, the life cycle is different and given as below:

- **Host:** Man acts as both **definitive** and **intermediate** host.
- **Infective stage:** Eggs of *T. solium*.
- **Mode of transmission:** Firstly man acquire the infection by—(1) ingestion of contaminated food or water with eggs of *T. solium* and (2) autoinfection.

**Autoinfection:** Eggs excreted from men reinfect the same individual. Autoinfection can be of two types:

- **External autoinfection:** Due to unhygienic personal habit, e.g., contaminated finger
- **Internal autoinfection:** Due to reverse peristaltic movements by which the gravid segments throw the eggs back into the stomach (equivalent to swallowing of the eggs)

- **Further life cycle in men is similar to that in pigs:** Oncosphere is released from the eggs, penetrates the intestine and enters into the portal circulation or mesenteric lymphatics and reaches to various organs like subcutaneous tissue, muscle, eye and brain where it is transformed to the larval stage cysticercus cellulosae in 7–9 weeks and deposited as cyst. Full develop-



**Fig. 10.13:** Life cycle of *Taenia saginata*



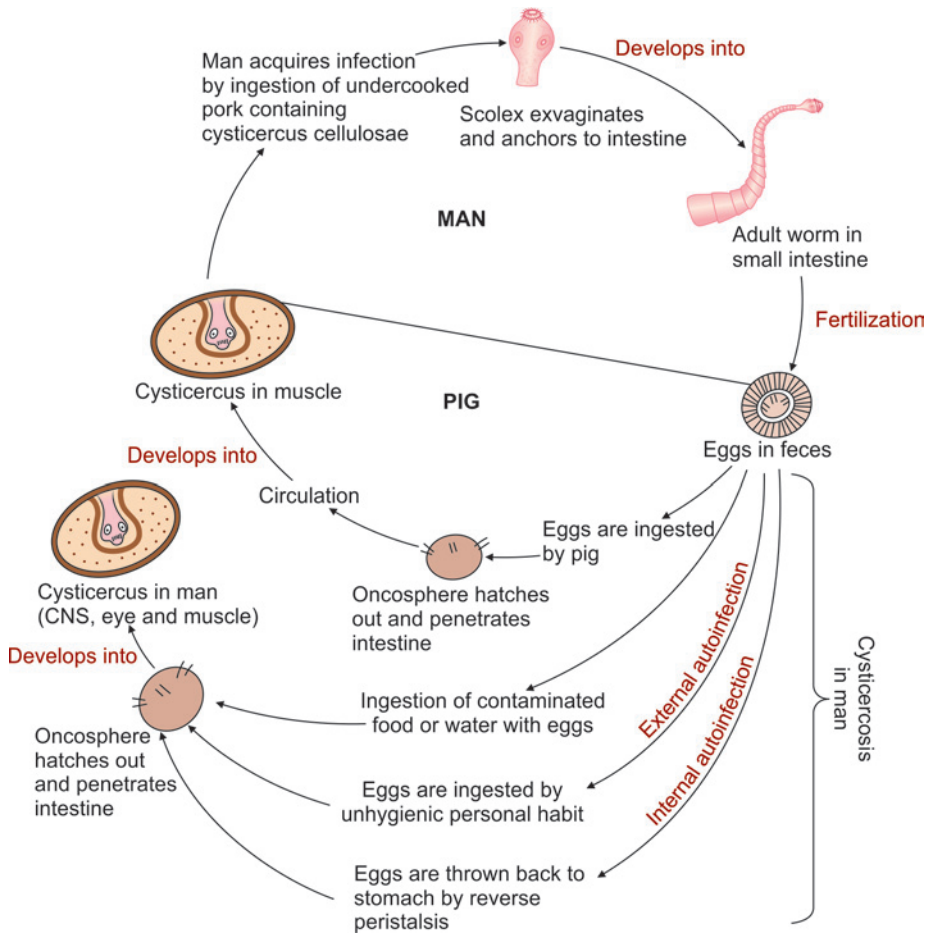


Fig. 10.14: Life cycle of *Taenia solium*

ment to mature cysts takes 2–3 months of time.

- Cysticercus cellulosa:** A mature *cysticercus cellulosa* is 0.5–1.5 cm size, spherical (or slightly oval), yellowish white, separated from the host tissue by a thin collagenous capsule (Fig. 10.15)
  - It contains two chambers:** Outer one is a bladder like sac filled with 0.5 mL of vesicular fluid and the inner chamber contains the growing scolex with hooklets and a spiral canal (Fig. 10.4C)
  - Racemose cysticerci:** In some cases, when the parasites are lodged in

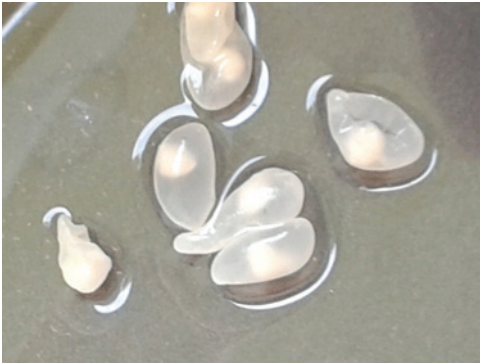spacious area, they grow and transform into larger lobulated cysticerci (> 20 cm), containing 60 mL of vesicular fluid.

## Pathogenesis and Clinical Features

### Intestinal Taeniasis

Both *T. saginata* and *T. solium* can cause intestinal taeniasis.

- Often, it is asymptomatic; patients become aware of the infection most commonly by noting the passage of proglottids in their feces
- The proglottids are often motile, and patients may experience perianal discomfort (or



**Fig. 10.15:** *Cysticercus cellulosae* (surgically removed)  
 Courtesy: HOD, Microbiology, Meenakshi medical college,  
 Chennai (with permission)

pruritus) when proglottids are discharged

- Mild abdominal pain or discomfort, nausea, loss of appetite, weakness, weight loss, headache and change in bowel habit (constipation or diarrhea) can occur
- Occasionally obstruction by the migrating proglottids can result in appendicitis or cholangitis.

### Cysticercosis

Clinical spectra of the disease depend upon the localization of the cyst. Though it is discovered from any site of the body but the common sites are central nervous system (CNS), subcutaneous tissue, skeletal muscle and eyes.

- **Subcutaneous cysticercosis:** It is frequently asymptomatic but may manifest as palpable nodules
- **Muscular cysticercosis:** Manifest as muscular pain, weakness or pseudohypertrophy
- **Ocular cysticercosis:** Can involve eye lids, conjunctiva and sclera. Common symptoms like proptosis, diplopia, loss of vision and slow growing nodule with focal inflammation
- Neurocysticercosis (NCC).

### Neurocysticercosis

- NCC is the most common form and accounts for 60–90% cases of cysticercosis

- NCC is considered as the most common parasitic CNS infection of man and the most common cause of adult onset epilepsy throughout the world

- Based on the site of involvement, NCC is of two types:

1. **Parenchymal:** Involves brain parenchyma

2. **Extraparenchymal** sites are meninges, ventricles and spinal cord

Though brain parenchyma was thought to be the most common site but recent evidences have shown that **subarachnoid space** being the most common site, followed by brain parenchyma

- **Asymptomatic neurocysticercosis (NCC):** Sometimes NCC remains in the brain without causing any apparent symptoms

- **Manifestations:** Seizure is the most common manifestation (70% of cases). NCC accounts for 50% cases of late onset epilepsy  
 Other features include:

- › Hydrocephalus (most common extraparenchymal feature)
- › Increased intracranial pressure and hypertension- presented as headache, vomiting and vertigo
- › Chronic meningitis
- › Focal neurological deficits
- › Psychological disorders and dementia

- **NCC exists in four morphological stages:** It starts as vesicular form, gradually develops into necrotic, followed by nodular and finally into calcified stage

- The clinical presentation is variable and depends on number, location & size of the cyst, the morphological stage of the cyst and the host immune response.

### Epidemiology

#### *Taenia saginata* Infection

The *T. saginata* infection is common in cattle breeding areas of the world.

The areas with the highest prevalence (up to 27%) include Central Asia, Central and East Africa.

### Taenia solium Infection

#### World

Cysticercosis is a major public health problem, especially in the developing world.

- *T. solium* infection is endemic includes Mexico, Central America, South America, Africa, Southeast Asia, India, Philippines, and Southern Europe
- NCC is considered as the most common parasitic CNS infection of man and the most common cause of adult onset epilepsy throughout the world accounting for 50% cases of late onset epilepsy
- However, it is reported less from the Muslim countries (as pork eating is not allowed).

#### India

- Previously it was under reported, accounting for 2–3% of epileptic cases in places like NIMHANS, Bangalore (2%) and Delhi (2.5%). This was because of lack of systematic population based studies and unavailability of imaging techniques.
- Recent studies [with the help of computed tomography (CT) and magnetic resonance imaging (MRI)] suggested the disease burden in India is more and varies from 18% to 31% of suspected cases of epilepsy
- It appears to be more prevalent in various places like Bangalore, Vellore, Bihar, Uttar Pradesh, Pondicherry and Chandigarh.

### Laboratory Diagnosis

#### Laboratory Diagnosis Intestinal taeniasis

- Stool examination—Detects eggs, proglottids
- *Taenia* specific coproantigen detection in stool—ELISA
- Antibody detection in serum—ELISA, CFT, Immunoblot
- Molecular method—PCR

### Intestinal taeniasis

#### Stool examination

Demonstration of characteristic eggs and less often proglottids of *Taenia* can be done by direct smear.

- Multiple stool examination and concentration techniques (formol ether sedimentation) can be followed to increase the detection rate
- Anal swabs (cellophane swabs used for *Enterobius*) can be used to collect faecal matter and is superior for detection of eggs than stool
- **Eggs** of *T. saginata* and *T. solium* are morphologically similar except that eggs of *T. saginata* are acid fast. Egg consists of an oncosphere with six hooklets surrounded by an embryophore
- **Proglottids** of *T. saginata* and *T. solium* can be differentiated by lateral branches in uterus, accessory lobe in ovary, vaginal sphincter and expulsion of segments (singly or in chain) (Table 10.4)
- **Scolex** can be detected in feces very rarely. *T. solium* scolex is armed with rostellum and hooklets.

#### Taenia specific antigen detection in stool

Enzyme-linked immunosorbent assay (ELISA) has been developed to detect *Taenia* specific antigen (coproantigen) in stool by using polyclonal *Taenia* antibodies. This test has many utilities:

- Claims more sensitive than stool examination
- Can detect *Taenia* carriers

However, it cannot differentiate between *T. saginata* and *T. solium*.

#### Antibody detection in serum

Various methods like precipitation, agglutination, complement fixation and ELISA have been carried out using different antigen preparation

- Antibody methods show variable results and cannot differentiate between present and past infection
- Recently, Immunoblot is developed for *T. solium* specific antibodies and claims 95% sensitive and 100% specific.

#### Molecular methods

Both DNA probe and polymerase chain reaction (PCR) have been developed to

differentiate *T. saginata* and *T. solium* by using specific primers.

- It can also differentiate the two subspecies *T. saginata saginata* and *T. saginata asiatica* based on mitochondrial DNA
- The two genotypes of *T. solium* can also be differentiated, one found in Asia and other in Africa and Latin America.

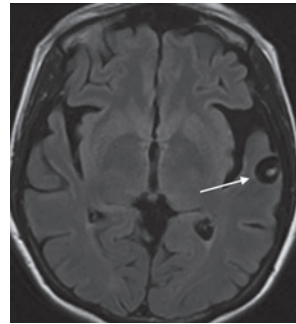
### Laboratory Diagnosis Cysticercosis

- Radiodiagnosis—CT scan and MRI
- Antibody detection in serum or CSF—ELISA, Western blot (EITB)
- Antigen detection in serum or CSF—ELISA
- Lymphocyte transformation test
- Histopathology of muscles, eyes, subcutaneous tissues or brain biopsies
- Del brutto diagnostic criteria

## Cysticercosis

### Radiodiagnosis (imaging methods)

- CT scan and MRI are the two important imaging methods used to detect cysticerci in brain
- Because of the vesicular structure, live cysticerci appear hypodense (low signal intensity) area and the scolex is present eccentric inside the vesicle and gives a hyperdense (high signal intensity) area
- Imaging methods are useful to identify:
  - The number of cyst (single or multiple cysticerci)
  - Location of the cyst (parenchymal or extraparenchymal)
  - Size of the cyst (small—cysticercus cellulosae and big cyst—cysticercus racemosus)
  - The stage of the disease (vesicular, necrotic, nodular and calcified)
  - Extent of the lesion
  - Active or dormant lesion: Associated inflammation and edema gives a ring like enhancement surrounding the cysts, indicates acute infection
- CT scan is useful to detect calcified cysts (appears as hyperdense dots)



**Fig. 10.16:** MRI of brain—arrow shows cystic lesion of neurocysticercosis in subarachnoid space

- MRI has a higher contrast resolution, which makes lesion clearer (Fig. 10.16). It is superior than CT scan to detect the:
  - Extraparenchymal cysts in ventricle and cisterns
  - Inflammatory changes
  - Vesicular and necrotic lesions
  - Noncystic lesions.

### Immunodiagnosis

It has the advantage of lower cost than CT and MRI and confirms the etiology.

#### 1. Antibody detection

**ELISA:** ELISA detects antibodies in serum and cerebrospinal fluid (CSF) by using crude extract of cysticerci or vesicular fluid.

- It is highly sensitive (75%–90%) in serum. CSF, ELISA also gives better results
- Moreover, recent ELISA methods using purified glycoprotein antigens have shown better sensitivity but its specificity is low as it gives false positive results in cross reacting helminthic infections.

**Western blot:** Western blot assay [also called as enzyme immune transfer blot (EITB)] uses highly specific lentil lectin purified seven glycoprotein (LL-Gp) antigenic fractions; hence its specificity approaches 100%.

- Presence of one to seven Gp bands confirms the diagnosis
- The sensitivity is related to the number of cysticerci in the brain—98% sensitivity with

more than three cysticerci, while only 65% sensitivity with 1–2 lesions (especially in children)

- It is more likely to be positive in serum than CSF samples.

However, antibody methods have disadvantages—(1) Cannot differentiate active and past infection, (2) Antibodies persist even after recovery of the patient.

## 2. Antigen detection

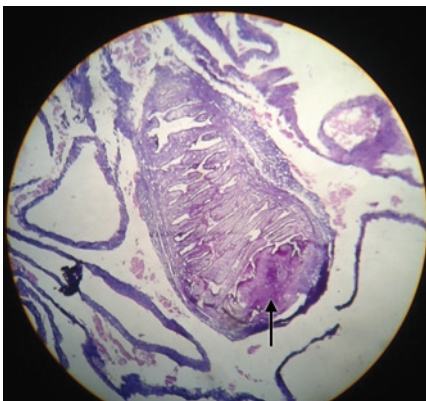
Antigen detection in CSF or serum by ELISA has been developed using monoclonal *T. solium* antibodies. Antigen disappears following treatment hence, can be used for monitoring.

## Lymphocyte transformation test

It is based on the transformation of the lymphocytes when subjected to *T. solium* cyst fluid antigens and showed sensitivity of 93.7% and specificity of 96.2%.

## Histopathology

Cysticerci can be detected in muscles, eyes, subcutaneous tissues (or brain during postmortem) by biopsy following surgical removal or fine needle aspiration of the cyst



**Fig. 10.17:** *Cysticercus cellulosae* in biopsy from the brain (hematoxylin and eosin stain) An entire cysticercus seen within the bladder walls, [Parenchymatous portion of the cysticercus can be better observed. The extensive folding of the spiral canal and one sucker of the scolex (Arrow)]

Courtesy: HOD, Pathology, Meenakshi medical College, Chennai

**Table 10.5:** Del brutto's Diagnostic Criteria for Human Cysticercosis

<b>Absolute criteria</b>
• Histology of tissue biopsy to detect cysticerci
• Visualization of the parasite in the eye by fundoscopy
• CT/MRI of brain- Detects lesions confirmatory of NCC (cysts with characteristic scolex)
<b>Major criteria</b>
• CT/MRI of brain- Detects lesions suggestive of NCC
• Serum/CSF antibody detection by western blot
• Resolution of lesions after albendazole or praziquantel treatment
<b>Minor criteria</b>
• CT/MRI of brain- Detects lesions compatible with NCC
• Clinical manifestations suggestive of NCC
• Serum/CSF antibody detection by ELISA
• Evidence of cysticercosis outside the CNS (e.g., cigar-shaped soft-tissue calcifications)
<b>Epidemiologic criteria</b>
• Residing in endemic area
• Frequent travel to endemic area
• History of contact with another patient with NCC

followed by microscopic demonstration of the parasite (Fig. 10.17).

## Del brutto diagnostic criteria

This has been proposed for the diagnosis of NCC in endemic countries. It is based on clinical, imaging, immunological and epidemiological data (Table 10.5).

- Confirmed diagnosis
  - One absolute criterion or
  - Two major criteria + one minor criterion + one epidemiologic criterion
- Probable diagnosis
  - One major criterion + two minor criteria or
  - One major criterion + one minor criterion + one epidemiologic criterion; or



- Three minor criteria + one epidemiologic criterion

Treatment	Intestinal taeniasis
<ul style="list-style-type: none"> <li>• <b>Praziquantel (drug of choice):</b> Single dose of (10 mg/kg) is highly effective</li> <li>• Niclosamide (2 g) is also effective but is not widely available.</li> </ul>	

Treatment	Cysticercosis
<p><b>Antiparasitic agents:</b></p> <ul style="list-style-type: none"> <li>• For brain parenchymal lesions: <ul style="list-style-type: none"> <li>➤ Albendazole (15 mg/kg per day for 8–28 days) or</li> <li>➤ Praziquantel (50–100 mg/kg daily in three divided doses for 15–30 days)</li> </ul> </li> <li>• Longer courses are often needed in patients with multiple subarachnoid cysticerci</li> </ul> <p><b>Symptomatic treatment of:</b></p> <ul style="list-style-type: none"> <li>• Seizures by antiepileptic drugs</li> <li>• High-dose glucocorticoids should be used to reduce the inflammatory reactions caused by dead cysticerci</li> <li>• Hydrocephalus: Attempts should be made to reduce intracranial pressure. In the case of obstructive hydrocephalus, cysticerci can be removed by endoscopic surgery or ventriculoperitoneal shunting.</li> </ul> <p><b>Surgery:</b></p> <ul style="list-style-type: none"> <li>• Open craniotomy to remove cysticerci is rarely required nowadays</li> <li>• Surgery is indicated for ocular and spinal and ventricular lesions because anti parasitic drugs can provoke irreversible inflammatory damage.</li> </ul>	

## Prevention

Intestinal taeniasis can be prevented by:

- Adequate cooking of beef or pork viscera:
  - Exposure to temperatures as low as 56°C for 5 minutes
  - Refrigeration or salting for long periods or freezing at –10°C for 9 days

- Effective fecal disposal to prevent infection to cattle and pigs.

The prevention of cysticercosis involves:

- Good personal hygiene to prevent auto-infection with eggs
- Effective fecal disposal to prevent contamination of food and water with eggs
- Treatment and prevention of human intestinal infections
- Vaccines to prevent porcine cysticercosis. Various antigens like *T. solium* oncosphere antigen, *T. crassiceps* and *T. ovis* recombinant antigens are attempted for vaccination of pigs. They are under development.

## OTHER TAENIA SPECIES

### Taenia saginata asiatica (Asian Tapeworm)

Some authors still regard it as a separate species where as others consider it as a subspecies of *T. saginata* due to similarities of the DNA sequences.

- It is morphologically similar to *T. saginata* except:
  - Intermediate host is pig (not in cow)
  - Cysticerci are located primarily in liver (not in muscle)
  - Scolex in cysticerci bears hooklets (may be lost in mature worms)
  - Both the cysticerci and the adult worm are smaller (with 300–1,000 proglottids)
- It is found mainly in Taiwan and other Asian countries like Korea, China, Malaysia, Thailand but not reported in India, yet
- Clinical features, diagnosis and treatment are similar to that of *T. saginata*.

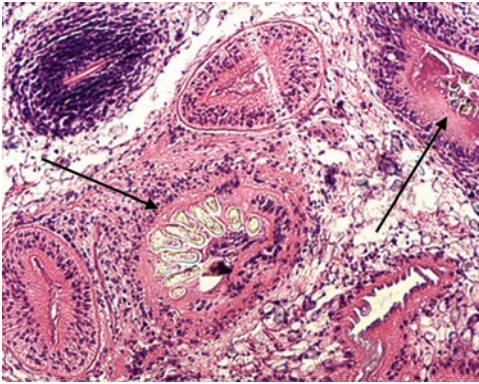
### Taenia multiceps (Multiceps multiceps)

It is a rare parasite infecting man.

### Morphology

- **Larva (coenurus):** Characterized by unilocular cyst with multiple scolices. Hence, named as Multiceps (Fig. 10.4D and 10.18)





**Fig. 10.18:** Coenurus removed from a subcutaneous nodule in the shoulder area of a patient, stained with hematoxylin and eosin (H and E) The black arrows point to hooklets in the protoscoleces

Source: DPDx Image Library, Centre for Disease Control and prevention (CDC), Atlanta (with permission)

- Adult worm is 40–60 cm in length. Scolex is pear shaped with four suckers and armed rostellum with two rows of hooklets
- Eggs are about 30  $\mu\text{m}$  in size, similar to that of other *Taenia* eggs.

### Life Cycle

- **Host:** It passes its life cycle through two hosts:
  1. **Definitive host:** Dog, fox and wolf
  2. **Intermediate host:** Herbivorous animals like sheep. Humans act as accidental intermediate host
- This disease occurs mainly in sheep and other herbivores affecting CNS where it is called as **gid** (means unstable gait and giddiness)
- Men get infection by ingestion of food and water contaminated with dog's feces containing eggs
- Oncospheres hatch out from the eggs, penetrate the intestine and migrate to various organs, usually CNS where they transform into the larval stage called as **coenurus**.

### Manifestations

Symptoms occurs as a result of space occupying lesions in CNS which includes headache, vomiting, paralysis, seizure, etc.

### Epidemiology

Most human cases occur in developing countries where the dog population is not controlled such as African countries (like Uganda, Kenya, Ghana and South Africa), Brazil, Mexico, Canada and the United States, and animal cases have been found in many other countries as well.

In India, few cases are reported so far. A recent case of cerebral coenurosis is reported from NIMHANS, Bangalore in 2011.

### Diagnosis

Diagnosis is based on gross and histological examination of coenurus following surgical removal.

Treatment	<i>Taenia multiceps</i>
Surgical removal is recommended. Praziquantel is also effective.	

## ECHINOCOCCUS SPECIES

*Echinococcus* causes hydatid disease in man. There are four species of *Echinococcus* known to infect humans:

- ***E. granulosus*:** Causes cystic hydatid disease
- ***E. multilocularis*:** Causes alveolar hydatid disease
- ***E. vogeli* and *E. oligarthrus*:** Cause polycystic hydatid disease.

### Echinococcus granulosus

#### History

It is also called as **dog tapeworm**.

- Hydatid cysts were recognized from the time of Hippocrates and Galen
- Hartmann (1695) had demonstrated the adult form in dogs while Goeze (1782) had described the larval form (hydatid cyst).

### Habitat

The larval form (hydatid cyst) is found in liver and other viscera of man and other herbivores. The adult worms reside in dog's intestine.

### Morphology

#### Adult Worm

It is much smaller than other cestodes.

- It measures 3–6 mm long, consists of head, neck and strobila (Fig. 10.19)
- **Head/scolex:** It is pyriform shaped (300  $\mu\text{m}$  diameter), bears four suckers and a rostellum armed with two rows of hooklets
- **Neck:** Short and thick
- **Strobila:** Made up of only three proglottids/segments: one immature, one mature and one gravid segment. The gravid segment is broader than others and is filled with 100–1,500 eggs. The structure of the proglottids is similar to other cyclophyllidean cestodes as described earlier.

#### Eggs

*E. granulosus* eggs are morphologically similar to *Taenia* eggs, consists of an oncosphere with six hooklets surrounded by an embryophore (Fig. 10.3 C).

#### Larva

The larval form of *E. granulosus* is called

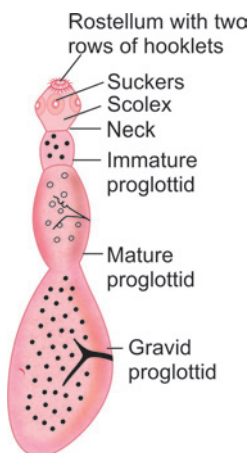


Fig. 10.19: *Echinococcus granulosus* (adult worm)

as **hydatid cyst**. (Described later under pathogenicity).

### Life Cycle (Fig. 10.20)

**Host:** *E. granulosus* life cycle passes through two hosts:

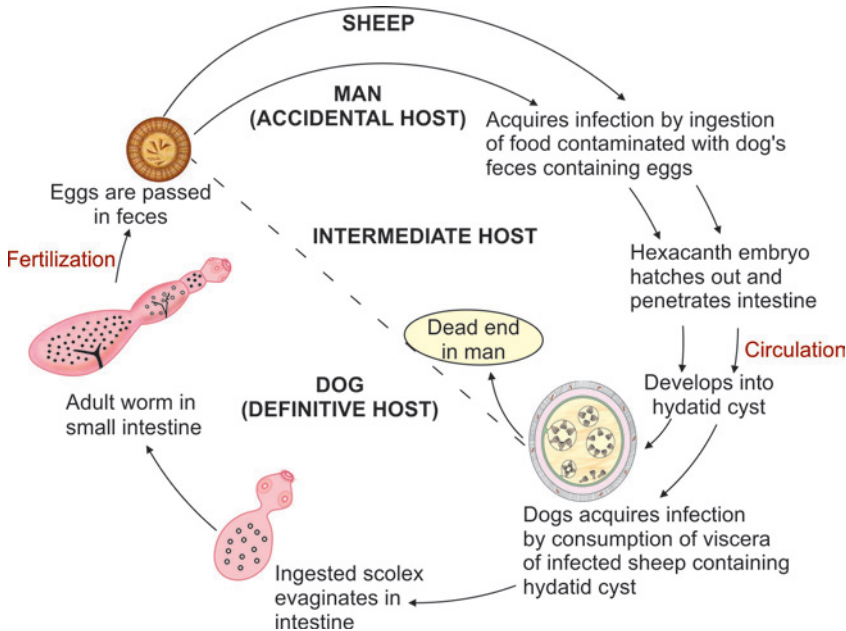
1. **Definitive host:** Dogs and other canine animals
  2. **Intermediate host:** Sheep and other herbivores
- Man acts as an **accidental intermediate host** (dead end).

**Mode of transmission:** Men (and other intermediate hosts) acquire the infection by ingestion of food contaminated with dog's feces containing *E. granulosus* eggs. Rarely flies serve as a *mechanical vector* of the eggs.

#### Development in man

**Eggs transform to larva (hydatid cyst):** In duodenum, the oncosphere is released by the rupture of embryophore. It penetrates into the intestinal wall, enters the portal circulation and carries to the liver (60–70% of cases) or lungs or rarely to other organs.

- Host-immune response tries to remove the parasite. Hence an inflammatory response takes place surrounding the sites where the oncospheres are settled
- Host-immune response may destroy many oncospheres, but few may escape destruction and develop into hydatid cyst
- The oncospheres are encysted by the fibrous tissue (produced by fibroblasts) and transform into fluid filled bladder like cyst called as **hydatid cysts**
- The hydatid cyst undergoes maturation increases in size at a rate of 1 cm/month. Full development takes 10–18 months in sheep (Fig. 10.20)
- This stage is infective to dog and other definitive hosts
- Man is a dead end (as dogs don't feed on human viscera).



**Fig. 10.20:** Life cycle of *Echinococcus granulosus*

### Development in Dog

Dog and other canine animals acquire infection by consumption of the contaminated viscera of intermediate hosts (sheep) containing mature hydatid cysts.

The hydatid cyst (larva) transforms into adult worm in dog's intestine. The adult worm becomes sexually mature, self fertilizes to produce eggs which are passed in feces and are infective to man.

### Pathogenicity

Pathogenicity is related to the deposition of the hydatid cysts (larval form of the parasite) in various organs.

### Hydatid cyst

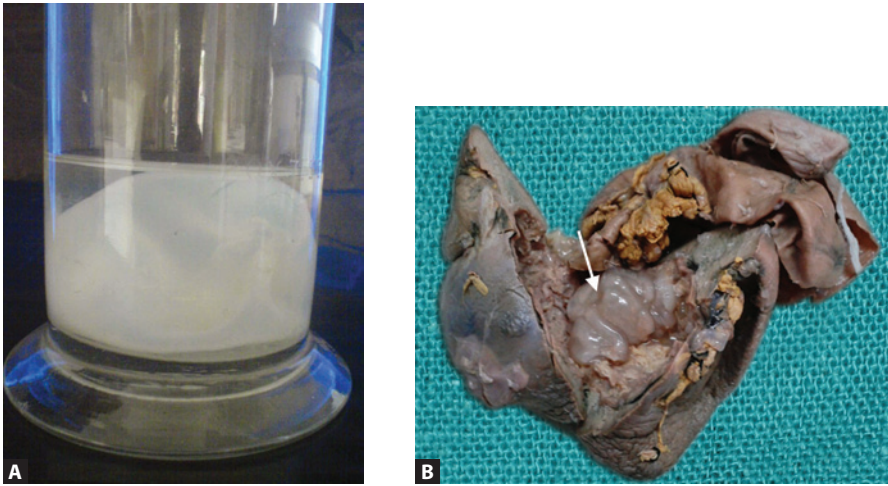
Fully developed hydatid cyst of *E. granulosus* is unilocular, subspherical, shape and size varies from few millimeters to more than 30 cm (usual size 5–8 cm) (Fig. 10.21).

- It appears as fluid filled bladder like cyst
- Cyst wall consists of three layers:

- **Pericyst** (outer layer, host derived): Consists of fibrous tissue and blood vessels produced by the host cellular reaction
- **Ectocyst** (middle layer, parasite derived): It is a tough elastic, glycan rich acellular hyaline layer of variable thickness (1 mm). It resembles the white of a hard-boiled egg
- **Endocyst** (inner layer, parasite derived): Germinal layer, 22–25  $\mu$ m thickness. It consists of number of nuclei embedded in protoplasmic mass. Its function is to form the ectocyst outside and on the inner side it forms brood capsule and secretes the hydatid fluid (Fig. 10.22)

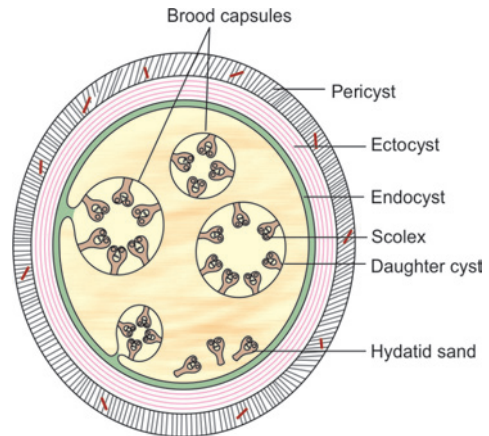
- **Hydatid fluid:** It is clear, colorless to pale yellow

- It has a pH of 6.7 and specific gravity of 1.005 to 1.010
- Chemical composition: It contains sodium chloride, sodium sulfate, sodium phosphate and succinates



**Figs 10.21A and B:** Hydatid cyst (A) macroscopic picture; (B) surgically resected from liver  
 Courtesy: B- HOD, Pathology, Meenakshi medical College, Chennai

- It is antigenic, toxic and anaphylactic
- Brood capsules arise from the inner side of the endocyst and contains number of protoscolices (future head)
- **Hydatid sand:** Some of the brood capsules and protoscolices break off and gets deposited at the bottom as granular deposit to form the hydatid sand
- **Variety of hydatid cyst:**
  - **Primary cyst:** Formed directly from the oncosphere released from the eggs ingested
  - **Secondary cysts:** Formed due to the breakage of the primary cyst by trauma. The secondary cysts are carried in the circulations to various organs
  - **Acephalocyst:** Cysts without brood capsules and protoscolices
  - **Endogenous daughter cysts:** Formed by the breakage of the brood capsule into the hydatid fluid; surrounded by ectocyst and endocyst
- **Fate of the hydatid cyst:**
  - Spontaneous resolution may happen to few cysts
  - Rupture of the cyst may either lead to:
    - Formation of secondary cysts



**Fig. 10.22:** Microscopy hydatid cyst

- Anaphylactic reaction to the hydatid fluid antigens.

### Clinical Features

Infection usually occurs in childhood but gets manifested in adult life.

- **Site:** Most common site of location of the cyst is liver (60–70%, right lobe) or lung (20–30%) but may be found in any organs like spleen and kidney (3–5%), brain and heart (1–1.5%) and rarely bones



- They grow upto 5–10 cm in size within the first year and can survive for years or even decades
- **Asymptomatic:** Many cases are asymptomatic and infection is detected only incidentally by imaging studies
- **Symptoms occur due to:**
  - **Pressure effect of the enlarging cyst:** Leads to palpable abdominal mass, hepatomegaly, abdominal tenderness, portal hypertension and ascites
  - **Obstruction:** Daughter cyst may erode into the biliary tree or a bronchus and enter into the lumen to cause cholestasis and dyspnea
  - Secondary bacterial infection can cause pyogenic abscess formation in the hydatid cysts
  - **Anaphylactic reactions:** Cyst leakage or rupture may be associated with a severe allergic reaction to hydatid fluid antigens; leading to hypotension, syncope and fever
- **Outcome of the disease:** It depends on the cyst size and location
- Younger children are more associated with extrahepatic cysts in lungs, brain and orbital sites
- In 20–40% of cases, multiple cysts or multiple organ involvement have been reported.

### Epidemiology

*E. granulosus* is worldwide in distribution.

#### World

Greater prevalence is reported from temperate countries like South America, the entire Mediterranean countries, Eastern Europe, Northern Africa, Central Asia and also in tropics like India and Nepal.

#### India

Hydatid disease is reported from various places in India like UP, Tamilnadu, Andhra Pradesh, Punjab and Pondicherry.

### Laboratory Diagnosis

*Echinococcus granulosus*

- Hydatid fluid microscopy (direct mount or staining with acid fast stain)—detects brood capsules and protoscolices
- Histological examination (H & E)—demonstrates cyst wall and attached brood capsules
- Antibody detection—IHA, LAT, IFA, ELISA, Western blot
- Antigen detection—ELISA, CIEP, LAT
- Imaging methods—X-ray, USG (demonstrates Water lily sign), CT scan, MRI
- Molecular method—PCR, PCR-RFLP
- Skin test (Casoni test)

### Laboratory Diagnosis

#### Hydatid fluid microscopy

Aspirated hydatid fluid is examined for brood capsules and protoscolices by direct microscopy or staining with acid fast stain.

- Drop of centrifuged fluid is placed between two slides and the slides are rubbed over the fluid. Hydatid sand is felt as grating of the sand grains in between the slides
- Purulent material can be examined after treating with hydrochloric acid.

#### Histological examination

Surgically removed cysts can be subjected to histopathological stains like Giemsa, hematoxylin and eosin (H & E) and Periodic acid Schiff (PAS) stain to demonstrate the three layers of the cyst wall and attached brood capsules (Fig. 10.23).

#### Antibody detection

**Screening tests:** Various antibody detection methods are evaluated using crude *E. granulosus* cyst fluid antigen. They show variable results (60–90% sensitivity). These tests are:

- Indirect hemagglutination (IHA)
- Latex agglutination test (LAT)

- Indirect fluorescent antibody tests (IFA)
- ELISA

#### Confirmatory tests:

- **Immunodiffusion and electro immunodiffusion:** Detecting antibody against antigen-5 (arc-5)
- **Western blot:** Detecting antibody against antigen B fragment (produces 8–12kDa band). This test is 92% sensitive and 100% specific. Antigen B fragment binds specifically to IgG4 antibodies

Antibody methods are useful for sero-epidemiological study but cannot differentiate recent and past infection. Antigen B is the antigen of choice used for seroepidemiological study for detection of antibody.

Patients with liver cysts show better results than extrahepatic cysts. Alveolar echinococcosis shows better results than cystic echinococcosis.

#### Antigen detection

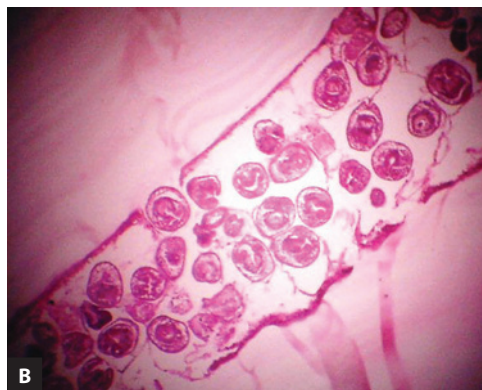
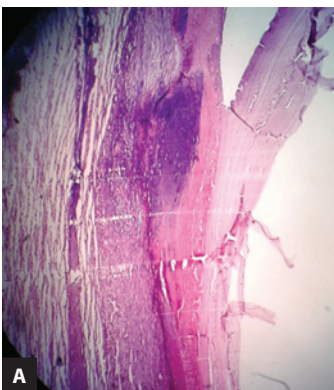
- ELISA, CIEP (counter-current immunoelectrophoresis) and LAT are available to detect specific antigens in serum and urine
- Antigen detection can differentiate recent from past infection and can be used as a prognostic marker.

#### Imaging methods

Imaging methods play an important role as

they are noninvasive methods, which can detect the cysts incidentally in asymptomatic individuals and in seronegative cases.

- **X-rays:** It is simple, inexpensive, yet useful technique to detect hepatomegaly and calcified cysts and cysts in lungs.
- **Ultrasound (USG):** It is the imaging method of choice because of its low cost and high diagnostic accuracy of 90%.
  - › It detects both single and multiple cystic lesions
  - › **Water lily sign:** When fluid leaks out of a cyst, the germinal layer gets collapsed and is seen floating within the cyst cavity
  - › **Daughter cysts:** Appear as cyst with in a cyst (cartwheel or honey comb appearance)
  - › Complications like biliary obstruction can be detected
  - › USG is used to monitor the response in treatment
  - › It is also used for epidemiological studies to detect the prevalence of hydatid cyst in population.
- **Computed tomography (CT scan):** It can detect 90–100% of cases.
  - › It detects more accurately the number, location of the cyst and the complications
  - › It is superior to detect the calcified



**Figs 10.23A and B:** Histopathological section of hydatid cyst (hematoxylin and eosin stain) (A) all three layers of cyst wall are seen—pericyst, ectocyst and endocyst; (B) endocyst with attached brood capsules

Source: HOD, Pathology, Meenakshi medical College, Chennai



lesions. Calcification occurs in 10% of cysts and usually requires 5–10 years to develop

- It is superior to USG to detect smaller cysts, extra-hepatic cysts and to differentiate hydatid cyst from other cystic lesions
- CT scan can also be used as a prognostic marker

- **Magnetic resonance imaging (MRI):** It has a higher contrast resolution, which makes cysts clearer. It can be used as an alternate to CT scan. However, it poorly detects the calcified cysts.

### **Molecular Methods**

- PCR targeting mitochondrial DNA has been developed
- PCR-RFLP can be used to detect genotypes of *E. granulosus*
- 10 genotypes have been identified from G1 to G10; each has a particular host specificity and geographical distribution. G1 is the most common genotype in India.

### **Skin test (Casoni test)**

It is an immediate hypersensitivity reaction to hydatid fluid antigens.

- Developed by Casoni in 1911
- **Antigen used:** Sterile hydatid fluid derived from unilocular cysts from dog or man (sterilized by filtration)
- **Procedure:** 0.2 mL of the antigen is injected in one arm; sterile saline is injected to the other arm as control
- **Interpretation:** Sensitive patients develop large wheal measuring 5 cm or more with formation of pseudopodia within 30 minutes with no reaction in the control arm
- **Disadvantage:** It has low sensitivity (60–80%) and gives false positive results in cross reactive cestode infections
- It is obsolete now days and replaced largely by the serological tests.

### **Other tests**

- Eosinophilia is present in 20–25% cases
- Hypergammaglobulinemia.

### **Tests to monitor the response in treatment**

- Imaging methods like USG, CT or MRI-size of the cyst decreases or disappears on improvement of the patient
- Antigen detection methods: Antigen disappears when patient improves.

Treatment	Echinococcus granulosus
	<p>Therapy for cystic echinococcosis is based on the considerations like–size, location, and manifestations of cysts and overall health of the patient.</p> <p><b>PAIR (puncture, aspiration, injection and re-aspiration)</b></p> <p>It is an alternate method recommended instead of surgery. It involves four basic steps:</p> <ul style="list-style-type: none"> <li>• Percutaneous puncture of the cyst</li> <li>• Aspiration of 10–15 mL of cyst fluid</li> <li>• Infusion of scolicidal agents like hypertonic saline, cetrimide, or ethanol</li> <li>• Re-aspiration of the fluid after 5 minutes</li> </ul> <p>PAIR claims higher cure rate, less recurrence rate, less complications and hospitalization compared to surgery</p> <p>PAIR is recommended for larger hepatic cyst, cyst within cyst, multiple cysts, and cyst with detached membrane</p> <p>PAIR is contraindicated for:</p> <ul style="list-style-type: none"> <li>• Superficially located cysts (because of the risk of rupture)</li> <li>• Inaccessible cyst or extrahepatic cysts</li> <li>• Cysts communicating to biliary tree.</li> </ul> <p><b>Surgery</b></p> <ul style="list-style-type: none"> <li>• Though surgery is the definitive method of treatment, it should be reserved for: <ul style="list-style-type: none"> <li>➤ Cases where PAIR is contraindicated or refractory</li> <li>➤ Secondary bacterial infection</li> <li>➤ Advanced disease</li> </ul> </li> <li>• Disadvantages of surgery are high recurrence rate (2–25%) and post operative complications (10–25%).</li> <li>• Preoperative use of albendazole is effective in reducing size and to prevent recurrence.</li> </ul>

Contd...

Contd...

Treatment	Echinococcus granulosus
<b>Antiparasitic agents</b> Albendazole is the drug of choice, given to prevent recurrence and to reduce the size of the cyst before surgery or PAIR and is given at 15 mg/kg daily in two divided doses 4 days before to 4 weeks after the procedure. Praziquantel is given alternatively.	
<b>Percutaneous thermal ablation</b> It is a noninvasive method, involves percutaneous radiofrequency ablation of the germinal layer of the cysts.	

### Prevention

Echinococcosis can be prevented by:

- Administering praziquantel to infected dogs
- To improve personal hygiene to reduce contamination of food and water with dog's feces
- Vaccinating the sheep
- Limitation of stray dogs population.

### Echinococcus multilocularis

#### Morphology

*E. multilocularis* is morphologically similar to *E. granulosus* except it is smaller in size (1.2–3.7 mm length).

#### Life Cycle

Life cycle is similar to that of *E. granulosus*. Only the hosts are different.

**Host:** There are two types of hosts:

- 1. Definitive host:** Foxes and wolves (and also dogs and cats)
- 2. Intermediate hosts:** Small wild rodents like squirrels, voles, mice, etc.  
Man is an **accidental intermediate host**.

### Clinical Features

*E. multilocularis* is the causative agent of alveolar (or multilocular) hydatid disease.

- So named because the cysts have multiple locules or cavities with no fluid or no free brood capsule/scolices (Fig. 10.24)

- Liver is the most common organ affected (98% of cases)
- **Symptoms:** Similar to that of *E. granulosus* such as hepatomegaly and portal hypertension
- Cyst appears as solid, firm mass with irregular outer layer and has an ability to migrate rapidly to other organs so that it mimics a malignant tumor
- Cysts spread by direct extension or via blood or lymphatics. Some cases (2%), piece of the endocyst may migrate to brain and lungs
- The rapid invasion is due to a **surface protein 14-3-3** found on germinal layer
- This disease is found more frequently in Russia, Kazakhstan, China, South-Central Europe and North America.

#### Laboratory Diagnosis

*Echinococcus multilocularis*

- Imaging methods—X-ray, USG, CT scan, MRI
- Antibody detection—Western blot technique, ELISA
- Histopathological diagnosis—PAS staining following FNAC

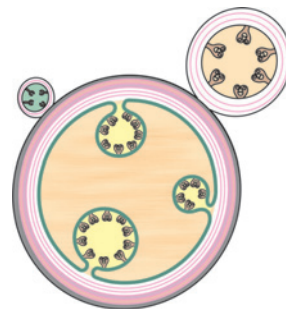
### Laboratory Diagnosis

#### Imaging methods

Imaging methods like USG, CT Scan and MRI can detect the number and size of the cyst, extension of the lesion and calcification if any.

#### Antibody detection tests

- Different ELISA formats are available using cyst fluid antigen, cyst wall derived



**Fig. 10.24:** Alveolar hydatid disease

glycan (Em2) antigen, recombinant EM-10 antigen. These tests are sensitive (86-97%) but gives false positive results in cross reacting *E. granulosus* infection.

- Western blot using Em-18 antigen is highly sensitive (97%) and specific (100%) and doesn't cross react with *E. granulosus*.

### Histopathological diagnosis

Staining with Periodic Acid Schiff (PAS) following FNAC (fine needle aspiration cytology) or biopsy can be done to detect the multiloculated sterile cyst and associated necrosis.

### Treatment and Prevention

Similar to that of *E. granulosus*.

## Echinococcus oligarthrus and Echinococcus vogeli

They rarely infect humans and cause polycystic hydatid disease

**Host:** There are two types of host:

1. **Definitive host:** Wild felids like wild cats, jaguars and pumas (*E. oligarthrus*) or brush dogs (*E. vogeli*)
2. **Intermediate host:** Rodents like paca, spiny rats and opossum.

### Life Cycle

It is similar to *E. granulosus*

### Clinical features

Only four cases of *E. oligarthrus* are reported so far, three involving orbit and one involving heart.

*E. vogeli* infects most commonly liver (80%) followed by lungs and other viscera. Symptoms are similar to cystic echinococcosis.

### Epidemiology

To date, only 80 cases of polycystic hydatid disease have been reported.

Most of the cases are seen in humid tropical forest area of central and Northern South America like Brazil, Colombia, Panama and Venezuela.

### Laboratory Diagnosis

Depends on imaging methods, histopathology, serology or molecular methods like PCR.

### Treatment and prevention

Similar to that of *E. granulosus*.

## HYMENOLEPIS NANA

- It is the smallest cestode infecting man, hence called as dwarf tapeworm
- Name *Hymenolepis* refers to a thin membrane covering the eggs (Hymen- membrane, lepis- covering, and nana- small size)
- It was first detected by Bilharz in 1857 in small intestine.

### Epidemiology

*H. nana* is considered as the most common tapeworm infection throughout the world infecting 50-75 million of people.

The overall prevalence ranges from 0-4% with higher prevalence in children (16%).

### Morphology

#### Adult Worm

The adult form is small, 1-4 cm in length and consists of head, neck and strobila. It resides in the small intestine (upper two third of ileum).

- **Head/scolex:** It is globular with four suckers and a rostellum bearing single row of 20-30 hooklets
- **Neck:** It is long and gives rise to proglottids
- **Strobila:** Consists of 200 segments (proglottids). Mature proglottids contain both male and female reproductive organs. Genital pore opens laterally on the same side. Uterus has lobulated wall and there are only three testicular follicles (Rest description is similar to any other cyclophyllidean cestodes described earlier).

### Egg

Eggs are the infective form as well as the diagnostic form of the parasite.

- Egg is round to slightly oval, 30-47 µm size

- It has two membranes (outer egg shell and an inner embryophore) and an oncosphere with six hooklets. Space between the two membranes is filled with yolk granules
- **Polar filaments:** Both the poles of embryophore are thickened from which four to eight polar filaments emerge
- **Non bile stained** (colorless in saline mount): It is the only cestode egg that is not stained by bile when passed through intestine.

### Larva

The larval form is called **cysticercoids**.

It is solid except the proximal part which is vesicular and contains the scolex.

### Life Cycle (Fig. 10.25)

Two life cycles are noted, i.e. direct and indirect cycle.

### Direct Cycle

**Host:** Man is the only host. There is no intermediate host. Rodents (rat and mice) are the other hosts.

**Infective form:** Eggs

**Mode of transmission:** Men acquire the infection by:

- Ingestion of food and water contaminated with eggs
- Autoinfection with their own eggs released in the small intestine.

**In the small intestine,** eggs hatch out, penetrate the intestinal wall and develops into cysticercoid larvae in 4–5 days.

- Thereafter, the intestinal villi rupture and cysticercoids larvae become free in the gut lumen and transform into the adult worms in 10–12 weeks
- Adult worm, when fully mature undergoes

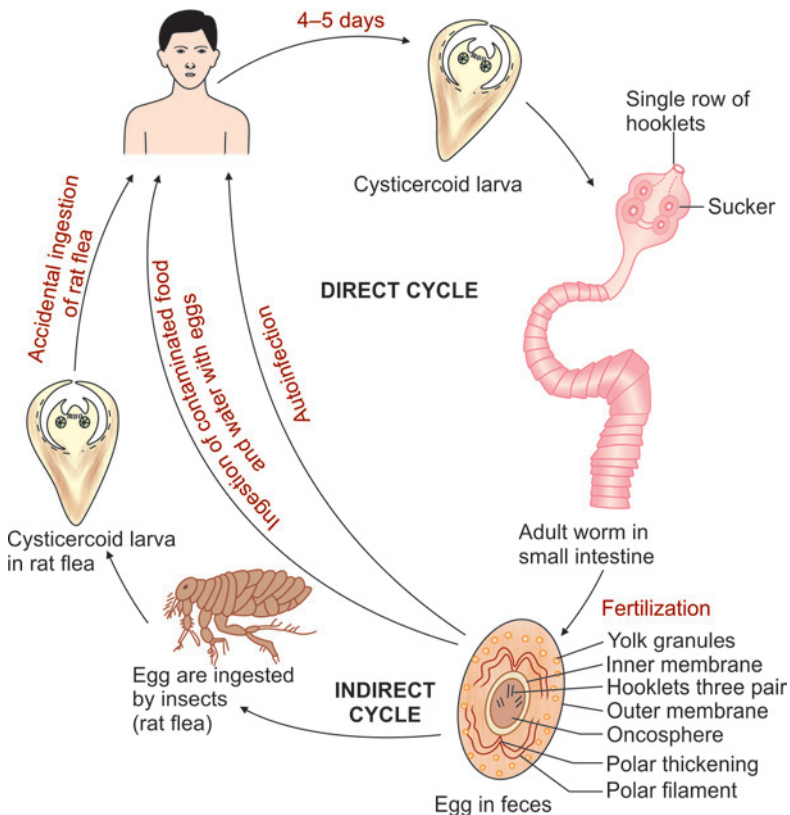


Fig. 10.25: Life cycle of *Hymenolepis nana*

fertilization to produce eggs

- Eggs are passed in the feces which are infective to man
- Though the adult worm lives only about 4–10 weeks, the infection persists due to autoinfection.

**Indirect Cycle**

**Host:** Man is the **definitive host**. Insects act as **intermediate host** such as rat fleas like *Pulex irritans* and *Xenopsylla cheopis*.

**Mode of transmission:** Men acquire the infection rarely, by accidental ingestion of insects containing the cysticeroid larva.

**In human intestine:** The larva develops into adult worm in human small intestine which then produces eggs that are passed in the feces.

**In rat fleas:** Eggs are ingested by the insects, embryo hatches out, penetrate the intestine and develop into the larval stage-cysticeroid larva in the insect's body cavity. This stage is infective to men.

**Clinical Features and Pathogenicity**

*H. nana* infection is usually asymptomatic.

When infection is intense and the worm burden exceeds 1000-2000 worms, patients develop symptoms like anorexia, abdominal pain, headache, dizziness and diarrhea.

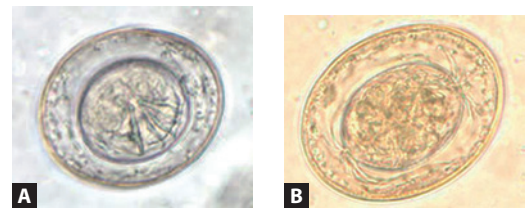
**Laboratory Diagnosis**

- Stool examination (detects non bile stained eggs with polar filaments between the shell membranes)
- Eosinophilia

Hymenolepis nana

**Laboratory Diagnosis**

Infection is diagnosed by detection of the characteristic non bile stained eggs with polar filaments between the shell membranes in the stool (as described earlier) (Fig. 10.26)



**Figs 10.26A and B:** Non bile stained egg of *Hymenolepis nana* in (A) saline mount—three pairs of hooklets are seen clearly; (B) iodine mount—polar filaments are seen clearly  
Source: DPDx Image Library, Centre for Disease Control and prevention (CDC), Atlanta (with permission)

Some patients have eosinophilia of 5% or more.

Treatment	Hymenolepis nana
	<ul style="list-style-type: none"><li>• Praziquantel (25 mg/kg once) is the treatment of choice, since it acts against both the adult worms and the cysticeroid larvae in the intestinal villi</li><li>• Nitazoxanide (500 mg bid for 3 days) may be used as an alternative.</li></ul>

**Prevention**

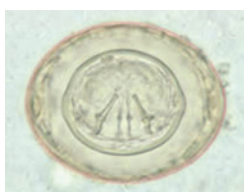Good personal hygiene and improved sanitation can eradicate the disease. Epidemics have been controlled by mass chemotherapy coupled with improved hygiene.

**HYMENOLEPIS DIMINUTA**

- *Hymenolepis diminuta* is also called as rat tape worm
- It is similar to *H. nana* with some differences as shown in the Table 10.6
- Always, it requires an intermediate host as insects like lepidopterans, myriapods, beetles etc
- It undergoes indirect life cycle only, there is no direct life cycle
- Human infection is rare, only less than 500

**Table 10.6:** Differences between *Hymenolepis nana* and *Hymenolepis diminuta*

	<i>Hymenolepis nana</i>	<i>Hymenolepis diminuta</i>
Common name	Dwarf tapeworm	Rat tape worm
Host	Man is the only host, occasionally insects act as intermediate host	Rodents (or man) definitive host and Insects are intermediate host
Life cycle	Both direct and indirect cycle	Only indirect cycle occurs, i.e. always needs insects
<b>Adult worm</b>		
Length	Small < 4 cm	Large, (1 meter or more)
Scolex	Bears four suckers with rostellum and hooklets	Bears four suckers, with rostellum but no hooklets
Proglottids	< 200	800–1,000
Egg	Smaller, 30–47 $\mu\text{m}$ , polar filaments present Non bile stained	Larger 60–80 $\mu\text{m}$ (Fig. 10.27) polar filaments absent and bile stained
Human infection	Common	Rare



**Figs 10.27:** Egg of *Hymenolepis diminuta* (saline mount) Courtesy: DPDx Image Library, Centre for Disease Control and prevention (CDC), Atlanta

cases are reported so far, mainly from India or other places like Japan, Italy, etc.

## DIPYLIDIUM CANINUM (DOUBLE PORED TAPEWORM)

This is a common tapeworm of dogs and cats.

### Morphology

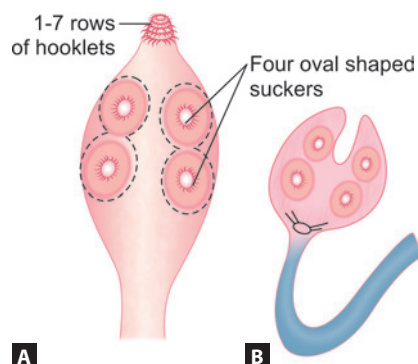
Adult worm is 10–70 cm long, scolex contains four oval suckers and is armed with rostellum and 1–7 rows of hooklets (Fig. 10.28A).

### Life Cycle

It resembles with the indirect cycle of *H. nana*.

**Host:** There are two types of hosts:

**1. Definitive host:** Dogs and cats (rarely men)



**Figs 10.28A and B:** *Dipylidium caninum* schematic diagrams (A) scolex; (B) cysticercoid larva

**2. Intermediate host:** Insects (fleas)

Man acquires infection by ingestion of flea containing cysticercoid larva (Fig. 10.28B)

### Clinical Features

Mostly, asymptomatic, but rarely symptoms like indigestion, loss of appetite, diarrhea, pruritus ani, abdominal pain may be reported. Children are affected commonly.

### Laboratory Diagnosis

By demonstration of proglottids or eggs in feces.



- **Eggs:** Eggs are of 25–40  $\mu\text{m}$  size, present in groups of 15 (egg packets). (Fig. 10.29A)
- Proglottids are typically barrel shaped (3.2 mm wide), looks like cucumber seed when fresh and rice grain when dry. It contains two sets of reproductive organs with two genital pores on both the lateral side, hence named as double pored tapeworm (Fig. 10.29B).

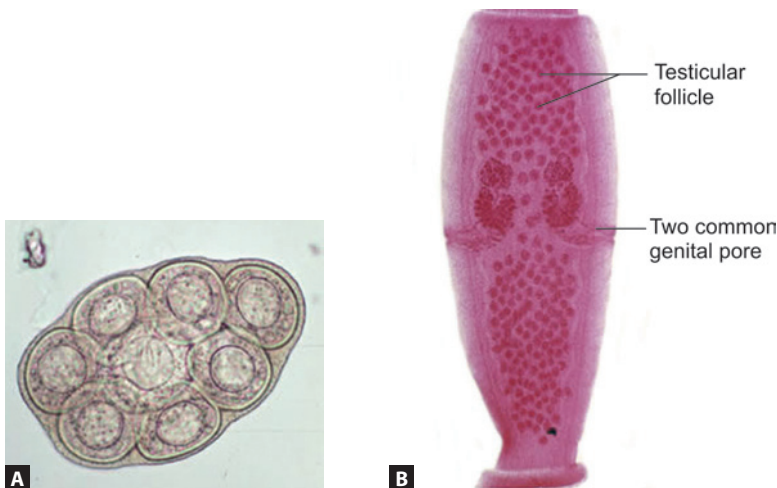
### Epidemiology

Human cases are rare and have been reported from Austria, Japan and the USA.

Treatment	Dipylidium caninum
Praziquantel is the drug of choice	

### Prevention

Requires flea control.



**Figs 10.29A and B:** *Dipylidium caninum* real diagrams (A) egg packets; (B) proglottids with two genital pores (hematoxylin and eosin stain)

Source: DPDx Image Library, Centre for Disease Control and prevention (CDC), Atlanta (with permission)

## EXPECTED QUESTIONS

### I. Write essay on:

- Describe the life cycle, pathogenesis and laboratory diagnosis of *Taenia solium*?
- Describe the life cycle, pathogenesis and laboratory diagnosis of *Echinococcus granulosus*?

### II. Short notes on:

- Sparganosis
- Diphyllobothriasis
- Double pored tapeworm
- Hydatid cyst
- Laboratory diagnosis of Neurocysticercosis

- Polycystic hydatid disease
- Alveolar hydatid disease
- Coenurosis

### III. Differentiate between:

- Taenia solium* and *Taenia saginata*
- Hymenolepis nana* and *Hymenolepis diminuta*

### IV. Multi choice questions (MCQs):

1. Which of the following cestode does not have a rostellum and hooks?

- Echinococcus granulosus*
- Taenia solium*
- Taenia saginata*
- Hymenolepis nana*

Contd...

Contd...

**2. Which of the following cestode eggs are NOT bile stained?**

- (a) *Hymenolepis nana*
- (b) *Diphyllbothrium latum*
- (c) *Echinococcus granulosus*
- (d) *Taenia solium*

**3. The larval form of *Hymenolepis nana* is called:**

- (a) Hydatid cyst
- (b) Coenurus
- (c) Cysticercus
- (d) Cysticercoid

**4. Humans acquire cysticercus cellulosae infection by all except:**

(a) Ingestion of Contaminated vegetables

(b) Autoinfection

(c) Reverse peristalsis

(d) Ingestion of contaminated pig's meat

**5. Which of the following cestode doesn't need an intermediate host to complete the life cycle?**(a) *Hymenolepis nana*(b) *Taenia saginata*(c) *Diphyllbothrium latum*(d) *Echinococcus granulosus***Answer**

1. (c)    2. (a)    3. (d)    4. (d)    5. (a)

# 11 Trematodes or Flukes

## Chapter Outline

- Classification of trematodes
- General characteristics of trematodes
- Blood flukes
  - *Schistosoma* species
- Liver flukes
  - *Fasciola* species
  - *Clonorchis* species
  - *Opisthorchis* species
- Intestinal flukes
  - *Fasciolopsis* species
  - Other less common intestinal trematodes
- Lung fluke
  - *Paragonimus* species
- Expected questions

Trematodes (also called as **flukes**) include the helminths that are unsegmented, flat (flat worms) and leaf-like.

## ■ CLASSIFICATION OF TREMATODES

### Systemic Classification

Systemic classification of medically important trematodes is proposed by Gibson and Bray (1994) and is outlined in Table 11.1.

**Trematodes belong to:**

- **Phylum:** Platyhelminths
- **Class:** Trematoda or Digenea

### Classification Based on the Habitat

#### Blood Trematodes (flukes)

- ***Schistosoma haematobium*:** Resides in vesical venous plexus

- ***Schistosoma mansoni*, *S. japonicum*:** Resides in rectal venous plexus and portal venous plexus.

#### Hepatic Trematodes (flukes)

- ***Fasciola hepatica* and *Fasciola gigantica*:** Both reside in liver
- ***Clonorchis* species and *Opisthorchis* species:** Both reside in bile duct.

#### Intestinal Trematodes (flukes)

- **Small intestine:** *Fasciolopsis buski*, *Heterophyes* species, *Metagonimus* species, *Watsonius* species
- **Large intestine:** *Gastrodiscoides* species

#### Lung Trematodes (flukes)

*Paragonimus westermani*

**Table 11.1:** Classification of trematodes

Order	Superfamily	Family	Genus	Species
Strigeida	Schistosomatoidea	Schistosomatidae	<i>Schistosoma</i>	<i>S. haematobium</i> <i>S. mansoni</i> <i>S. japonicum</i> <i>S. mekongi</i> <i>S. intercalatum</i>
Echinostomida	Paramphistomatoidea	Zygocotylidae	<i>Gastrodiscoides</i>	<i>G. hominis</i>
			<i>Watsonius</i>	<i>W. watsoni</i>
	Echinostomatoidea	Fasciolidae	<i>Fasciola</i>	<i>F. hepatica</i>
			<i>Fasciolopsis</i>	<i>F. buski</i>
Plagiorchiida	Opisthorchioidea	Opisthorchiidae	<i>Opisthorchis</i>	<i>O. felinus</i> <i>O. viverrini</i>
			<i>Clonorchis</i>	<i>C. sinensis</i>
		Heterophyidae	<i>Heterophyes</i>	<i>H. heterophyes</i>
			<i>Metagonimus</i>	<i>M. yokogawai</i>
	Plagiorchioidea	Paragonimidae	<i>Paragonimus</i>	<i>P. westermani</i>

## GENERAL CHARACTERISTICS OF TREMATODES

### Morphology

Trematodes exist in three morphological forms—adult worm, egg and larva. The adult worms are unsegmented and flattened dorsoventrally but some have thick fleshy bodies (schistosomes).

- **Size:** Range from less than 1 mm to ~60 mm
- **Suckers:** They attach to host with two suckers—(1) oral sucker (anterior) which surrounds the mouth and (2) ventral sucker (acetabulum) on the ventral surface
- **Digestive system:** It is incomplete, consists of anterior mouth, muscular pumping pharynx which continues as esophagus. Esophagus bifurcates in front of ventral sucker into a pair of blind intestinal pouches called caeca. The anus is absent
- Most trematodes are hermaphrodites (monoecious) except the schistosomes, which are dioecious (sexes are separate)
- **Male reproductive organs:** Consist of number of testes present near the cecal end, vas efferens arise from each testes join to form a common

vas deferens which runs via a small seminal vesicle and opens at genital pore situated near the ventral sucker

- **Female reproductive organs:** Consist of an ovary (present near the ventral sucker), vitelline glands surrounding ovary, oviduct, ootype and a uterus containing eggs that opens behind the ventral sucker
- The **excretory system** is bilaterally symmetrical. It consists of flame cells and collecting tubules which lead to a median bladder opening at the posterior end of the body, usually on the dorsal aspect
- The **nervous system** consists of paired ganglia at the anterior end. From this, nerves extend anteriorly and posteriorly
- **Oviparous:** Trematodes are oviparous, i.e. they lay eggs
- The eggs are operculated except those of schistosomes
- **Larva:** Trematodes have many larval forms such as miracidium, sporocyst, redia, cercaria, and metacercaria.

### Life Cycle

**Host:** Trematodes complete their life cycle

in three different hosts, one definitive host (man) and two intermediate hosts. **The first intermediate** host is **fresh water snail** or **mollusc** and the **second intermediate** host is either aquatic **plant** or **fish** or **crab**. However, schistosomes don't need a second intermediate host.

**Mode of transmission:** Man acquires infection by eating aquatic plants, fishes or crabs harboring infective form (metacercariae) or by the penetration of free living cercariae (schistosomes).

**Development in Definitive Host (Man)**

The young trematodes migrate to their habitat where they grow into adults, sexually mature and begin to lay eggs, which are excreted in feces, urine or sputum (depending on the species) and gain access to water.

Depending on embryonation, eggs show three different types of development:

- 1. The eggs which are embryonated when laid, hatch to release miracidia, which infect the intermediate host, i.e. snail (e.g. schistosomes)
- 2. The eggs which are not embryonated when laid, first mature in water and then hatch to release miracidia, which infect suitable intermediate host (e.g. *Paragonimus*, *Fasciola*, and *Fasciolopsis*)
- 3. The eggs which are embryonated when laid, but hatch only on ingestion by suitable snail host (e.g. *Clonorchis*, *Opisthorchis*, and *Metagonimus*).

**Developments in First Intermediate Host (Snail)**

The miracidium is a free swimming ciliated larva which penetrates suitable intermediate host like snails or molluscs.





- Miracidium contains apical gland which releases proteolytic enzymes which aids the process of penetration
- In liver or lymph spaces of intermediate host, miracidium transforms into sporocyst

- Asexual multiplication of sporocysts does not occur at this stage except in schistosomes where asexual multiplication gives rise to second generation sporocysts
- The sporocysts develop to become rediae. The rediae multiply to produce second generation rediae or transform into cercariae. There is no redia stage in schistosomes
- A single miracidium can give rise to large number of cercariae. Based on the morphology of tail, cercariae can be divided into four types (Table 11.2)
- In schistosomes, cercariae are infective to man, whereas in other trematodes; metacercariae are the infective forms.

**Developments in Second Intermediate Host (Fish or Crab)**

After ingestion by a fish or a crab, the cercarial larvae develop into metacercariae which are the infective forms to the definitive host (man).

**Table 11.2:** Types of cercarial larvae of trematodes

	Elongated body with forked tail (e.g. <i>Schistosoma</i> )
	Oval body with short stumpy tail (e.g. <i>Paragonimus</i> )
	Cercaria is armed with spines and has a large fluted tail and conspicuous eye spots, (e.g. <i>Clonorchis</i> , <i>Metagonimus</i> and <i>Heterophyes</i> )
	Cercaria is armed with spines and has a pigmented eye spots with a long keeled tail, (e.g. <i>Opisthorchis</i> )

## BLOOD FLUKES

### SCHISTOSOMA SPECIES

The schistosomes are known as **blood flukes** as they live in vascular system of humans and other vertebrate hosts. They cause **schistosomiasis** which is the second most devastating tropical parasitic disease after malaria affecting more than 200 million people residing in rural and agricultural areas. *Schistosoma* species belong to

- **Order:** Strigeida
- **Superfamily:** Schistosomatoidea
- **Family:** Schistosomatidae.

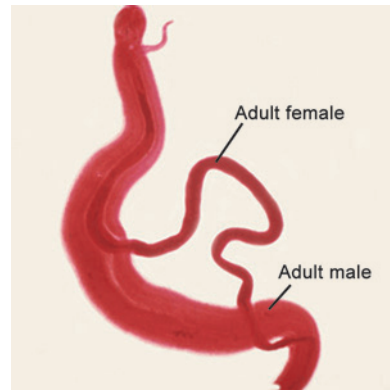
### General Characteristics

The general morphology of schistosomes is similar to any trematodes described earlier. However, they differ from other trematodes in many ways which is discussed below.

### Adult Worm

Adult worms live in the venous plexuses of definitive hosts (hence called as **blood flukes**).

- The body is cylindrical, covered by a thick (4  $\mu\text{m}$ ), tuberculated and syncytial tegument (except in *S. japonicum* which possesses a smooth tegument)
- There is no muscular pharynx and the intestinal caeca reunite behind the ventral sucker to form a single canal
- Suckers are armed with delicate spines
- Sexes are separate (dieocious) with female worms slightly longer and slender than males worms (Fig. 11.1)
- Male worm possesses a sex canal (gynecophoric canal) on ventral side in which the female worm reposes
- The number of testes in male worms varies from four to nine
- The Laurer's canal is absent in female worms
- Humans (or animals) are the **definitive hosts**, snails are the **intermediate hosts**
- There is no second intermediate host.



**Fig. 11.1:** Adult worms of schistosomes  
(The thin female resides in the gynecophoric canal of the thicker male)

Source: DPDx Image Library, Centre for Disease Control and prevention (CDC), Atlanta (with permission)

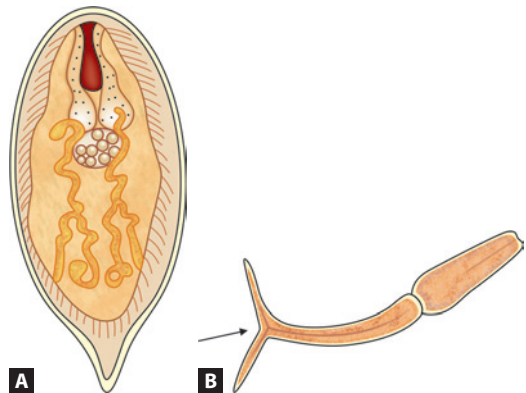
### Eggs

Schistosomes lay non-operculated eggs with a spine like projection. Eggs are fully embryonated when excreted in urine or feces that hatch out immediately to form miracidia (Fig. 11.2A).

### Larva

Various larval forms are miracidium, sporocyst and cercaria.

- There are no rediae and metacercariae stages
- The cercariae have forked tail (Fig. 11.2B) but no pharynx and they are the infective form to man (by penetration of skin).



**Figs 11.2A and B:** *Schistosoma haematobium*  
(A) terminal spined egg; (B) fork tailed cercaria



**Table 11.3:** Schistosomes that parasitize humans

<b>Schistosomes</b>	<b>Definitive host</b>	<b>Intermediate host (various genera of snail)</b>	<b>Distribution</b>
<b>African schistosomes</b>			
<i>Schistosoma haematobium</i>	Man, monkey, chimpanzee	<i>Bulinus</i>	Africa and Middle East
<i>Schistosoma mansoni</i>	Man, monkey, chimpanzee and dog	<i>Biomphalaria</i>	Africa and South America and Caribbean
<i>Schistosoma intercalatum</i>	Man	<i>Bulinus</i>	West and Central Africa
<b>Asian schistosomes</b>			
<i>Schistosoma japonicum</i>	Man, dog, cat and rodent	<i>Oncomelania</i>	China and Philippines
<i>Schistosoma malayensis</i>	Man and rodent	<i>Robertsiella</i>	Malaysia
<i>Schistosoma mekongi</i>	Man and dog	<i>Neotricula</i>	Laos and Thailand

## Schistosomes that Parasitize Humans

Mainly the species infecting humans are categorized into African and Asian schistosomes (Table 11.3).

### SCHISTOSOMA HAEMATOBIMUM

#### History

*Schistosoma haematobium* is the causative agent of **urinary schistosomiasis or bilharziasis**. Theodor Bilharz in 1851 detected the adult worm and the terminal spined eggs in the mesenteric veins of a young man at autopsy.

#### Habitat

Adult male worm holds the female worm in the gynecophoric canal and resides in the venous plexus of urinary bladder and ureter.

#### Epidemiology

Approximately, 200–300 million individuals are infected with schistosomes globally.

*S. haematobium* infection is common with Africa including Caribbean Islands (West Indies), Madagascar and Arabian Peninsula.

**India:** Schistosomiasis is extremely rare in

India. A confirmed endemic focus of urinary schistosomiasis was demonstrated in Gimvi village of Ratnagiri district, Maharashtra transmitted by snail of genus *Ferrissia*.

## Morphology

### Adult Form

They are diecious and can live for 20–30 years. The male worm is 15 mm in length and 0.9 mm in breadth. They have 4–5 testes. Female worm is 20 mm in length and 0.25 mm in breadth. Fertilized female worm contains 20–200 terminal spined eggs at one time.

### Egg

The eggs measure 120–170 µm in length and 40–70 µm in breadth. They are oval, brownish yellow and non-operculated. The eggs have characteristic terminal spine at the posterior end (Fig. 11.2A)

### Larva

*S. haematobium* has many larval stages such as miracidium, sporocyst and cercaria. Cercaria larva is the infective form to man.

### Cercaria

It is elongated and oval with 400 µm length (including tail) and 60 µm breadth. The body

is covered with minute spine like projection on the surface. It has two suckers, i.e. anterior and ventral and has bifurcated tail. It has a life span of 24–72 hours (Fig. 11.2 B).

### Life Cycle (Fig. 11.3)

**Host:** There are two types of host:

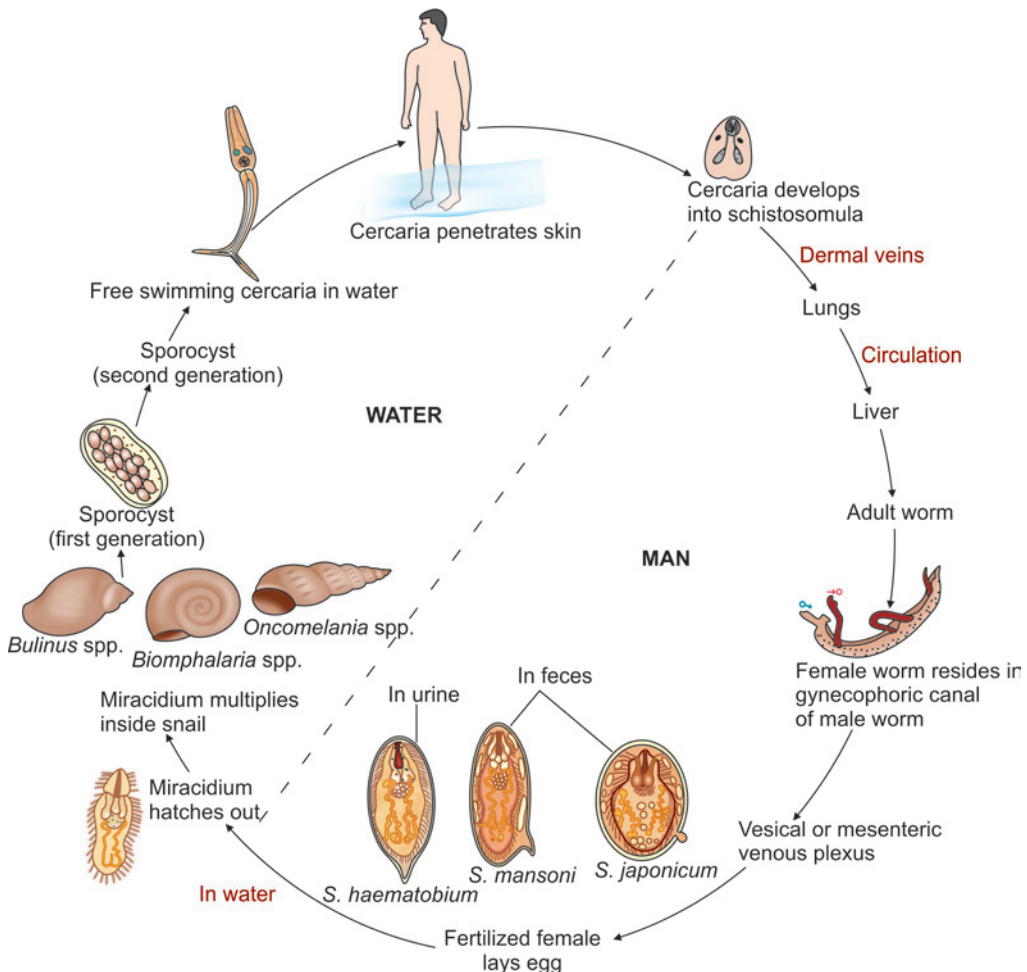
- 1. Definitive host:** Man is the definitive host.
- 2. Intermediate host:** Freshwater snails of genus *Bulinus*.

**Mode of transmission:** Man acquires infection by penetration of skin by the infective form (cercariae) present in contaminated water.

### Development in Man

The free swimming infective cercaria penetrates the intact epidermis with the help of oral and ventral suckers. It loses its tail and outer coating to become the next stage larva, **schistosomula**.

- The schistosomula travels via dermal veins to reach lungs and from there via the systemic circulation, it enters the portal system
- Within liver sinusoids, it feeds and grows for a period of 5–6 weeks to develop into adult worm



**Fig. 11.3:** Life cycle of *Schistosoma* species

- Adult worms become sexually mature, pairing of worms take place, female worms reside in the gynecophoric canal of male worms. They migrate from the portal system, move against the blood flow and reach vesical and ureteric venous plexus
- The young flukes become coated with host red cell antigens and histocompatibility antigens, so that they are not recognized as foreign and escape from the host immune response
- Fertilized female worm lays eggs in these venous plexus. The eggs penetrate the venules and urinary mucosa with the help of terminal spine and the lytic substances secreted by them. Eggs along with blood are excreted in urine
- **Pre-patent period:** It is the time taken between the penetration of cercariae and the first production of eggs, which is usually 2–3 months.

### Development in Water

The fully embryonated eggs are passed in urine. When these eggs gain access into the water they hatch to release free-swimming miracidium.

### Development in Snail

Miracidium lives in water for 8–12 hours and infect snails of *Bulinus* species.

- In snail, the miracidium multiplies asexually giving rise to first and second generation sporocysts which on further development, transforms to fork tailed cercaria. Redial stage is absent
- A single miracidium can give rise to  $\sim 10^5$  cercariae. The cercariae escape from the snail into water and cause human infection. The cycle is repeated.

## Pathogenesis and Clinical Features

### Acute Schistosomiasis

The invasion of cercariae in the skin causes dermatitis at penetration site followed by allergic pruritic papular lesion.

Migration of schistosomula in lungs causes cough with mild fever.

## Chronic Schistosomiasis

### Urogenital disease

Light infection may be asymptomatic. Symptoms develop usually after 3–6 months.

- The adult worms are rarely pathogenic. The main pathogenic mechanism in schistosomiasis is due to the eggs deposited in various tissues
- The eggs passing into urinary bladder cause the mucosal damage that leads to dysuria and hematuria (seen upto 80% of children infected)
- The soluble antigens released from the eggs provoke delayed type of hypersensitivity reaction around them. This leads to the formation of egg granuloma composed of egg at the center surrounded by macrophages, lymphocytes, fibroblasts, and multinucleated giant cells
- The granuloma varies in size. Many granulomas are joined together, to form larger nodules. The urinary mucosa covering the nodules shows glandular metaplasia (**cystitis glandularis**)
- Later on, in chronic stage fibrotic changes occur, visible as sandy patches on cystoscopy.

### Obstructive uropathies

Fibrosis may cause obstruction of the lower end of the ureters that result in hydroureter and hydronephrosis, which may be seen in 25–50% of infected children.

### Bladder carcinoma

The metaplastic changes in urinary mucosa may lead to carcinoma of bladder.

- **Predisposing factors:** Nitroso compounds intake and secondary bacterial infections
- **Type:** Squamous cell carcinoma is the most common type. It is seen with high to moderate worm burden where as transitional cell carcinoma may occur in areas with lighter worm load.

### Involvement of other sites

Eggs may be carried by venous blood to various parts of the body like spinal cord,

liver, lungs or intestine and produce similar granulomas.

### Laboratory Diagnosis

#### Schistosoma haematobium

- Urine microscopy—Detects terminal spined eggs
- Histopathology of bladder mucosal biopsy—Detects terminal spined eggs
- Antibody detection (serum)—HAMA-FAST-ELISA, HAMA-EITB, IFA, IHA and cercarial Huller reaction
- Antigen detection (serum and urine)—CCA and CAA detection by ELISA or dip stick assay

### Laboratory Diagnosis

#### Urine Microscopy

Diagnosis of *S. haematobium* is made by detection of non-operculated terminal spined eggs in the urine or rarely in feces (Figs 11.2A and 11.4A).

The terminal hematuria portion of urine is collected between 12 pm and 3 pm, concentrated by centrifugation or by membrane filtration and observed under microscope for the presence of non operculated terminal spined eggs.

### Histopathology

Demonstration of *S. haematobium* eggs in bladder mucosal biopsy confirms the diagnosis.

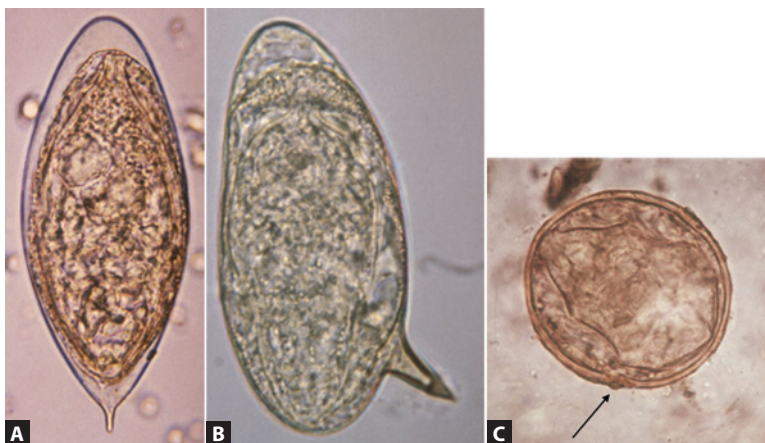
### Antibody Detection

The tests for detection of antibody are useful for sero-epidemiology.

- Two assays are available to detect serum antibodies against *S. haematobium* adult worm microsomal antigen (HAMA).
  - **HAMA-FAST-ELISA** [Falcon assay screening test enzyme-linked immunosorbent assay] is a new test with high sensitivity and specificity
  - **HAMA-EITB** (enzyme-linked immunotransfer blot)
- Other antibody detection methods are—cercarial Huller reaction, indirect fluorescent antibody test (IFA) and indirect hemagglutination (IHA) test
- Immunoglobulin E (IgE) and IgG-4 are elevated in schistosomiasis like any other helminthic infections.

### Antigen Detection

Detection of circulating antigen indicates recent infection and can be used for



**Figs 11.4A to C:** *Schistosoma* eggs (A) *S. haematobium*; (B) *S. mansoni*; (C) *S. japonicum*

Source: A- ID# 4843, B- ID# 4841, C- ID#4842. Public Health Image Library, Centre for Disease Control and prevention (CDC), Atlanta (with permission)

monitoring the treatment response. They are also useful when urine microscopy fails to detect eggs (chronic and ectopic cases).

- Circulating cathodic antigen (CCA) and circulating anodic antigen (CAA) can be detected in serum and urine by ELISA or dip stick assays. CCA levels are much higher in urine than CAA
- ELISA based assay using specific monoclonal antibodies against soluble egg antigen (M Ab-SEA) shows sensitivity of 90% (serum) and 94 % (urine).

Treatment	Schistosoma haematobium
Praziquantel is the drug of choice for the treatment of schistosomiasis (Table 11.4).	

### Prevention

Preventive measures include:

- Proper disposal of human excreta and urine
- Eradication of snails by using molluscicides such as metal salts (iron or aluminium sulfate), metaldehyde, methiocarb and acetylcholine esterase inhibitors
- Treatment of infected persons.

## SCHISTOSOMA MANSONI

*S. mansoni* produces intestinal schistosomiasis in humans.

### Habitat

Adult male and female worms reside in mesenteric veins draining sigmoidorectal region.

### Epidemiology

*S. mansoni* infection is common in Africa including Caribbean Islands (West Indies), South America (Brazil and Argentina), Madagascar, and Arabian Peninsula. No cases are reported from India so far.

### Morphology

- Adult worms are similar to other schistosomes with some minor differences (Table 11.5).
- Nonoperculated eggs have characteristic lateral spine. They measure 110–175  $\mu\text{m}$   $\times$  45–70  $\mu\text{m}$  (Fig. 11.4B and 11.5)
- Fork tailed cercaria is the infective form.

### Life Cycle

Life cycle of *S. mansoni* is similar to *S. haematobium* except:

- Humans are the definitive host; sometimes other vertebrate hosts like monkeys, chimpanzees and dogs may act as reservoir and definitive host
- Fresh water snails of *Biomphalaria* species are intermediate hosts

**Table 11.4:** Drug therapy for human trematode infections

Infection	Drug of choice	Dose and duration (for adults)
<b>Blood flukes</b>		
African schistosomes	Praziquantel	20 mg/kg, two doses in 1 day
Asian schistosomes	Praziquantel	20 mg/kg, three doses in 1 day
<b>Biliary (hepatic) flukes</b>		
<i>Clonorchis sinensis</i> , <i>Opisthorchis viverrini</i> , <i>Opisthorchis felinus</i>	Praziquantel	25 mg/kg, three doses in 1 day
<i>Fasciola hepatica</i> , <i>Fasciola gigantica</i>	Triclabendazole	10 mg/kg once
<b>Intestinal flukes</b>		
<i>Fasciolopsis buski</i> , <i>Heterophyes heterophyes</i>	Praziquantel	25 mg/kg, three doses in 1 day
<b>Lung flukes</b>		
<i>Paragonimus westermani</i>	Praziquantel	25 mg/kg, three doses per day for 2 days

**Table 11.5:** Comparison of species of *Schistosoma*

Features	<i>Schistosoma haematobium</i>	<i>Schistosoma mansoni</i>	<i>Schistosoma japonicum</i>
Habitat of adult worm	Vesical and pelvic venous plexuses	Veins draining sigmoidorectal region	Veins draining ileocecal region
Tegument	Small tubercles	Large papillae with spines	Smooth
Size (male)	15 × 0.9 mm	12 × 0.8–1 mm	15 × 0.5 mm
Size (female)	20 × 0.25 mm	16 × 0.25 mm	22 × 0.3 mm
Number of testes	4–5 in cluster	6–9 in cluster	7 in linear
Uterus	With 20–100 eggs at one time; average 50	Short; few eggs at one time	Long; contain up to 300 eggs; average 50
Egg	Elliptical with sharp terminal spine; 120–170 µm × 40–70 µm	Elliptical with sharp lateral spine; 110–175 µm × 45–70 µm	Oval to almost spherical; rudimentary lateral knob; 70–100 µm × 50–70 µm
Egg discharged in	Urine	Feces	Feces

- The adult worm lives in mesenteric veins draining sigmoidorectal region
- The prepatent period is around 5 weeks (35 days).

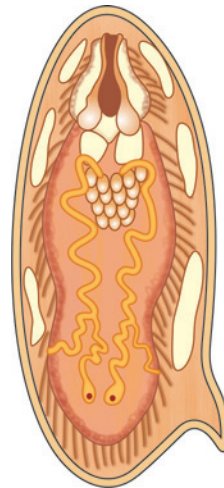
### Pathogenesis and Clinical Feature

In general, the pathogenesis of mansonian schistosomiasis occurs in three stages.

#### Cercarial Dermatitis

After 2 or 3 days of cercarial invasion, an itchy maculopapular rash develops on the affected areas of the skin called as cercarial dermatitis (**swimmer's itch**). This is also observed in *S. japonicum* infection.

Cercarial dermatitis is particularly severe when humans are exposed to avian schistosomes (*Trichobilharzia* species and *Orientobilharzia* species) and mammalian schistosomes (*Gigantobilharzia* species and *Microbilharzia* species). Man being an aberrant host, these parasites don't undergo further development. This condition occurs when a person from non-endemic area visit to an area endemic for these schistosomes. Cercariae die in the skin and evoke severe allergic responses.



**Fig. 11.5:** Lateral spined egg of *Schistosoma mansoni*

#### Acute Schistosomiasis (Katayama Fever)

The acute phase of disease occurs within 4–8 weeks of infection, especially when the schistosomes start producing eggs. It is less common in endemic area.

The antigens (released from eggs) and the adult worms stimulate the host humoral response, leading to the formation of immune



complexes and serum sickness like illness called **Katayama fever**.

It is characterized by fever, generalized lymphadenopathy, and hepatosplenomegaly. Parasite-specific antibodies may be detected. There is a high peripheral blood eosinophilia.

### **Chronic Schistosomiasis**

After eggs are produced, they are trapped in the small venules and are carried into the intestine (or less commonly to bladder) and are excreted in feces. Some are carried through portal circulation into liver and other parts of the body.

#### **Intestinal disease**

The eggs are deposited in the intestinal wall. Soluble antigens liberated from eggs induce inflammatory reactions that lead to granuloma formation around the eggs in the intestine.

Fibrosis and thickening occurs in the intestinal wall along the entire length of colon and rectum.

#### **Hepatosplenic disease**

Granuloma formation and fibrosis in liver (Symmers pipe stem fibrosis) seriously impedes the portal blood flow leading to portal hypertension, hepatomegaly (seen in 15–20%), splenomegaly and gastric varices.

#### **Other body sites**

Pulmonary involvement occurs when eggs are carried and lodged in the lungs by collateral circulation. Egg sequestration and granuloma formation may cause pulmonary emboli formation, pulmonary hypertension and right sided heart failure (cor pulmonale).

- Spinal cord schistosomiasis and myelopathy
- Nephrosclerosis and kidney failure due to circulating immune complexes deposited in glomerular membrane
- Secondary bacterial infection especially with *Salmonella* species.

#### **Laboratory Diagnosis**

*Schistosoma  
mansoni*

- Stool microscopy—detects eggs with lateral spine
  - Wet mount and stool concentration technique
  - Hatching test
  - Kato thick smear technique for egg counting
- Rectal biopsy specimen to detect eggs—histopathology, acid fast stain
- Antigen (such as CCA, CAA, SEA) detection
- Antibody detection—ELISA, EITB

### **Laboratory Diagnosis**

#### **Stool Microscopy**

In acute cases, eggs with lateral spine can be demonstrated in stool or rarely in urine. (Fig. 11.4B).

In chronic cases or in patients with low worm burden, the number of eggs excreted in stool is less and intermittent. Hence, the following ways can be employed to increase the sensitivity

- Multiple stool specimens should be examined
- Stool concentration techniques such as gravity or centrifugal sedimentation should be followed
- **Hatching test:** This involves hatching of motile miracidia when the eggs are diluted in water and perpendicular beam of light is passed through the water at the top
- The quantitation of eggs in stool specimens can be done by Kato thick smear technique.

#### **Rectal Biopsy Specimen**

Histopathological demonstration of lateral spined eggs in biopsy material from rectal mucosa confirms the diagnosis of schistosomiasis.

Egg shell of *S. mansoni* is acid fast and can be stained by modified Ziehl-Neelsen stain.

### Antigen Detection

Similar to *S. haematobium*, various antigens can be detected like CCA in urine and CAA in serum and soluble egg antigen (SEA) in serum.

### Antibody Detection

Similar to *S. haematobium*, ELISA and EITB formats are available to detect serum antibodies.

Treatment	Schistosoma mansoni
<ul style="list-style-type: none"> <li>Praziquantel is the drug of choice. (Table 11.4).</li> <li>Oxamniquine is also very effective.</li> </ul>	

### Prevention

Same that of *S. haematobium*.

## SCHISTOSOMA JAPONICUM

It is the most pathogenic species among the schistosomes.

### Habitat

Adult worms reside in the mesenteric veins draining the ileocecal region.

### Epidemiology

*S. japonicum* infection occurs most commonly in far East including China, Philippines, Japan and Indonesia. Children of 5–10 years of age are commonly affected. No cases are reported from India so far.

### Morphology

Adult worms are similar to other schistosomes (Table 11.5) with the following differences:

- Tegument:** The body surface is smooth
- The eggs are relatively smaller (70–100  $\mu\text{m}$  length  $\times$  50–70  $\mu\text{m}$  width) and more spherical than those of other schistosomes and have rudimentary lateral spine (may be absent in some strains) (Figs 11.6 and 11.4C).

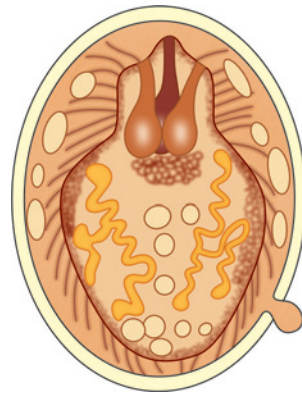


Fig. 11.6: Egg of *Schistosoma japonicum*

### Life Cycle

Life cycle of *S. japonicum* is similar to that of *S. mansoni* with few exceptions:

- Definitive host is mainly man and sometimes domestic animals like cat, dog and cattle
- Intermediate host—snails of *Oncomelania* species
- The prepatent period is around 5 weeks
- Higher egg output:** The female worm lays more than 3,000 eggs/day.

### Pathogenesis and Clinical Features

Pathogenesis is almost similar to that caused by *S. mansoni*. However, the disease is more severe because of the higher egg production and smaller size of the eggs (easy dissemination).

- Cercarial dermatitis
- Katayama fever:** It is seen after 40 days of infection. It is more severe and sometimes leads to death
- Intestinal disease:** Deposition of egg granulomas in the intestinal wall leads to mucosal hyperplasia, ulcers, micro abscess formation and sometimes, pseudopolyposis with blood loss
- Hepatosplenic disease:** Seen due to granulomatous response surrounding the eggs
- Central nervous system (CNS) infection:**

Occurs in 2–4% of cases. Parietal lobe is the most common site. Symptoms include Jacksonian convulsions and grand mal seizures

- **Carcinoma:** Both colorectal carcinoma and liver carcinoma (and cirrhosis) are reported from people of China and Japan infected with *S. japonicum*
- Chronic secondary infection with *Salmonella* species and hepatitis B virus has been associated with *S. japonicum*.

### Laboratory Diagnosis and Treatment

Similar to that of *S. mansoni*.

### Vaccine

Development of an effective vaccine against *S. japonicum* infection is under trial. Recombinant *S. japonicum* paramyosin muscle protein antigen is the most common vaccine candidate used. Promising results were obtained against animal models.

## SCHISTOSOMA INTERCALATUM

*S. intercalatum* infection occurs in the same areas where other African schistosomes are prevalent (Central and West Africa).

- **Clinical features:** Similar to *S. mansoni* like intestinal, hepatosplenic manifestations and secondary *Salmonella* infections
- **Laboratory diagnosis:** Eggs resemble with that of *S. hematobium* with a terminal spine and acid fast but of large size (140–240  $\mu\text{m}$   $\times$  50–85  $\mu\text{m}$ )
- **Treatment:** Praziquantel is the drug of choice.

## SCHISTOSOMA MEKONGI

*S. mekongi* infection occurs in the Mekong river basin of Laos, Thailand and Cambodia.

- Man and dogs are the **definitive hosts**. Snail of the Genus *Neotricula aperta* serve as **intermediate hosts**
- **Clinical features:** It similar to that caused by

### Schistosomiasis in India

- Human schistosomiasis is extremely rare in India. This may be due to many reasons such as—absence of appropriate intermediate host (snails), environmental conditions and host immune mechanisms
- A confirmed endemic focus of urinary schistosomiasis was demonstrated in Gimvi village of Ratnagiri district, Maharashtra in 1952. It was found to be transmitted by snail of genus *Ferrissia*. More than 600 cases were reported mainly affecting people of 10–20 years of age. However, with the help of world Health Organization (WHO), it was eliminated from that place
- **Cercarial dermatitis** has been reported in high proportion in rural/tribal population of Assam, Chhattisgarh and Madhya Pradesh in people using ponds water tanks
- Even cases of **hepatic schistosomiasis** caused by *S. incognitum* were reported by Chandler in 1926
- **Paddy field dermatitis:** Cercarial larvae of many of the avian species can cause dermatitis in the rice field workers and is called as paddy field dermatitis (farmer's dermatitis). Rice field dermatitis is an occupational health problem in Assam (*S. spindalis*), also seen in other countries like Japan, Malaysia and Thailand.

*S. japonicum*, with intestinal, hepatosplenic and brain involvement

- **Laboratory diagnosis:** Eggs are spherical, similar to that of *S. japonicum* except that they are smaller (30–55  $\mu\text{m}$   $\times$  50–65  $\mu\text{m}$ ). Antibody and antigen detection methods are also available similar to that of other schistosomes
- **Treatment:** Praziquantel is the drug of choice.

## LIVER FLUKES

### FASCIOLA HEPATICA

*Fasciola hepatica*, also known as the **common liver fluke** or **sheep liver fluke**. The disease

is called **fascioliasis**. In addition to humans, it also infects sheep and other domestic animals.

### Habitat

The parasite lives in the liver and bile duct.

### Epidemiology

Fascioliasis is a cosmopolitan zoonotic disease with a worldwide prevalence of 17 million cases.

- It is particularly endemic in sheep-raising countries
- Human cases have been reported in South America, Europe, Africa, Australia, and Far East
- **India:** Human fascioliasis in India is extremely uncommon. Only few cases are reported so far, mainly from North and Northeastern India including Assam, Uttar Pradesh and Bihar. Recently few cases are reported from Mumbai and Vellore. Various animal studies indicate that *F. gigantica* is more prevalent in India than *F. hepatica*.

### Morphology

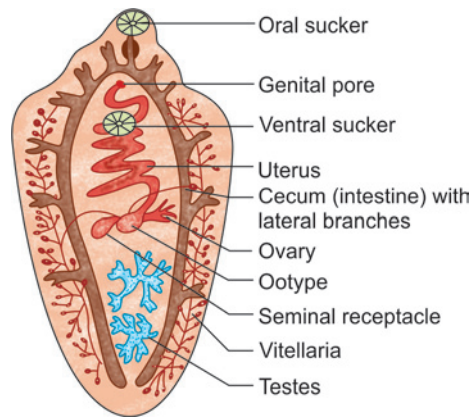
#### Adult Worm

Large in size (3 cm length by 1.2 cm breadth), flat, leaf-shaped, brown colored (Fig. 11.7 and 11.8A).

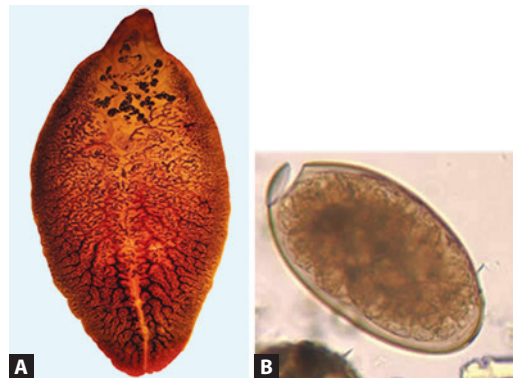
- **Suckers:** The anterior end has a conical projection (shoulder) containing oral sucker while the posterior end is rounded. The ventral sucker is situated away from the oral sucker
- Intestine is bifurcated and incomplete and bears lateral branches
- It is hermaphrodite with both male and female reproductive organs.

#### Egg

Eggs are oval, bile stained, unembryonated and operculated (Fig. 11.8B).



**Fig. 11.7:** Adult worm of *Fasciola hepatica* (schematic diagram)



**Figs 11.8A and B:** *Fasciola hepatica* (A) adult worm; (B) egg

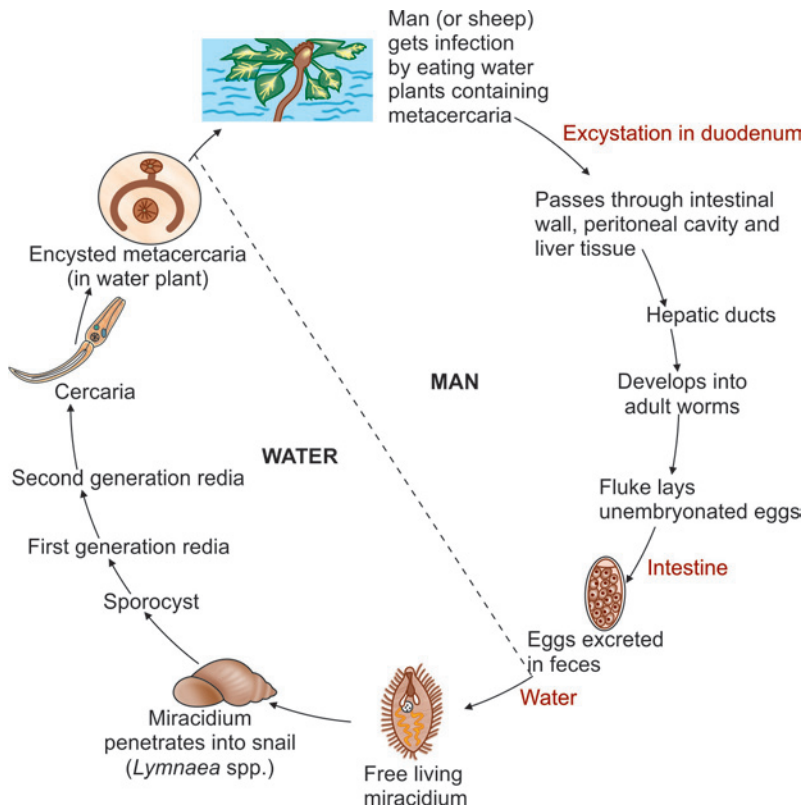
- **Large size:** Measures about 130–150  $\mu\text{m}$  by 60–90  $\mu\text{m}$  size
- The eggs of *F. hepatica* are similar to that of *Fasciolopsis buski* and cannot be differentiated.

#### Larva

Metacercaria larva is the infective form for man and other definitive hosts. Other larval forms are miracidia, rediae and sporocysts.

#### Life Cycle (Fig. 11.9)

**Host:** Sheep is the principal definitive host. Goats cattle and humans are other definitive



**Fig. 11.9:** Life cycle of *Fasciola hepatica*

hosts. The amphibian snails (Genus: *Lymnaea*) are the first intermediate hosts and water plants serve as the second intermediate hosts.

**Mode of transmission:** The sheep and other definitive hosts including man get infection by eating water plants and water cress containing metacercariae.

### Development in Man or Sheep

In duodenum, the metacercariae excyst and penetrate through intestinal wall to reach peritoneal cavity.

- The larvae invade liver tissue and migrate through the liver parenchyma into the hepatic ducts where they mature into adult worms in about 9 weeks of infection
- Inside the hepatic duct the fluke starts laying unembryonated eggs which come

back to the intestine and are excreted in the feces.

### Development in Water

The eggs further develop in water in 1–2 weeks to release miracidium at 22–26°C.

### Development in snails

The miracidium penetrates the suitable snail host. Inside the snail host, the miracidium multiplies and transforms into sporocysts, which further develop into two generations of rediae. Finally, the rediae give rise to cercariae.

### Development in aquatic plants

The cercariae escape from the snails and infect the water plants where they encyst to form

metacercariae. Metacercariae when ingested by the definitive host, cause infection and the cycle is repeated.

## Pathogenesis

Incubation period varies from days to few months.

**Acute disease** develops during metacercarial migration (1–2 weeks after infection) and includes fever, right-upper-quadrant pain, hepatomegaly and eosinophilia. Computed tomography (CT) scan of the liver may show migratory tracks. The adult worm can cause obstruction of the bile duct and dilatation of the biliary tract

In **chronic phase**, the liver parenchyma is inflamed with formation of multiple sub-capsular abscesses (called as **liver rot**). Bile duct obstruction by adult worm and biliary cirrhosis are also reported but less commonly. However, liver malignancy is not associated.

### Laboratory Diagnosis *Fasciola hepatica*

- Stool microscopy—detects operculated eggs
- Antibody detection—ELISA, CIEP, western blot techniques
- Molecular tests—DNA probe, PCR
- USG, CT scan, MRI—detect lesions in liver
- Peripheral blood eosinophilia

## Laboratory Diagnosis

### Stool Microscopy

Typical operculated eggs can be demonstrated in the stool specimen (Fig. 11.8B).

- However, in acute condition stool microscopy is not useful as the worm burden is less. Concentration techniques (sedimentation methods) can be followed to increase the sensitivity. Floatation methods are not useful
- More so, the operculated eggs of *F. hepatica* are similar to that of *F. gigantica*, *F. buski*, *Echinostoma* and *Gastrodiscoides*

- **Spurious infection (pseudofascioliasis):** Sometimes, eggs may be detected in the stool of people who have eaten *F. hepatica* infected liver. This can be differentiated from true infection by stool examination of the patient, 3 days after a liver free diet.

### Antibody Detection

Detection of serum antibodies against excretion secretion antigen helps in early diagnosis before the eggs are detected in stool.

- Various serological tests available are ELISA, counter electrophoresis and western blot techniques
- They are useful for seroepidemiological study and to monitor the response to treatment.

### Molecular Methods

Methods such as DNA probes and polymerase chain reaction (PCR) are available to detect *F. hepatica* specific genes in stool specimens.

### Other Methods

Imaging methods—like ultrasound, CT scan or magnetic resonance imaging (MRI) can be employed to detect the lesions in the liver.

- Peripheral blood eosinophilia
- Elevated serum IgE and IgG4 antibodies.

Treatment	<i>Fasciola hepatica</i>
<ul style="list-style-type: none"> <li>• Triclabendazole (10 mg/kg once) is the drug of choice for fascioliasis</li> <li>• Bithionol and praziquantel are the other alternative drugs.</li> </ul>	

## Prevention

Fascioliasis can be prevented by:

- Avoidance of consumption of raw water plants and cleaning them before use
- Control of snails
- Health education
- Treatment of infected person.



## ■ FASCIOLA GIGANTICA

It is closely related to *F. hepatica*.

- It is seen in tropics and aquatic environment and is the predominant species in Africa and some Pacific Islands
- It is a common parasite of herbivores like cattle and camels. Human infection is also reported but rarely
- **Life cycle:** Similar to that of *F. hepatica*. Only difference is first intermediate host is aquatic snail (in contrast to amphibian snail for *F. hepatica*)
- **Clinical feature:** Similar to that of *F. hepatica*, characterized by hepatomegaly and abdominal pain
- **Laboratory diagnosis:** Eggs are morphologically similar to that of *F. hepatica* and *F. buski*, but larger in size ( $160\text{--}190\ \mu\text{m} \times 70\text{--}90\ \mu\text{m}$ )
- **Treatment:** Same as that of *F. hepatica*.

## ■ CLONORCHIS SINENSIS

*Clonorchis sinensis* is also called **Chinese liver fluke**. McConnell was the first to describe the adult worm and the pathologic changes in a Chinese patient who died in a medical college, Kolkata, India in 1875.

### Habitat

Adult worm lives in the bile duct, pancreatic duct and common bile duct of man and other domestic animals.

### Epidemiology

*C. sinensis* is found primarily in Eastern Asia like China, Korea, Japan and Malaysia, infects over 35 million people globally. However, infections from India are not reported so far though the first case was detected from Kolkata.

### Morphology

#### Adult worm

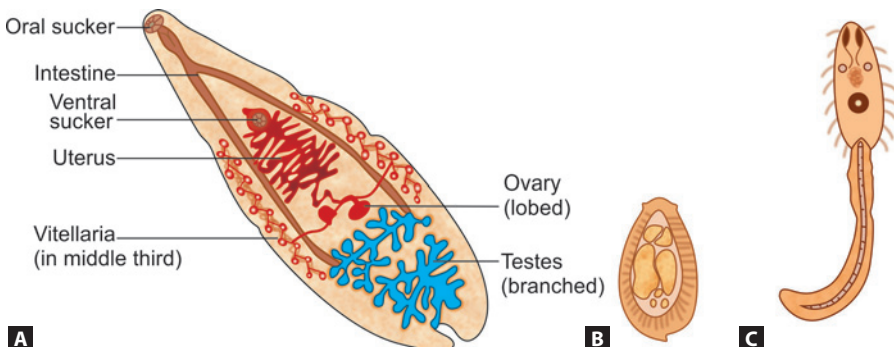
Adult worms are dorsoventrally flattened, elongated, lancet-shaped, measure 10–20 mm in length and 3–5 mm in width. The characteristic distinguishing feature is the presence of two deeply lobulated and branched testes one behind another. The uterus is situated anteriorly. The fluke can survive in the biliary tract for as long as 30 years (Figs 11.10A and 11.11A).

#### Egg

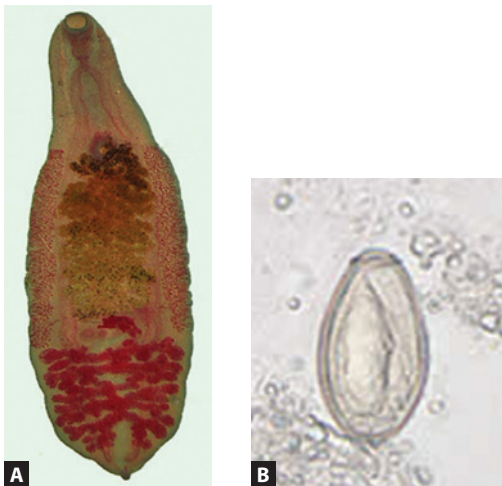The eggs measure  $28\text{--}35\ \mu\text{m} \times 12\text{--}19\ \mu\text{m}$  and are characterized by a distinct operculum with a prominent shoulders and a tiny knob at the posterior pole (flask shaped appearance), excreted in the stool (Figs 11.10B and 11.11B).

#### Larva

Metacercaria is the infective form of the parasite. It is found in the flesh of the fresh water fish. Other larval stages are cercaria (Fig. 11.10C), redia, sporocyst and miracidium.



**Figs 11.10A to C:** *Clonorchis sinensis* (schematic diagram) (A) adult worm; (B) egg; (C) cercaria larva



**Figs 11.11A and B:** *Clonorchis sinensis* real image (A) adult worm (carmine stained); (B) egg (saline mount)

Source: DPDx Image Library, Centre for Disease

Control and prevention (CDC), Atlanta (with permission)

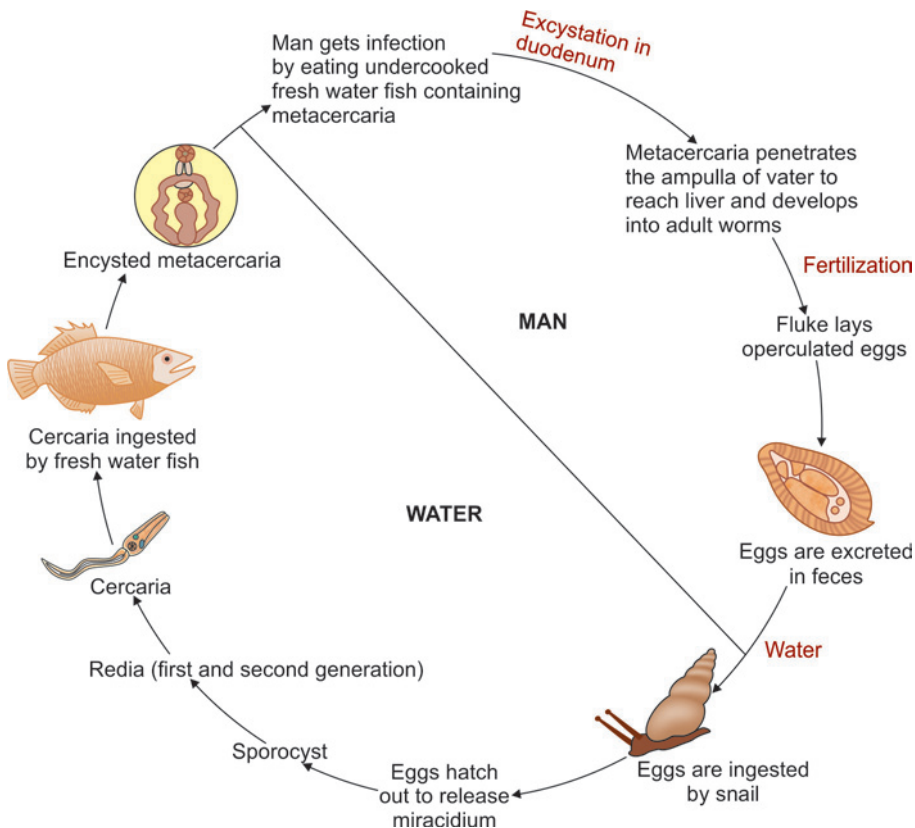
### Life Cycle (Fig. 11.12)

**Hosts:** Man and other domestic or wild animals (like dogs, pigs, cats, minks, weasels and rats) act as definitive hosts. It requires two intermediate hosts—first fresh water snail and second fresh water fish of family Cyprinidae.

**Mode of transmission:** Man acquires infection by eating undercooked fresh water fish harboring metacercariae.

### Development in Man

The metacercariae excyst in the duodenum and penetrate the intestine to reach the liver. They enter the biliary capillaries, mature into adult worms and start laying operculated eggs. The fully embryonated eggs are released into the duodenum and excreted in the feces. Human cycle takes around 3 months.



**Fig. 11.12:** Life cycle of *Clonorchis sinensis*

**Development in Snail**

In contrast to other trematodes, *Clonorchis* egg hatches out inside the snail (not in water) to release miracidium which then penetrates the intestine of snail and reaches the vascular space. Miracidium multiplies and passes through single generation of sporocyst and two generations of rediae and finally converts into cercaria.

**Development in Fish**

Cercariae escape from the snail host and infect the fresh water fish. After 3 weeks, cercariae transform into metacercariae. When the infected fishes are ingested by definitive hosts, the life cycle is repeated.

**Pathogenesis**

**In light worm burden:** People are usually asymptomatic

**In chronic infection with heavy worm burden:**

- Mechanical obstruction of the bile duct and irritation due to toxin released by the flukes leads to cholangitis, dilatation of the bile duct and bile retention
- There is marked ductal epithelial hyperplasia, periductal inflammation and fibrosis
- In some cases adenomatous hyperplasia of the ductal epithelium is seen
- **Bile duct carcinoma:** Chronic irritation of the bile duct for long periods can lead to **cholangiocarcinoma**. Risk factors for the bile duct carcinoma include elderly people (60–80 years old) and pre-existing primary sclerosing cholangitis.

**Laboratory Diagnosis**     *Clonorchis sinensis*

- Stool microscopy—Detects flask shaped operculated eggs
- Serodiagnosis—CFT, IHA, ELISA for antibody detection, ELISA for antigen detection
- Molecular methods—Multiplex PCR

**Laboratory Diagnosis**

**Stool Microscopy**

Demonstration of the characteristic flask shaped eggs in the stool establishes the diagnosis. Microscopy of the duodenal aspirate is more sensitive than stool microscopy. Formalin-ether concentration should be done when egg burden is low. However, the eggs of *C. sinensis* are morphologically similar to that of *Opisthorchis*, *Heterophyes*, and *Metagonimus*.

**Serodiagnosis**

Various serological tests like CFT, indirect hemagglutination test and ELISA are used to detect the antibodies in the serum. ELISA for circulating antigen in the serum is also available. Detection of antigen is more useful as it indicates current infection

**Molecular Methods**

A multiplex PCR has been developed to detect *Clonorchis* and *Opisthorchis* simultaneously. It is rapid with high sensitivity and specificity.

Treatment	<i>Clonorchis sinensis</i>
Praziquantel (25 mg/kg, three doses in 1 day) is the drug of choice for clonorchiasis.	

**Prevention**

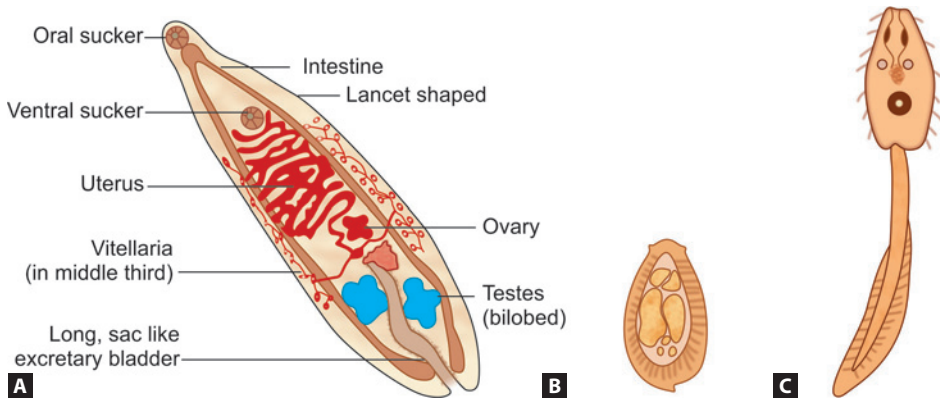
- Clonorchiasis can be prevented by:
- Avoidance of eating raw or undercooked fresh water fish
  - Sanitary disposal of stool and sewage
  - Control of snail hosts.

**OPISTHORCHIS VIVERRINI**

**Epidemiology**

*O. viverrini* has been reported from South-east Asia, mainly from Laos, Thailand and Cambodia.

More than 10 million people are infected globally with a prevalence of 35%. In certain places, prevalence is up to 90%.



**Figs 11.13A to C:** *Opisthorchis viverrini* schematic diagram (A) adult worm; (B) egg; (C) cercaria

## Morphology

### Adult Worm

It is elongated and dorsoventrally flattened similar to that of *C. sinensis* except that it is smaller (8–12 mm in length). It has a lifespan of 20 years (Fig. 11.13A and 11.14A).

### Eggs

Measure  $27\ \mu\text{m} \times 15\ \mu\text{m}$ , flask shaped with an operculum and a knob, similar to that of *C. sinensis* (Fig. 11.13B and 11.14B).

### Larvae

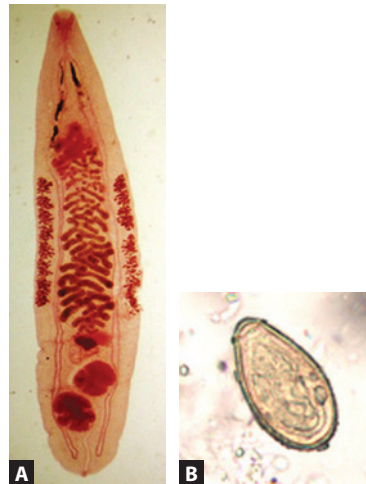
Metacercaria is the infective form of the parasite. It is found in the flesh of the fresh water fish. Other larval stages are cercaria (Fig. 11.13C), redia, sporocyst and miracidium.

## Life Cycle

Similar to that of *C. sinensis*.

**Host:** Man and other domestic or wild animals like dogs and cats are definitive hosts. It requires two intermediate hosts; first fresh water snail and second-fresh water fish of family Cyprinidae.

**Mode of transmission:** Man acquires infection by eating undercooked fresh water fish harboring metacercariae.



**Figs 11.14A to B:** *Opisthorchis viverrini* (A) adult worm (carmine stained); (B) egg (saline mount)

Source: DPDx Image Library, Centre for Disease Control and prevention (CDC), Atlanta (with permission)

## Pathogenicity

Pathogenicity is related to the multiplication of adult flukes in the hepatobiliary system that leads to chronic mechanical obstruction and inflammation of the bile duct.

### Cholangiocarcinoma

Various reasons may contribute to the development of cholangiocarcinoma such as:

- Obstruction and irritation of the bile duct by the adult flukes
- Chronic inflammatory changes in the bile duct leading to ductal epithelial cell dysplasia
- Generation of active toxic radicals
- Functional loss of tumor suppressor genes
- Activation of oncogenes
- Altered cellular detoxification mechanisms
- Use of tobacco in betel nut and cigarettes
- Intake of nitrosamine in food.

**Liver Cancer**

Few reports of hepatocellular carcinoma are also reported mainly from the Northeastern Thailand.

**Other Hepatobiliary Manifestations**

- Hepatomegaly
- Cirrhosis
- Cholecystitis
- Cholangitis
- Obstructive jaundice
- Secondary bacterial infection.

**Laboratory Diagnosis**     *Opisthorchis viverrini*

- Stool microscopy—detects flask-shaped eggs
- DNA hybridization
- Antigen detection

**Laboratory Diagnosis**

**Stool Microscopy**

Multiple stool examination can be carried out to detect the characteristic flask shaped eggs. Sedimentation techniques are followed for stool concentration. The eggs are similar to that of *C. sinensis*, *Heterophyes* and *Metagonimus*; hence reliable diagnosis depends on recovery of the adult worm, patient history and geographical area.

DNA hybridization and detection of antigen have been used to detect the parasite in the stool.

Treatment	<i>Opisthorchis viverrini</i>
Praziquantel (25 mg/kg, three doses in 1 day) is the drug of choice.	

**OPISTHORCHIS FELINEUS**

- *Opisthorchis felineus* is also known as **cat liver fluke**
- Infection is limited to Central and Eastern Europe, Russia and Kazakhstan
- **Morphology:** Similar to that of *O. viverrini* Adult worm measures 7–12 mm long, eggs are operculated and measure 30 µm × 11 µm size
- Man and other feline animals (cat and dog) act as **definitive host**. Snail (Genus-*Bithynia*) is the **first intermediate host** while fresh water fishes of crab family serve as second **intermediate host**
- Clinical disease, diagnosis, and treatment similar to that of *O. viverrini*.

**INTESTINAL FLUKES**

**FASCIOLOPSIS BUSKI**

It is also known as **giant intestinal fluke**. It is the largest and the most common intestinal fluke infecting man. It was first noted by Busk in 1843 in the duodenum of an East Indian sailor.

**Habitat**

It is found in the mucosa of duodenum and jejunum of man and pig.

**Epidemiology**

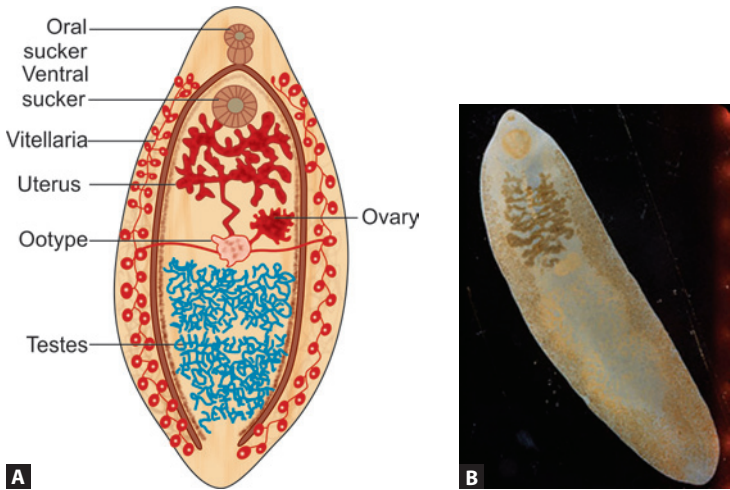
*F. buski* is mainly endemic in Southeast Asian countries such as India, China, Pakistan, Bangladesh, Thailand and Malaysia.

- Risk factors include poverty, unhygienic socio-cultural practices, food habits and availability of open type of pig farms
- **India:** Prevalence of *F. buski* may be as high



**Table 11.6:** Differences between adult worm of *Fasciola hepatica* and *Fasciolopsis buski*

Properties	<i>Fasciola hepatica</i>	<i>Fasciolopsis buski</i>
Size	Smaller (3 cm)	Bigger (2–7.5 cm)
Anterior end (shoulder)	Bears cephalic cone	Doesn't have cephalic cone
Oral and ventral suckers	Well separated	Lie close to each other
Intestinal caeca	Bear lateral branches	Don't have lateral branches



**Figs 11.15A and B:** *Fasciolopsis buski* (A) schematic diagram; (B) carmine stained  
Source: B DPDx Image Library, Centre for Disease Control and prevention (CDC), Atlanta (with permission)

as 22.4% in India. It has been reported from various states like Assam, Uttar Pradesh, Bihar, Odisha, Madhya Pradesh and West Bengal.

Morphology

Adult Worm

The adult worm measures 2–7.5 cm in length and 0.8–2 cm in breadth.

- It is fleshy with broad anterior end but does not have cephalic cone which is present in *F. hepatica* (Table 11.6).
- It has two suckers, ventral and oral, present close to each other. (Fig. 11.15).
- It is a hermaphrodite.

Eggs

Eggs are large (130–140  $\mu\text{m} \times 80\text{--}85 \mu\text{m}$  size),

operculated and bile stained eggs, similar to that of *F. hepatica*.

Larvae

Metacercaria is the infective form to man and pig.

Life Cycle (Fig. 11.16)

The life cycle is similar to that of *F. hepatica*.

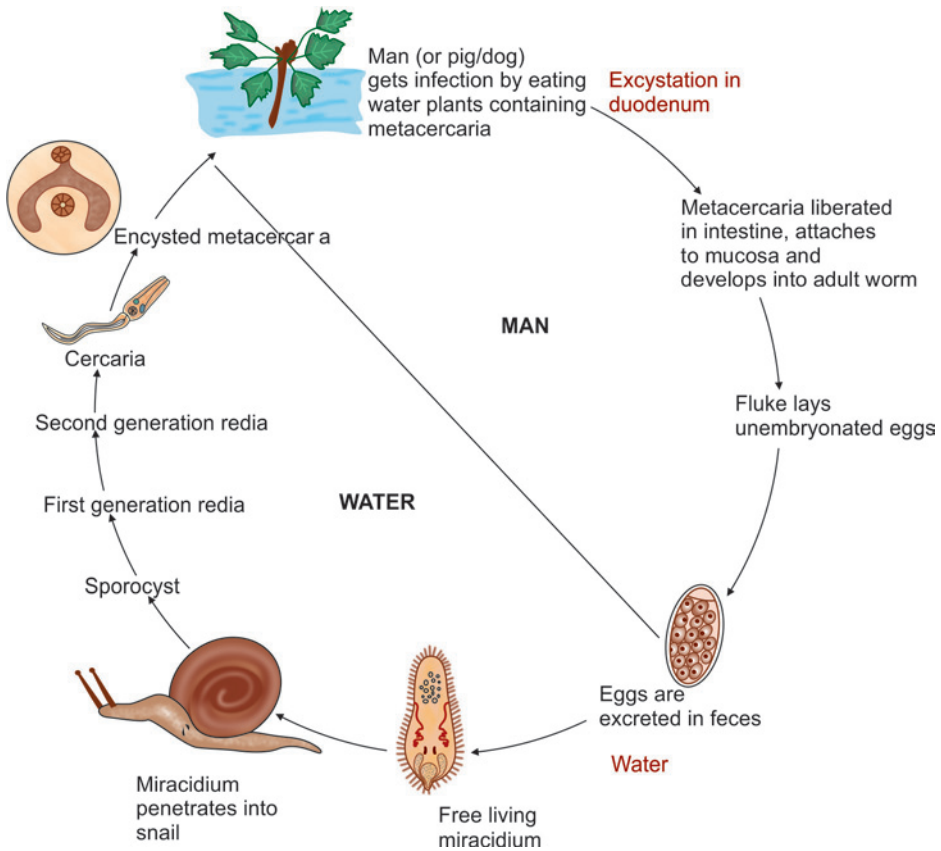
**Host:** It completes its life cycle in one definitive host (pig or man) and two intermediate hosts (first—snail of Genera *Segmentina* and *Hippeutis*, second—aquatic plants).

**Modes of transmission:** Humans acquire infection by eating contaminated water plants.

Development in Man/Pigs

The larvae develop into adult worm in the





**Fig. 11.16:** Life cycle of *Fasciolopsis buski*

intestine which lays unembryonated eggs which are excreted in feces.

### Development in Water

The eggs mature and hatch to release miracidia which infect the snails.

### Development in snails

The larvae undergo various stages of developments such as sporocysts, rediae (two generations) and cercariae

### Development in aquatic plants

The cercariae escape from snails and encyst to metacercariae on the surface of water plants. On ingestion of plants by man or pig, the cycle is repeated.

### Pathogenesis

The main pathogenesis is due to the traumatic and obstructive damage to the intestine.

- **Light infection:** It may be asymptomatic or its attachment to intestinal mucosa leads to local inflammation, ulcerations with mucus and blood in stool
- **In severe infection:** There may be partial obstruction of intestinal tract
- Malabsorption and protein losing enteropathy may be seen with profuse yellowish green stool
- Marked eosinophilia and leukocytosis are commonly observed.

### Laboratory Diagnosis Fasciolopsis buski

- Stool microscopy (by wet mount and sedimentation concentration technique)—detects operculated eggs

### Laboratory Diagnosis

Detection of large number of operculated eggs in the stool sample gives probable diagnosis of *F. buski*.

- Sedimentation methods are recommended for stool concentration when worm load is less
- However, the operculated eggs of *F. hepatica*, *Echinostoma* and *Gastrodiscoides* are morphologically similar to that of *F. buski*
- Definitive identification can be done only after identification of the adult worm.

### Treatment Fasciolopsis buski

- Praziquantel is the drug of choice. It is given as 25 mg/kg, three doses in 1 day
- Niclosamide is given alternatively.

## OTHER LESS COMMON INTESTINAL TREMATODES

### Gastrodiscoides hominis

It was discovered from India by Lewis and McConnell in 1880.

- **Habitat:** The adult worm lives in the cecum and ascending colon of pigs, monkeys and also man
- **Epidemiology:** *G. hominis* is reported mainly from India (Assam and other states like Bihar and Odisha), China and Vietnam. Recently cases from Africa are also reported. In some parts of India, the prevalence may be as high as 41%
- **Morphology:** Adult worms are bright pink and measure 8–14 mm long and 4–5 mm wide, pyriform-shaped, with a conical anterior portion and hemispherical posterior portion. Oral sucker is near the anterior end while the ventral sucker

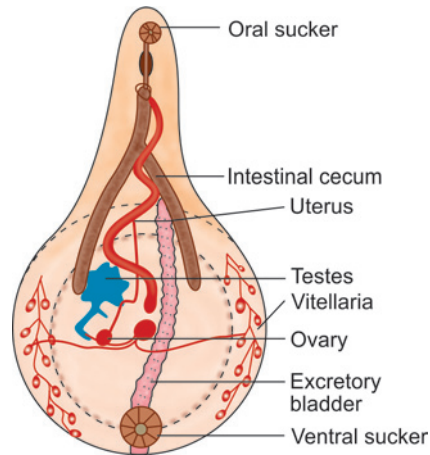


Fig. 11.17: Adult worm of *Gastrodiscoides hominis*

is located at the posterior end. A large excretory bladder is located near the midline behind the ventral suckers (Fig. 11.17)

- Eggs are operculated, similar to *F. buski*, measures  $150\ \mu\text{m} \times 60\text{--}70\ \mu\text{m}$  size
- **Life cycle:** It is similar to *F. buski*. Humans are the **definitive hosts**. Snails (Genus: *Helicorbis coenosus* in India) are the **first intermediate hosts** and aquatic plants serve as **second intermediate host**
- **Clinical feature:** Light infection is asymptomatic where as heavy infection may cause mucus diarrhea and other intestinal symptoms.
- **Laboratory diagnosis:** Stool microscopy is done to demonstrate of operculated eggs in stool
- Praziquantel is the drug of choice.

### Watsonius watsoni

It is mainly a parasite of monkeys; human infection is rare.

- Few cases are reported from West Indies and other African countries
- Adult worms are located in the small intestine. They measure 8–10 mm long and 4–5 mm wide. Ventral sucker is located posteriorly

- Eggs are operculated, measure  $125\text{--}130\text{ }\mu\text{m} \times 75\text{--}80\text{ }\mu\text{m}$  size
- Life cycle is not known. Infection probably occurs by ingestion of plants containing metacercariae
- Clinical feature, diagnosis and treatment—Similar to that of *G. hominis*.

### Heterophyes heterophyes

It was reported by Bilharz in 1851.

- **Habitat:** The adult worm lives in the small intestine (jejunum and upper ileum) of man and many fish eating mammals like dogs, cats and birds
- **Epidemiology:** *Heterophyes heterophyes* is reported mainly from China, Egypt, India, Japan, Korea, and Sudan
- **Morphology:** Adult worm measures 1–1.7 mm, grey with a round broad posterior end and possesses three suckers—oral, ventral (situated left side) and a genital sucker surrounding the genital pore (Fig. 11.18).
- Eggs are operculated and smaller measure  $27\text{--}30\text{ }\mu\text{m} \times 15\text{--}17\text{ }\mu\text{m}$  size
- **Life cycle:** It is similar to that of any intestinal trematode. Humans (or other mammals) are the **definitive host**. Snails are the **first intermediate host** and brackish water fishes (Genus: *Mugil capito*) serve as **second intermediate host**

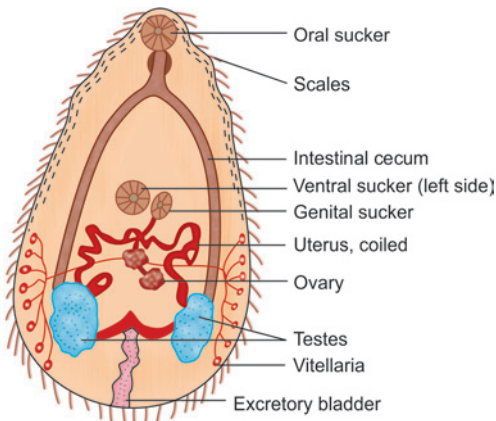


Fig. 11.18: Adult worm of *Heterophyes heterophyes*

- **Clinical feature:** Light infection is asymptomatic where as heavy infection may cause mucus diarrhea, intestinal ulcers and abdominal pain
- **Laboratory diagnosis:** It is done by demonstration of operculated eggs. However, the eggs of *H. heterophyes* are morphologically similar to that of *M. yokogawai* and *C. sinensis*.
- Praziquantel is the drug of choice.

### Metagonimus yokogawai

- **Epidemiology:** *M. yokogawai* is considered as the most common intestinal fluke in Far East; most of the cases are reported from China, Japan, Indonesia, Israel and Taiwan
- **Habitat:** The adult worm lives in the small intestine
- **Morphology:** Adult worms are similar to that of *H. heterophyes* except slightly larger in size (1–2.5 mm long), ventral sucker is situated on the right side of the midline and there is no genital sucker (Fig. 11.19)
- Eggs are operculated and smaller, measure  $26\text{--}28\text{ }\mu\text{m} \times 15\text{--}17\text{ }\mu\text{m}$  size
- **Life cycle:** It is similar to that of any intestinal trematode. Humans (fish eating mammals like dogs, cats and birds) are the definitive hosts. Fresh water snails (*Semisulcospira* species) are the first intermediate host and

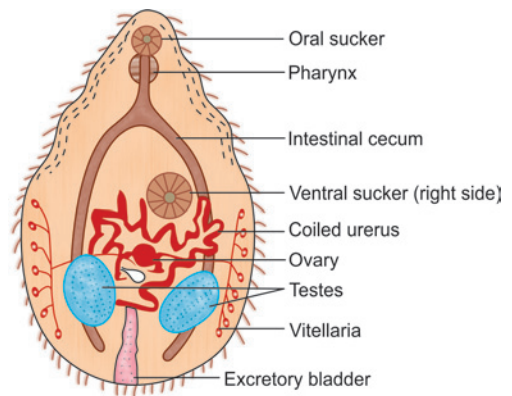


Fig. 11.19: Adult worm of *Metagonimus yokogawai*

freshwater fishes (Genus- Mugil) serve as second intermediate host

- Clinical features, diagnosis and treatment are similar to that of *H. heterophyes*

### Echinostoma ilocanum

- **Habitat:** The adult worm lives in the small intestine of rats and dogs. Human infection is rare.
- **Epidemiology:** It is mainly reported from China, Indonesia, Thailand, Taiwan and Philippines.
- **Morphology:** Adult worms are reddish gray and measure less than 2 cm long and the oral sucker is surrounded by a crown of spine present near the anterior end.

Eggs are ellipsoidal and operculated and measure 86–116  $\mu\text{m}$   $\times$  58–69  $\mu\text{m}$  size.

- **Life cycle:** It is similar to that of any intestinal trematode.
- Clinical feature, diagnosis and treatment are similar to that of *H. heterophyes*.

## LUNG FLUKE

### ■ PARAGONIMUS WESTERMANI

*Paragonimus westermani* is also known as **oriental lung fluke**. It causes endemic hemoptysis in man. Naterer was the first to describe the parasite in 1828.

#### Epidemiology

More than 40 species of *Paragonimus* are recognized as parasites of mammals; however, only 10 species infect humans with a global prevalence of 22 million.

- It is endemic in many parts of the world, except North America and Europe
- *P. westermani* is the most important species infecting humans, found in the Far East, principally Korea, Japan, Taiwan, China, and the Philippines
- The other species are *P. miyazaki* (Japan), *P. skrjabini* and *P. hueitungensis* (China), *P. heterotrema* (China, Southeast Asia), *P. uterobilateralis*, *P. africanus* (Central and

West Africa), *P. mexicanus* (Central and South America), and *P. kellicotti* (North America)

- **India:** Paragonimiasis is endemic in North East states of India. Many cases are reported from **Manipur** with a prevalence of 6.7%. Earlier, *P. westermani* was thought to be the causative agent of paragonimiasis in Manipur. However, according to the recent studies, *P. heterotremus* may be the responsible for paragonimiasis in Manipur.

#### Habitat

The adult worm lives in the parenchyma of lung.

#### Morphology

##### Adult Worm

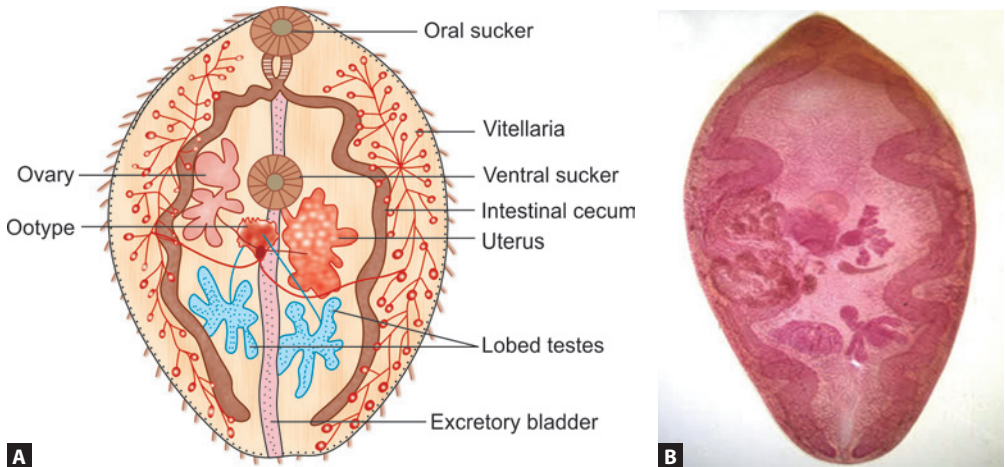
- It is thick, fleshy (plump) and reddish brown in color
- It measures up to 16 mm in length, 8 mm in breadth
- The fluke is oval in shape with broader anterior end
- Tegument is covered throughout by spines like scale
- The oral sucker is situated anteriorly and ventral sucker situated in the middle of the body (Fig. 11.20)
- The excretory bladder is large and divides the body of worm into two equal halves
- The parasite is hermaphrodite with two irregularly deep lobed testes at posterior end (Fig. 11.20).

#### Eggs

The eggs are oval, operculated and golden-brown in color and measures 80–120  $\mu\text{m}$   $\times$  45–65  $\mu\text{m}$ . They are unembryonated when laid (Figs 11.21, 11.22).

#### Larvae

Metacercaria is the infective form of the parasite. It is present in the flesh of second



**Figs 11.20A and B:** *Paragonimus westermani* adult worm (A) schematic diagram; (B) carmine stained  
 Source: B DPDx Image Library, Centre for Disease Control and prevention (CDC), Atlanta (with permission)

intermediate host (crab or gray fish).

Other larval stages are cercaria, redia, sporocyst and miracidium.

### Life Cycle (Fig. 11.21)

**Host:** *P. westermani* completes its life cycle in one definitive host (man, or dogs and cats) and two intermediate hosts: first—snail (Genus: *Melania* or *Semisulcospira* and *Brotia* species), second—crabs or cray fishes.

**Mode of transmission:** Man acquires infection by eating uncooked, partially cooked, salted, or pickled crab or cray fish (second intermediate host) containing metacercariae.

### Development in Man

In the small intestine, the larvae (metacercariae) escape out and penetrate the intestinal wall to reach peritoneal cavity. Then they pierce the diaphragm to reach the lung parenchyma and settle near to the bronchus. The larvae mature into adult worms, which start laying unembryonated eggs that are coughed out in sputum. The eggs are swallowed and excreted in feces in 5–6 weeks after the onset of infection.

### Development in Water

The further development of eggs takes place in the water where miracidia hatch out from the eggs in 2–3 weeks at 29–31°C.

### Development in snail

The miracidium released from each egg infects the snail, undergoes asexual multiplication to produce sporocysts. The sporocysts through two generations of rediae give rise to stumpy-tailed cercariae in 3–5 months.

### Development in crab or crayfish

The mature cercariae escape from snail host and are ingested by crabs or crayfishes. Cercariae encyst to form metacercariae which when ingested by man, the cycle is repeated.

### Pathogenesis

Metacercariae penetrate the intestinal wall and migrate to the abdominal cavity. This may cause abdominal tenderness, nausea and vomiting. Then they migrate to lungs and develop to adult worms that cause pulmonary paragonimiasis.

### Pulmonary Paragonimiasis

The adult worm initially causes eosinophilic granulomatous inflammation in the lungs



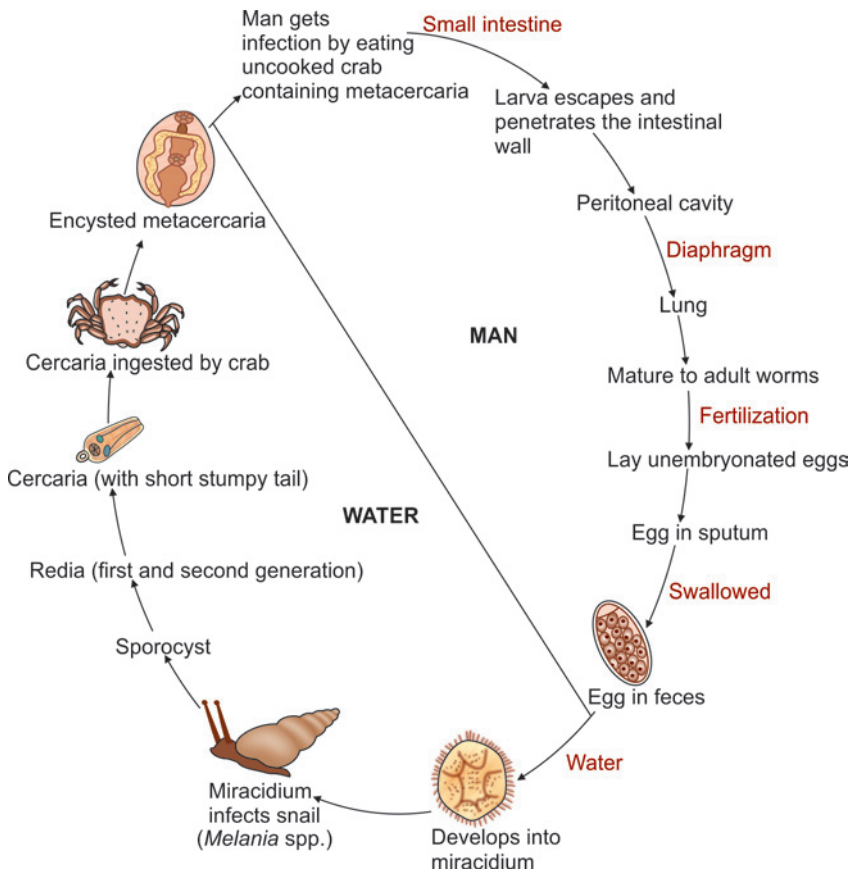


Fig. 11.21: Life cycle of *Paragonimus westermani*

which leads to the formation of encapsulating fibrotic capsules or cysts surrounding the worms. The cysts are commonly found on the right lung.

- The cysts are about 1 cm in diameter and contain blood mixed thick purulent fluid containing one or more flukes and golden brown eggs. When cysts break up into bronchioles, the blood mixed sputum is expectorated
- Symptoms appear with moderate to heavy infection. The common presenting features are productive cough with brownish blood tinged rusty sputum with an offensive fishy odor
- Sometimes, frank hemoptysis occurs along with peripheral blood eosinophilia
- In chronic cases, bronchitis or bronchiec-

tasis or pneumonia leading to lung abscess may be seen.

### Extrapulmonary Paragonimiasis

The worms migrate from the ruptured cysts to various sites such as liver, spleen, abdominal wall and less commonly in brain.

- Extrapulmonary infections are usually associated with *P. mexicanus*, *P. heterotremus* and occasionally with *P. westermani*.
- **Cerebral paragonimiasis:** It is the most severe form of paragonimiasis. Encapsulated cysts in the brain parenchyma present as space-occupying lesions. Symptoms include fever, headache, vomiting, motor weakness or epilepsy
- **Cutaneous paragonimiasis:** Migratory



subcutaneous nodules may be seen in 20–60% of *P. skrjabini* and 10% of *P. westermani* infected patients. They form tender nodules which vary from few millimeter to 10 cm.

#### Laboratory Diagnosis

*Paragonimus westermani*

- Sputum microscopy—detects operculated eggs
- Serological tests—antibody detection (CFT, ELISA), antigen detection (Dot ELISA)
- MRI, CT scan, X-ray—detect lesions in lungs and other organs
- Peripheral blood eosinophilia

### Laboratory Diagnosis

#### Sputum Microscopy

Early morning, deeply coughed sputum sample is collected for microscopy. The saline mount of sputum sample is examined for characteristic operculated eggs. Histopathological stains can also be used (Fig. 11.22)

If the egg burden is less, then:

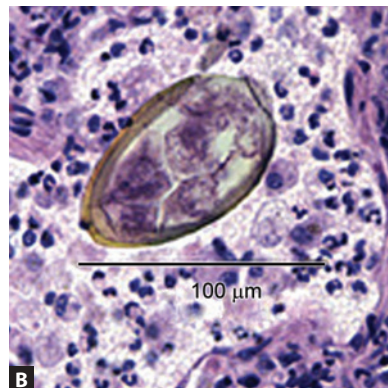
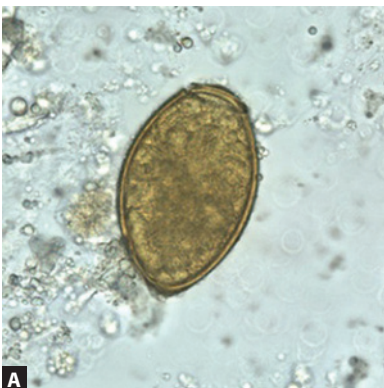- Multiple sputum examination (up to seven samples) should be done
- Sputum can be concentrated by formalin-ether sedimentation technique

- Mucoid sputum can be liquefied by mucolytic agents like sodium hydroxide
- Stool microscopy may be done in children as the collection of sputum is difficult in them.

### Serological Tests

Serological tests are useful in the early part of the disease, where the microscopy has failed to detect eggs in sputum and stool and also for epidemiological purpose.

- **Antibody detection:** Detection of serum antibodies to *P. westermani* can be done by:
  - Complement fixation test (CFT) (positive in active infection but soon becomes negative after the death of the worms)
  - Indirect hemagglutination (IHA) test and latex agglutination test
  - ELISA using purified adult excretory-secretory antigen to detect parasite specific IgG or IgE has shown a high sensitivity especially with pleural fluid than serum
  - Western blot test using adult worm homogenate is also highly sensitive and specific
- **Antigen detection:** Dot ELISA format has been developed to detect species specific and stage specific antigens by using monoclonal antibodies. Detection of antigens indicates active infection.



**Figs 11.22A and B:** Eggs of *Paragonimus* species (A) sputum—wet mount; (B) lung biopsy—stained with hematoxylin and eosin

Source: DPDx Image Library, Centre for Disease Control and prevention (CDC), Atlanta (with permission)

Treatment	Paragonimus westermani
<ul style="list-style-type: none"> <li>• Praziquantel (25 mg/kg, three doses per day for 2 days) is the drug of choice for treatment of paragonimiasis</li> <li>• Bithionol and niclofolan can also be used with 100% cure rate without any side effects</li> <li>• Surgical management may be needed for pulmonary or cerebral lesions</li> </ul>	

### Other Tests

- Peripheral blood eosinophilia
- **Radiological tests:** MRI and CT scan

are preferred to locate the cysts in the CNS or other sites. Even Chest X-ray may demonstrate the characteristic pulmonary lesions, including patchy densities, cavities, pleural effusion.

### Prevention

Paragonimiasis can be prevented by:

- Sanitary disposal of sputum
- Control of snails
- Treatment of cases
- Health education.

## EXPECTED QUESTIONS

### I. Write essay on:

- (a) Describe the life cycle, pathogenesis and laboratory diagnosis of *Schistosoma haematobium*?

### II. Write short notes on:

- (a) Cercarial dermatitis (swimmer's itch)
- (b) *Clonorchis sinensis*
- (c) *Fasciola hepatica*
- (d) Lung fluke

### III. Differentiate between:

- (a) *Schistosoma haematobium* and *Schistosoma mansoni*
- (b) Adult worm of *Fasciola hepatica* and *Fasciolopsis buski*

### IV. Multiple choice questions (MCQs):

#### 1. Which of the following is the largest trematode?

- (a) *Fasciola hepatica*
- (b) *Fasciolopsis buski*
- (c) *Clonorchis sinensis*
- (d) *Schistosoma haematobium*

#### 2. Which of the following is called as lung fluke?

- (a) *Clonorchis sinensis*
- (b) *Ascaris lumbricoides*
- (c) *Strongyloides stercoralis*
- (d) *Paragonimus westermani*

#### 3. Carcinoma of urinary bladder is associated with which of the following parasites?

- (a) *Schistosoma japonicum*
- (b) *Schistosoma mansoni*
- (c) *Schistosoma haematobium*
- (d) *Schistosoma intercalatum*

#### 4. In which of the following trematode, the sexes are separate?

- (a) *Schistosoma haematobium*
- (b) *Clonorchis sinensis*
- (c) *Fasciolopsis buski*
- (d) *Paragonimus westermani*

#### 5. Chinese liver fluke is the common name of:

- (a) *Fasciola hepatica*
- (b) *Fasciola gigantica*
- (c) *Clonorchis sinensis*
- (d) *Fasciolopsis buski*

### Answer

1. (b) 2. (d) 3. (c) 4. (a) 5. (c)

# 12 Nematodes—I (Intestinal Nematodes)

## Chapter Outline

- General properties of nematodes
- Classification
- General description
- Large intestinal nematodes
  - *Trichuris trichiura*
  - *Enterobius vermicularis*
- Small intestinal nematodes
  - Hookworm
  - *Strongyloides* species
  - *Ascaris* species
- Expected questions

## GENERAL PROPERTIES OF NEMATODES

Nematodes are probably the most widespread animal group occurring in the world. Many of them are non pathogenic and exist as free living forms in fresh or marine water and soil while few of the species can be pathogenic and exist as parasitic form in both animals and plants.

## CLASSIFICATION

### Systemic Classification

Systemic classification is based on Anderson et al. (1974) classification. Phylum Nematoda has two classes Adenophorea and Secernentea which are different in many ways (Table 12.1 and 12.2).

**Table 12.1:** Differences between class Adenophorea and Secernentea

Characteristics	Class Adenophorea	Class Secernentea
Sensory structure (phasmids)	Absent	Present
Esophagus	Modified with the presence of: <ul style="list-style-type: none"><li>• Gland cells (stichocytes) or</li><li>• Reserve organ (trophosome)</li></ul>	Normal appearance
Excretory organs	Without lateral canals	Lateral canals present
Caudal papillae	Absent	Present
Infective form to the definitive host	First stage larva ( <i>Trichinella</i> ) or embryonated eggs ( <i>Trichuris</i> )	Third stage larva or embryonated eggs

**Table 12.2:** Systemic classification of phylum nematoda (Anderson et. al. 1974)

Class	Superfamily	Family	Genus
Adenophorea	Trichinelloidea	Trichinellidae	<i>Trichinella</i>
		Trichuridae	<i>Trichuris</i> , <i>Capillaria</i>
Secernentea	Oxyuroidea	Oxyuridae	<i>Enterobius</i>
	Ascaridoidea	Ascarididae	<i>Ascaris</i> , <i>Toxocara</i> , <i>Baylisascaris</i> , <i>Lagochilascaris</i>
		Anisakidae	<i>Anisakis</i>
	Ancylostomatoidea	Ancylostomatidae	<i>Ancylostoma</i> , <i>Necator</i>
	Rhabditoidea	Strongyloididae	<i>Strongyloides</i>
	Strongyloidea	Chabertiidae	<i>Oesophagostomum</i> , <i>Ternidens</i>
		Syngamidae	<i>Mammomonogamus</i>
	Gnathostomatoidea	Gnathostomatidae	<i>Gnathostoma</i>
	Metastrongyloidea	Angiostrongylidae	<i>Angiostrongylus</i>
	Trichostrongyloidea	Trichostrongylidae	<i>Trichostrongylus</i>
	Filarioidea	Onchocercidae	<i>Wuchereria</i> , <i>Brugia</i> , <i>Loa loa</i> , <i>Onchocerca</i> , <i>Mansonella</i> , <i>Dirofilaria</i>
	Dracunculoidea	Dracunculidae	<i>Dracunculus</i>
	Thelazioidea	Thelaziidae	<i>Thelazia</i>
	Dioctophymatoidea	Dioctophymatidae	<i>Dioctophyme</i>

### Classification Based on Habitat

Most of the nematodes inhabit in the intestine while some (e.g. filarial worms) reside in various tissues (Table 12.3).

### Classification Based on they Lay Egg or Larva

Based on they lay eggs or larvae after fertilization, nematodes can be classified into:

1. Oviparous
2. Viviparous
3. Ovoviviparous.

#### Oviparous

Most of the nematodes are oviparous, i.e following fertilization, the female worms produce eggs that take some time to hatch out to form larvae in the environment.

- Eggs with segmented ovum—Hookworm and *Trichostrongylus* species
- Eggs with unsegmented ovum—*Ascaris* species

- Eggs with unsegmented ovum with mucus plug at both the poles—*Trichuris* species and *Capillaria* species
- Eggs containing larva that takes some time to hatch out—*Enterobius* species.

#### Viviparous

Female worms directly give birth to larvae; there is no egg stage.

Filarial worm, *Trichinella* species, *Dracunculus* species.

#### Ovoviviparous

Female worms lay eggs containing larvae that immediately hatch out. Example *Strongyloides* species.

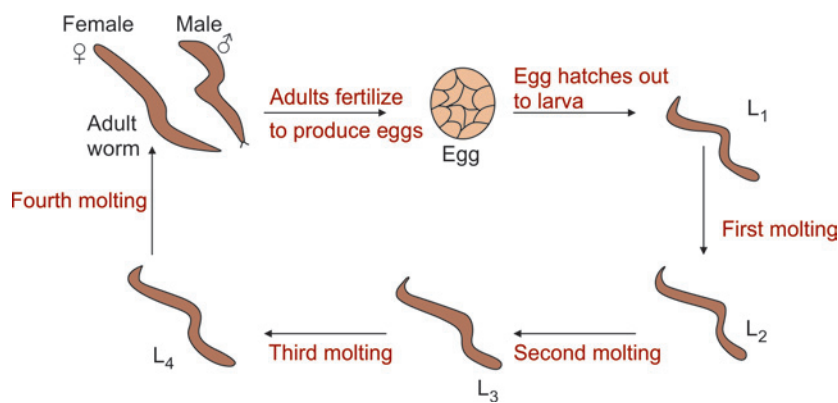
### GENERAL DESCRIPTION

Nematodes pass through six developmental stages (Fig. 12.1) adult worm, egg stage and four larval stages (L<sub>1</sub>–L<sub>4</sub>). Each larval stage transforms to the next by shedding of the cuticle (called as **molting**).

**Table 12.3:** Classification of nematodes based on habitat

Intestinal Human nematodes	Somatic Human nematodes	Animal nematodes infecting rarely to man	
		Larva migrans	Other Animal nematodes
<b>Small Intestine</b>  <i>Ascaris lumbricoides</i> (Common round worm) <i>Ancylostoma duodenale</i> (Old world Hookworm) <i>Necator americanus</i> (American or new world Hookworm)	<b>Filarial worm</b>  <b>Lymphatics</b> <i>Wuchereria bancrofti</i> <i>Brugia malayi</i> <i>Brugia timori</i>  <b>Skin</b> <i>Loa loa</i> (also eye) <i>Onchocerca</i> (also eye) <i>Mansonella streptocerca</i> <i>Mansonella ozzardi</i> (Serous cavity) <i>Mansonella perstans</i>	<b>Visceral Larva migrans</b> <i>Toxocara</i> (Liver) <i>Angiostrongylus cantonensis</i> (CNS) <i>Angiostrongylus costaricensis</i> (abdomen) <i>Anisakis</i> <i>Gnathostoma</i> <i>Baylisascaris</i>  <b>Cutaneous larva migrans</b> <i>Ancylostoma braziliensis</i> <i>Ancylostoma caninum</i> <i>Ancylostoma ceylanicum</i> <i>Gnathostoma</i> spp. <i>Uncinaria stenocephala</i> <i>Bunostomum</i> spp.	<b>Zoonotic filariasis</b> <i>Dirofilaria</i>  <b>Intestine</b> <i>Capillaria philippinensis</i> <i>Trichostrongylus</i> spp. <i>Strongyloides fuelleborni</i> <i>Oesophagostomum</i> <i>Ternidens</i> spp.  <b>Conjunctiva</b> <i>Thelazia</i> spp.  <b>Liver</b> <i>Capillaria hepatica</i>  <b>Kidney</b> <i>Diocotophyma</i> spp.  <b>Respiratory tract/lungs</b> <i>Mammomonogammus</i> <i>Capillaria aerophila</i> <i>Ascaris suum</i>
<b>Large intestine</b> <i>Trichuris trichiura</i> (Whip worm) <i>Enterobius vermicularis</i> (Thread or pin worm)	<b>Other Human Somatic nematodes</b> <i>Trichinella spiralis</i> <i>Dracunculus medinensis</i> (Guinea worm)		

Abbreviations: CNS, central nervous system



**Fig. 12.1:** Developmental stages of nematodes

**Adult Worm**

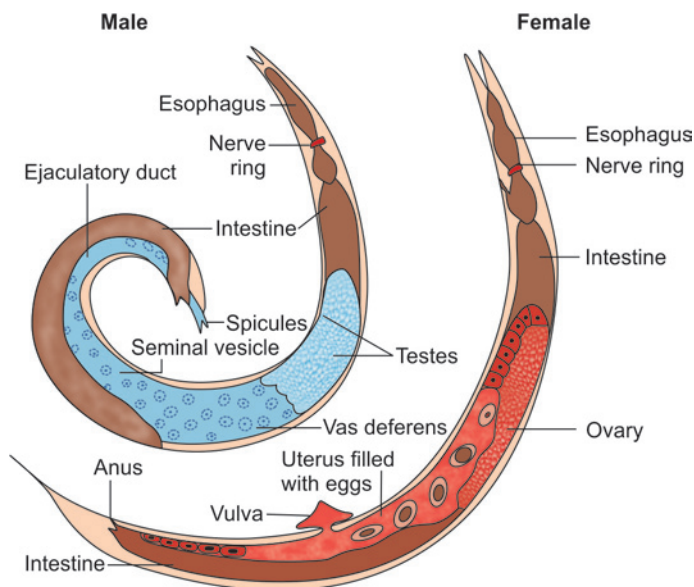
- **Shape:** Nematodes are elongated, cylindrical or filariform in shape with both the ends pointed. They are unsegmented without any appendages
- **Size:** Variable, ranging from less than 5 mm (hookworm, *Trichinella* and *Strongyloides*) to as long as one meter (*Dracunculus*). Female worms are longer than male worms
- **Symmetry:** Body is bilaterally symmetrical (one plane) while head is radially symmetrical (multiple plane)
- **Body wall:** Made up of outer layer of

tough acellular cuticle and inner layer of longitudinal muscle

- **Locomotion:** Nematodes move by contraction of the longitudinal muscles
- **Alimentary canal:** It is well developed and consists of mouth at the anterior end followed by a muscular and glandular esophagus, intestine and rectum that leads to sub-terminal anus at the posterior end. In some species (e.g. hookworm) mouth bears the teeth (cutting plate). The esophagus (or pharynx) may bear posterior bulb (as in *Enterobius*). The intestine or midgut is lined by a single layer of columnar cells
- **Body cavity:** They possess a body cavity or a pseudocoel (space between body wall and alimentary canal) with high hydrostatic pressure which is filled with body fluid secreted by intestine and genital organs
- **Sexes:** Nematodes are diecious (bisexual), i.e. sexes are different
- **Male reproductive system:** It consists of a long convoluted tube which can be differentiated into testes, vas deferens, seminal vesicle and ejaculatory duct. Some worms

also bear accessory copulatory organs like a copulatory bursa with two spicules (rod like protrusible organ present at the posterior end) and gubernaculum (an elevation of cloaca that guides the spicule during copulation). The ejaculatory duct opens subterminally at the posterior end into a common passage along with the rectum (known as cloaca) (Fig.12.2)

- **Female reproductive system:** It consists of two (common) or one convoluted tube. Each tube is differentiated into an ovary, oviduct, seminal receptacle, and uterus and then both the tubes joined to form a common vagina that opens outside through vulva (genital pore) either in the middle of the body or near the mouth (Fig. 12.2)
- **Nervous system:** It is rudimentary and consists of circular nerve ring (brain) surrounding the esophagus and six longitudinal nerve trunks (one dorsal, one ventral and four lateral). The dorsal nerve is responsible for motor control, while the lateral nerves are for sensory and the ventral one combines both the functions. Some species possess



**Fig. 12.2:** Adult male and female nematode (schematic diagram)



sensory structure like sensory papilla and phasmid (chemoreception organs) over the cuticle

- **Excretory system:** It is also rudimentary. Unlike cestodes, they don't have flame cells. Various ways of waste disposal are:
  - Through anus
  - Excretion of nitrogenous waste in the form of ammonia through the body wall
  - In some species, H shaped canal along each side of body regulates nutrients and waste content
  - In few other species; An excretory gland is situated near esophagus.

### Life Cycle

Nematodes complete their life cycle in one host (man) except in filarial worms (need two hosts—definitive host-man and intermediate host—mosquito) and *Dracunculus* species (need two hosts—definitive host man and intermediate host cyclops).

Life cycle, pathogenesis, diagnosis and treatment are discussed in detail under individual nematodes.

## LARGE INTESTINAL NEMATODES

### ■ TRICHURIS TRICHIURA

It is also called as **whipworm** as the adult worm resembles to a handle of a whip.

- It was first described by Linnaeus in 1771
- 71 species of *Trichuris* are recorded so far. However, human infection is mostly confined to *T. trichiura* and very rarely *T. suis* (pig whipworm) and *T. vulpis* (dog whipworm).

### Habitat

It resides in the large intestine of man (mainly cecum and appendix).

### Epidemiology

Trichuriasis is worldwide in distribution,

mainly in warm and moist climate.

- Children are commonly affected
- Global prevalence in humans is approximately 604 millions.

### Morphology

#### Adult Worm

It is whip shaped. Anterior three-fifth is thin, hair like, coiled (like rope of a whip) and posterior two-fifth is short and thick.

- The coiled anterior part contains the esophagus and is attached to the gastrointestinal tract (GIT) mucosa where as the posterior thick part bears the genital organs and intestine and lie free in the human intestine
- The esophagus is glandular, surrounded by a gland called as **stichosome**
- Male is whitish, 30–45 mm long and bears a coiled posterior end
- Female is longer (35–50 mm) and its posterior part is either shaped like a comma or arc (resembles a handle of a whip) (Figs 12.3 and 12.4).

### Egg

Eggs are barrel shaped surrounded by a shell, bear mucus plug at both the poles.

- Elongated, measures 50–54  $\mu\text{m}$  long and 22–23  $\mu\text{m}$  wide
- Unembryonated when firstly passed.
- Bile stained; yellowish brown in colour (in saline mount)
- Floats in saturated salt solution.

**Note:** Eggs of *T. vulpis* is similar to that of *T. trichiura* but it is larger (70–80  $\mu\text{m}$   $\times$  30–42  $\mu\text{m}$ ) with smaller mucus plug.

### Life Cycle (Fig. 12.3)

**Host:** Humans are the only host.

**Infective form:** Embryonated eggs.

**Mode of transmission:** Men (usually children) acquire infection by ingestion of contaminated food and water containing embryonated egg.

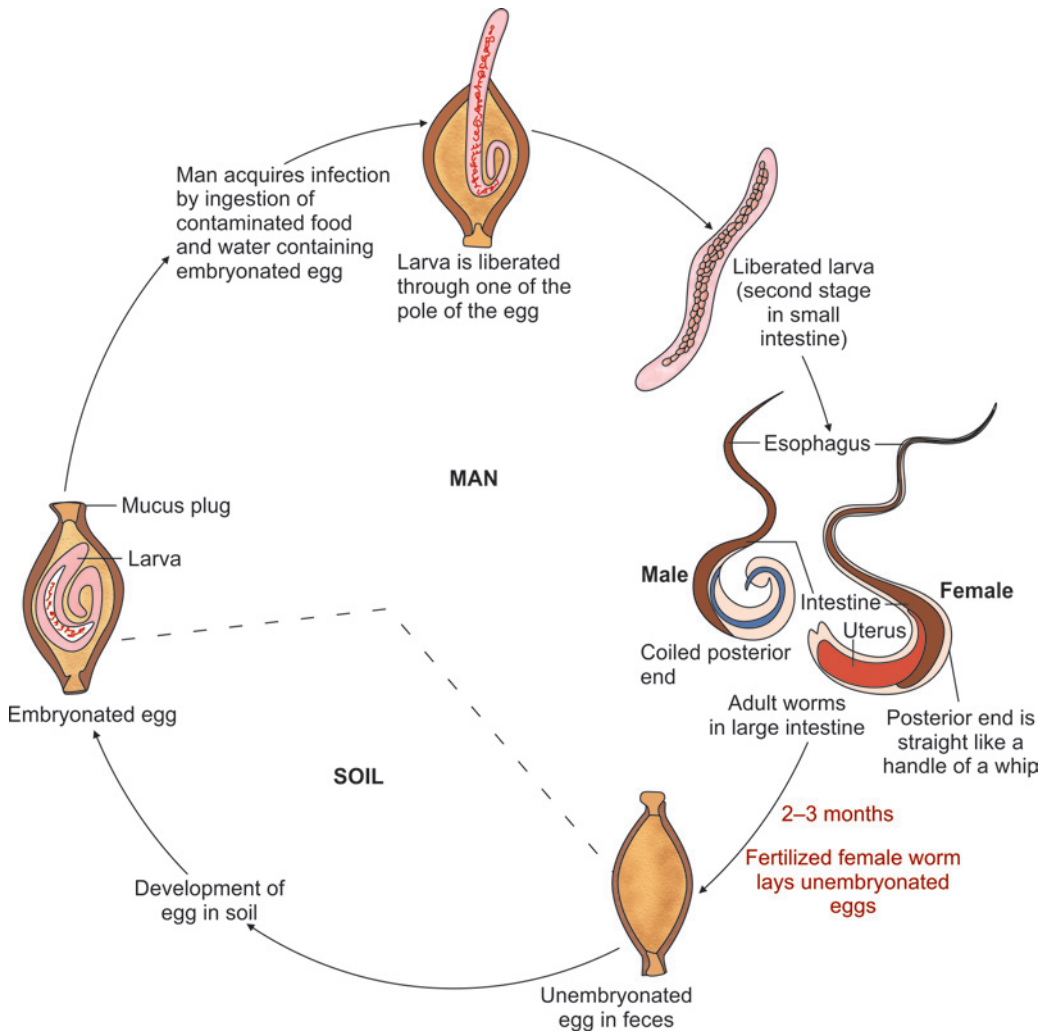


Fig. 12.3: Life cycle of *Trichuris trichiura*

### Egg-Larva-Adult Transformation

Eggs hatch out in the intestine releasing the second stage larva, migrate to large intestine where they undergo further moltings to transform into adult worms.

### Adults Laying Unembryonated Egg

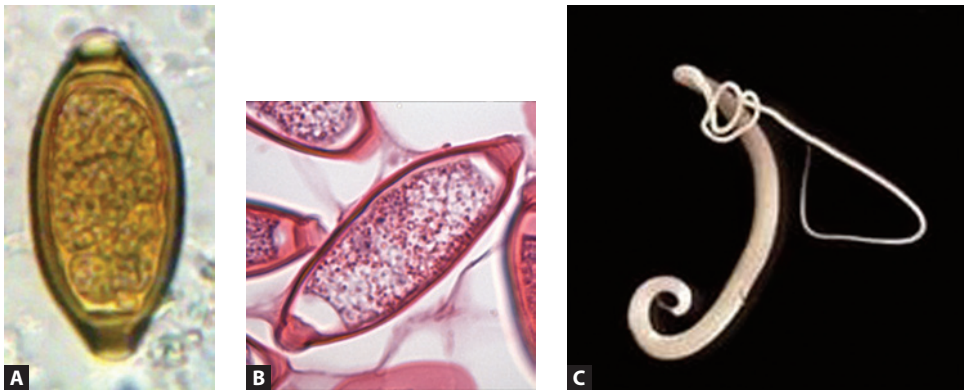
Within 2–3 months, the female worms following fertilization start laying unembryonated eggs. Each female worm can lay 14,000–20,000 eggs per day for 1–3 years.

### Embryonation

The unembryonated eggs passed in the feces are not infective. It takes about 28 days to become embryonated (it undergoes two molts to produce second stage larva within the egg shell). Embryonation occurs at 25°C in warm and moist condition. Such embryonated eggs are infective to man.

### Pathogenicity and Clinical Feature

Most infected individuals have no symptoms



**Figs 12.4A to C:** *Trichuris trichiura* (A) egg in iodine mount; (B) egg (hematoxylin and eosin stain); (C) adult female

Source: (A) Dr Anand, Janagond, Associate professor, Velammal Medical College, Madurai, Tamilnadu; (B and C) DPDx Image Library, Centre for Disease Control and prevention (CDC), Atlanta (with permission)

or only have eosinophilia.

Incubation period varies from 70 days to 90 days.

**In people with heavy infections:** Adult female worm gets buried in the large intestinal mucosa that leads to:

- **Mechanical distortion:** Leading to inflamed, edematous, and friable mucosa
- **Allergic response by the host:** Increased numbers of macrophages infiltrates in the lamina propria that produce tumor necrosis factor- $\alpha$  (TNF- $\alpha$ )

Common manifestations include:

- Abdominal pain, anorexia, etc
- *Trichuris* dysentery syndrome-bloody or mucoid diarrhea resembling inflammatory bowel disease
- Iron deficiency anemia due to blood loss
- Recurrent rectal prolapse (due to heavy worm load in the rectum and malnutrition)
- Growth retardation and impaired cognitive function (due to the release of anti-inflammatory cytokines induced by the secretory molecules of *Trichuris* species).

#### Laboratory Diagnosis

#### *Trichuris trichiura*

- Stool examination—detects barrel shaped eggs with mucus plugs at the ends
- Other findings
  - Peripheral blood Eosinophilia (< 15%)
  - Increased serum IgE level

### Laboratory Diagnosis

#### Stool Examination

Because the level of egg output is high (approximately 200 eggs/g of feces per worm pair), microscopic examination of a single fecal smear is sufficient for diagnosis of symptomatic cases (Fig. 12.4).

- The characteristic  $50 \times 22 \mu\text{m}$  barrel-shaped *Trichuris* eggs (with mucus plugs at the ends) are readily detected on stool examination either by direct wet mount or following concentration of the stool (Fig. 12.4A)
- Preservative: Formalin is preferred over polyvinyl alcohol to preserve the stool samples
- Whip shaped adult worms of 3–5 cm long, are occasionally seen on proctoscopy (12.4 C).

#### Other Findings

- Peripheral blood eosinophilia (< 15%)
- Increased serum IgE level.

#### Treatment

#### *Trichuris trichiura*

- Mebendazole (500 mg once) or albendazole (400 mg daily for three doses) is safe and moderately effective for treatment, with cure rates of 70–90%
- Ivermectin (200 mg/kg daily for three doses) is also safe but is less effective.

## ENTEROBIUS VERMICULARIS

*Enterobius vermicularis* is also called as **pin worm** or **threadworm**.

- It is described first by Leuckart, in 1865
- *E. vermicularis* is the only species. The second species *E. gregorii* is identical to *E. vermicularis* (except the basal portion of spicule) and now it is considered as the younger stage of *E. vermicularis*.

### Habitat

The adult worm remains attached to the large intestine (cecum, appendix and adjacent portion of colon) by their mouth end.

### Epidemiology

**Global prevalence in humans:** Globally, around 209 million people are infected by pinworms

- The prevalence is maximum in school children between the age of 5 and 14 years.
- People carry the infection for years together due to auto infective cycles
- **It has been said that:** “*You had the infection as a child, you have it now and you will again get it when you have children*”
- **Factors promoting infection:** Over crowding and impaired hygiene, poor personal care (nail biting or inadequate hand washing).

### Morphology

#### Adult Worm

It is small, white and thread like (hence named as threadworm).

- **Cervical alae:** The adult worm bears a wing like expansion of the cuticle near the anterior end
- **Double bulb esophagus:** The posterior end of the esophagus is dilated to form globular bulb
- Male worm is smaller (2–5mm long × 0.1–0.2 mm wide) and the posterior one-third is tightly curved and bears a copulatory bursa with spicules at the posterior end. Males die soon after fertilization

- Female worm is longer (8–13 mm long × 0.3–0.5 mm wide), and the posterior one-third is tapering, straight, thin and pointed (looks like a pin, hence called as pin worm).

### Eggs

- **Shape:** Oval or planoconvex (one side is plain and the other side is flat because it is compressed laterally)
- **Size:** 50–60  $\mu\text{m}$  long × 20–30  $\mu\text{m}$  wide (Fig. 12.5)
- **Surrounded by:** Double layered egg shell
- Not bile stained, Colorless in saline mount
- Embryonated when passed fresh; contains a tadpole larva inside
- Floats in saturated salt solution.

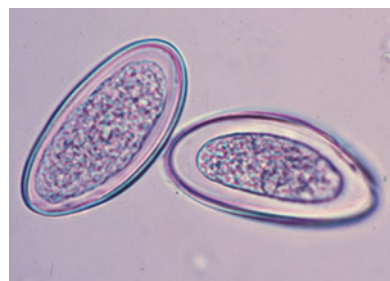
### Life Cycle (Fig. 12.6)

**Host:** Humans are the only host.

**Infective form:** Embryonated eggs are infective to man.

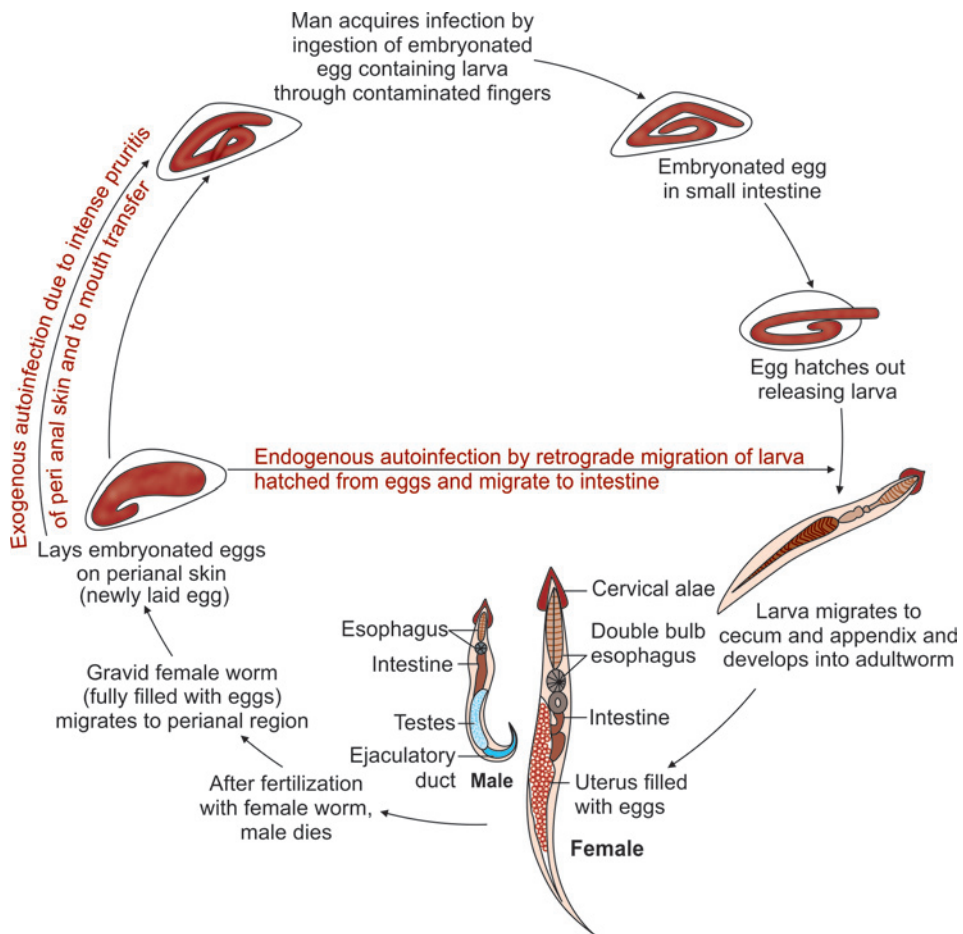
**Mode of transmission:** Men (usually children) acquire infection by ingestion of embryonated eggs containing larva by:

- Ingestion of eggs contaminated with fingers due to inadequate hand washing or nail biting habit
- **Autoinfection:** Endogenous autoinfection by retrograde migration of the larva hatched from the eggs in the perianal skin



**Fig. 12.5:** Egg of *Enterobius vermicularis* (saline mount)

Source: DPDx Image Library, Centre for Disease Control and prevention (CDC), Atlanta (with permission)



**Fig. 12.6** Life cycle of *Enterobius vermicularis*

Exogenous autoinfection—eggs cause intense irritation of the perianal skin and scrapping of the area leads to contaminated finger.

Rarely, inhalation of the airborne eggs

### Development in Man

Eggs usually contain the fully developed larvae. Eggs hatch out releasing the larvae in the cecum and develop into adult worms.

- Adult female mature within 1 month. After fertilization with female worms, the male worms usually die. Gravid female worms fully filled with eggs migrate to large

intestine (rectum, colon) and start laying eggs on the perianal skin. Adult female worms usually lay 2,000 eggs/day

- The eggs are embryonated and are the infective stage to man
- Female worm live for about 2 months but because of the autoinfection the cycle continues.

### Pathogenicity and Clinical Features

- **Asymptomatic:** Most of the infections are asymptomatic
- **Symptomatic patients:**
  - **Age and sex:** Females, children and



young adults are often symptomatic than males and older people

- **Cardinal symptoms:** Perianal pruritus often worse at night as a result of the nocturnal migration of the female worm
- Excoriation of the perianal skin and bacterial super-infection may occur (due to continuous scratching of the skin)
- Abdominal pain and weight loss (may be seen in heavy infections)
- **Migration of the worm:** Rarely, pinworms invade the female genital tract, causing vulvovaginitis and pelvic or peritoneal granulomas. Other sites involved are urinary tract, peritoneal cavity, lungs and liver
- Eosinophilia is uncommon.

#### Laboratory Diagnosis

*Enterobius vermicularis*

- Microscopy—wet mount of perianal swab collected by cellophane tape method or NIH swab method detects planoconvex eggs containing larvae

#### Laboratory Diagnosis

The female worms lay eggs in the perianal area; not in rectum. Hence eggs are rarely detected by stool examination.

So the eggs deposited in the perianal skin are collected by applying cellophane tape or its modification called, NIH swab.

#### Cellophane Tape Method

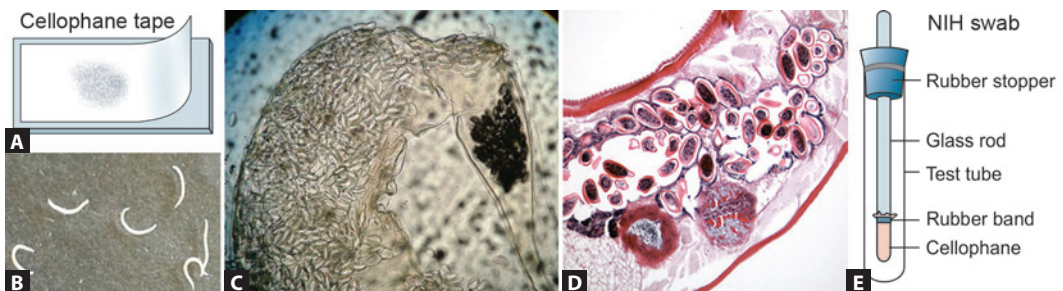
Eggs are detected by the application of clear cellulose acetate tape to the perianal region in the morning before the child goes for bath. The tape is then applied on the clear glass slide. The slide is observed under microscope for the detection of pin worm eggs (Figs 12.5 and 12.7).

#### NIH Swab Method

It is devised in National institute of health, USA.

- It consists of a glass rod attached to a cellophane tape by a rubber band
- The other end of the glass rod is fixed by a rubber stopper and kept in a test tube
- The cellophane part of the glass rod is rolled over the perineal and perianal skin area to collect the sample
- After the tape is transferred to a slide, microscopic examination will detect *Enterobius* eggs, which are planoconvex, flattened along one side, measure  $50\text{--}60\ \mu\text{m} \times 20\text{--}30\ \mu\text{m}$ , containing a larva inside (Figs 12.5 and 12.7).

The adult female worms may occasionally be found in the feces or crawling to the perianal skin (Fig. 12.7B).



**Figs 12.7A to D:** *Enterobius vermicularis* (A) cellophane tape; (B) adult worm (actual size);

(C) adult female worm containing numerous eggs; (D) longitudinal section of an adult female worm shows many planoconvex eggs; (E) NIH swab method

Source: (B and C) HOD, Dept. of Microbiology, Meenakshi Medical College, Chennai (D) DPDx Image Library, Centre for Disease Control and prevention (CDC), Atlanta (with permission)



Treatment	Enterobius vermicularis
<ul style="list-style-type: none"><li>• One of the following drugs can be given:<ul style="list-style-type: none"><li>➢ Mebendazole (100 mg once)</li><li>➢ Albendazole (400 mg once) or</li><li>➢ Pyrantel pamoate (11 mg/kg once; maximum, 1 g).</li></ul></li><li>• The same treatment should be repeated after 2 weeks</li><li>• Treatment of household members is advocated to eliminate asymptomatic reservoirs of potential reinfection.</li></ul>	

**Prevention**

By improving personal hygiene such as proper washing of bed clothes and hand washing.

**SMALL INTESTINAL NEMATODES**

**■ HOOKWORM**

Hookworm is one of the important causes of iron deficiency anemia in both tropics and temperate countries. It is so named because the anterior end of adult worm is bent.

**Classification**

Hookworm belongs to the family Ancylostomatidae which consists of two species infecting humans. *Ancylostoma duodenale* and *Necator americanus*. The word *Ancylostoma* is derived from hooked mouth (*Ancylos*—hooked, *stoma*—mouth)

- Human parasite:
  - *A. duodenale* or old world hook worm
  - *N. americanus* or new world (or American) hook worm
- Animal parasites that rarely infect man causes cutaneous larva migrans
  - *Ancylostoma braziliensis*
  - *Ancylostoma caninum*
  - *Ancylostoma ceylanicum*
  - *Uncinaria stenocephala*.

**History**

- *A. duodenale* was first detected by an Italian physician Dubini in 1843 and life cycle and

pathogenesis was described by Arthur Loss in 1898

- *N. americanus* was first described by Stites in 1902 in Texas, USA, hence called as **American hookworm**.

**Epidemiology**

**World**

Hookworm infection is wide spread. Globally, nearly 900 million people are infected. *N. americanus* infection (835 million) is more common than *A. duodenale* (135 million).

- *A. duodenale* is prevalent in southern Europe, North Africa, and northern Asia
- *N. americanus* is the predominant species in the Western world, found throughout Central and South Africa, Central and South America
- In South East Asia including India, both the species coexist
- Hookworm infection is almost eradicated from Europe and USA
- Males and young adults (15–25 years) are commonly affected. But the anemia due to the iron loss is more severe in children and pregnant women.

**India**

Hookworm infection is widely prevalent in India. More than 200 million people are estimated to be infected in India.

- *N. americanus* is predominant in south India and *A. duodenale* in north India
- *Necator* is seen in all the states except the Punjab and Uttar Pradesh
- Recently, another species, *A. ceylanicum* has been reported from a village near Calcutta
- The heavily infected areas are: Assam (tea gardens), West Bengal, Bihar, Odisha, Andhra Pradesh, Tamil Nadu, Kerala and Maharashtra.

**Endemic Index**

**Chandler's index** is used in the epidemiological studies of hookworm disease to

estimate the morbidity and mortality in the community from hookworm infection (which depends much upon the worm load).

## Morphology

### Adult Worm (*A. duodenale*)

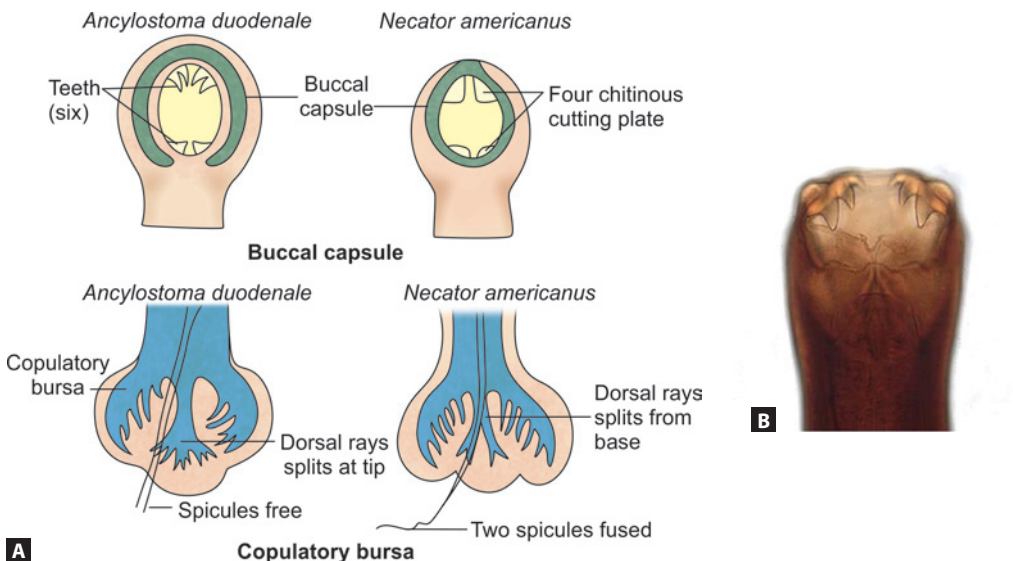
- **Size:** Male worm is smaller (5–11 mm) than the female (9–13 mm)
- **Shape:** Straight except the anterior end which is bent dorsally (in the same direction of body curvature), hence called as **hookworm**
- **Color:** Adult worm is pink or grayish white but may look reddish due to ingested blood
- **Mouth:** It is present at the anterior end, directed dorsally. It contains the buccal capsule which is lined by a hard substance bearing six teeth (four hook like teeth on ventral surface and two knob like teeth dorsally) (Fig. 12.8)
- **Glands:** The digestive system is attached with five glands, one of them is the esophageal gland secreting a substance that prevents clotting

- Presence of copulatory bursa in the caudal end of males differentiates it from the female worms of *A. duodenale* (Table 12.4).
- **Copulatory bursa:** It is the umbrella like expansion of the posterior end of male worm bearing two spicules, consists of three lobes (one-dorsal and two-lateral). All the three lobes again split in a tripartite fashion. Dorsal lobe contains three dorsal rays; each lateral lobe contains five rays (two-ventral and three lateral rays). So total numbers of rays are 13 (Fig. 12.8).
- Other features are similar to any nematode described at the beginning of the chapter
- Adult worm of *N. americanus* is different from *A. duodenale* (Table 12.5).

## Egg

Hookworm eggs are:

- Oval shaped, measures 60  $\mu\text{m}$  long  $\times$  40  $\mu\text{m}$  wide
- Not bile stained, colorless
- Surrounded by thin, hyaline, translucent egg shell



**Figs 12.8A and B:** (A) Buccal capsule and copulatory bursa of *Ancylostoma duodenale* and *Necator americanus*; (B) buccal capsule of *Ancylostoma* spp.

Source: DPDx Image Library, Centre for Disease Control and prevention (CDC), Atlanta (with permission)

**Table 12.4:** Differences between male and female worms of *Ancylostoma duodenale*

Features	Male worm	Female worms
Size	Smaller (5–11 mm)	Longer (9–13 mm)
Copulatory bursa	Present posteriorly	Absent
Posterior end	Expanded due to copulatory bursa	Tapering and straight pointed tail
Genital opening	Opens in cloaca along with anus	Opens separately in the middle

**Table 12.5:** Differences between Adult worm of *Ancylostoma duodenale* and *Necator americanus*

Adult worm	<i>Ancylostoma duodenale</i>	<i>Necator americanus</i>
Size	Large and thick	Smaller and more slender
Bending of anterior end	Bends in the same direction of body curvature	Bends in the opposite direction of body curvature
Buccal capsule	Bears six teeth <ul style="list-style-type: none"><li>• Four hook like ventral teeth</li><li>• Two knob like dorsal</li></ul>	Four chitinous cutting plate present, Two ventral and two dorsal Dorsomedian teeth are present
Copulatory bursa	<ul style="list-style-type: none"><li>• Bifurcation is tripartite</li><li>• Total number of rays 13</li><li>• Dorsal ray splits at the tip</li><li>• Two spicules present freely</li></ul>	<ul style="list-style-type: none"><li>• Bifurcation is bipartite</li><li>• Total number of rays 14</li><li>• Dorsal ray splits from the base</li><li>• Both spicules fused at the tip</li></ul>
Posterior end of female worm	Bears a spine	No spine present in females
Vulva opens at	Behind the middle of the body	In front of middle of the body
Pathogenicity	More pathogenic because of <ul style="list-style-type: none"><li>• Larger size, armed with teeth and more migratory</li><li>• Blood loss 0.15–0.26 mL/worm/day</li></ul>	Less pathogenic <ul style="list-style-type: none"><li>• <b>Except:</b> Ground itch and dermatitis (more severe)</li><li>• Blood loss 0.03 mL /worm/day</li></ul>

- Ovum (embryo) is segmented (four blastomeres) (Fig. 12.9)
- There is a clear space between the egg shell and the embryo
- Floats on saturated salt solution
- Eggs of both *A. duodenale* and *N. americanus* are morphologically indistinguishable.
- Filariform larva is longer (660–720  $\mu\text{m}$ ) than the rhabditiform larva (100–150  $\mu\text{m}$ ), the esophageal bulb extends to about one third of the body length and the posterior end is more acutely tapered (Fig. 12.10)
- The rhabditiform larva of *A. duodenale* and *N. americanus* is morphologically similar but it differs in the morphology of their filariform larva (Table 12.6).

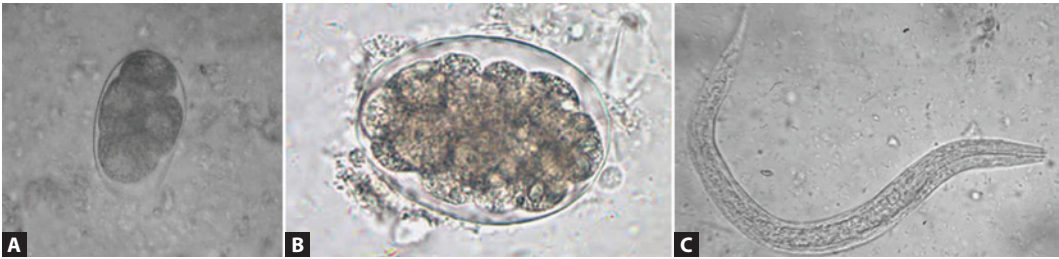
**Larva**

There are four stages of hookworm larva ( $L_1$  to  $L_4$ )

- First stage larva is called as rhabditiform larva
- $L_3$  stage larva is called as filariform larva and is the infective form to man

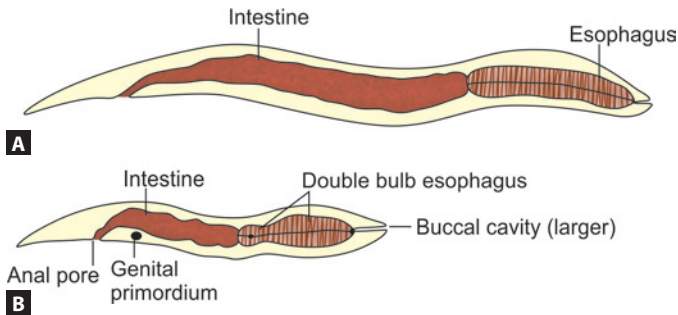
**Life Cycle (Fig. 12.11)**

**Host:** Involves only one host (man).  
**Infective stage:** Third stage filariform ( $L_3$ ) larva.  
**Mode of transmission:** Through penetration of skin by the third stage larva (by walking



**Figs 12.9A to C:** Hookworm (A) egg with four blastomeres; (B) egg with many blastomeres; (C) rhabditiform larva

Source: (B and C) DPDx Image Library, Centre for Disease Control and prevention (CDC), Atlanta (with permission)



**Figs 12.10A and B:** Hookworm (*Acylostoma duodenale*) (A) filariform larva; (B) rhabditiform larva

**Table 12.6:** Differences between filariform ( $L_3$ ) larva of *Ancylostoma duodenale* and *Necator americanus*

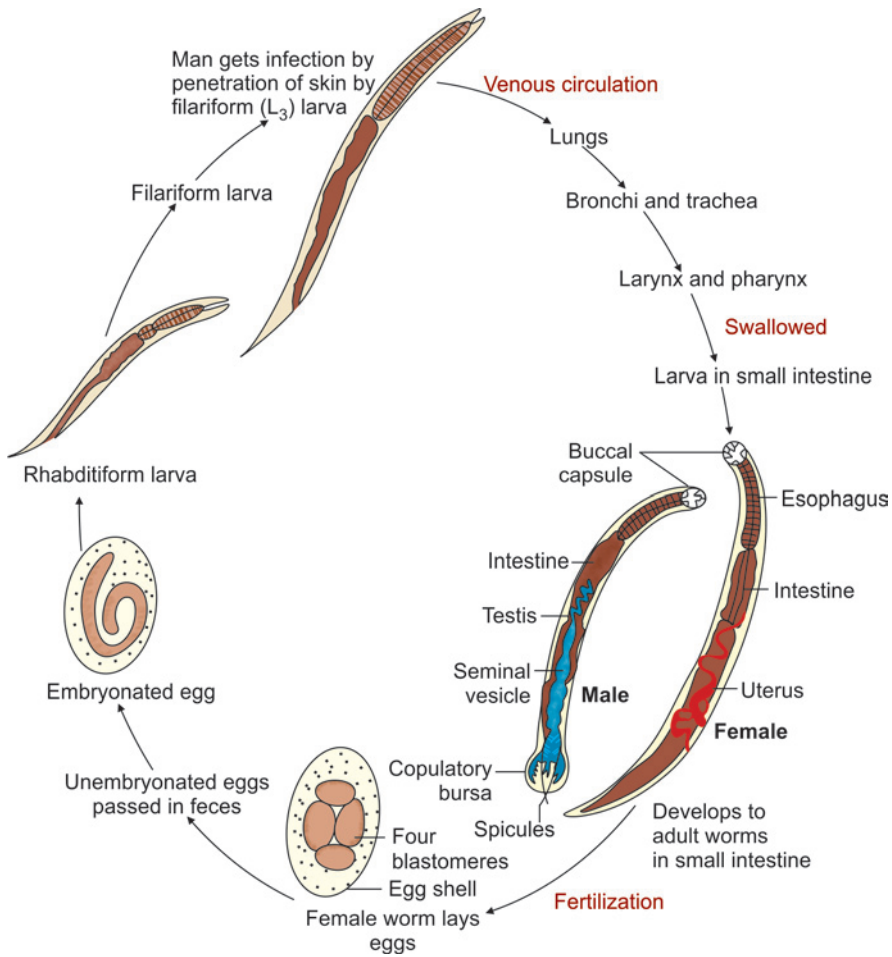
Filariform ( $L_3$ ) larva	<i>Ancylostoma duodenale</i>	<i>Necator americanus</i>
Size	720 $\mu\text{m}$	660 $\mu\text{m}$
Shape	Head blunt and tail pointed	Same
Cuticle	Bears faint transverse striations	Bears prominent transverse striations
Buccal capsule	Shorter (10 $\mu\text{m}$ ), lumen larger and bounded by two thin chitinous wall	Larger (15 $\mu\text{m}$ ), lumen short and bounded by two thick chitinous wall
Esopho-intestinal junction	No gap between esophagus and intestine	Gap between esophagus and intestine due to prominent anterior dilatation of intestinal lumen
Intestine	Posterior end of intestine has a refractile body	Refractile body absent

bare foot in dampen soil). Though rare, but other routes of transmission of the larva has been reported through oral, in utero and transmammmary routes.

**Migratory Phase**

Following penetration, the  $L_3$  larvae enter into

the small subcutaneous venules and through venous circulation, reach to the right side of heart and finally to the lungs. Here, they enter into the alveolar space and migrate up to bronchi, trachea and finally by swallowing of sputum, they enter GIT.



**Fig. 12.11:** Life cycle of hookworm

### Intestinal Phase

#### Develop into adults

The L<sub>3</sub> larvae undergo third molt (either in the migratory phase or on reaching esophagus) to form L<sub>4</sub> larvae that reach the small intestine where they undergo the final molt to develop into adult worms.

#### Laying eggs

The adult worms attach to the intestinal mucosa by their teeth in buccal capsule. In about 5 months following infection, the adult worms mature and then following ferti-

zation, the female worms start laying the eggs, which are excreted in the feces.

A gravid female of *A. duodenale* can lay 10,000–25,000 eggs/day where as that of *N. americanus* can lay 5000–10,000 eggs/day. The female worm survives for about 1 year (*A. duodenale*) and 3–5 years (*N. americanus*).

#### Development in Soil

Embryonation takes place in moist, sandy and warm soil. The first stage (rhabditiform) larvae hatch out from eggs which then molt twice and finally the infective stage, i.e. L<sub>3</sub>

larvae are developed within 5–8 days and they remain viable in soil for several weeks.

### Pathogenicity

Hookworm has ability to suck blood from the intestinal vessels by:

- Attaching and making cuts in the intestinal wall by buccal capsule and teeth followed by sucking the blood through contraction of their muscular esophagus
- Secreting hydrolytic enzymes
- Releasing anticoagulants like factor VIIa/tissue factor inhibitor
- Ingestion of extravasated blood

It can also penetrate the skin which is facilitated by proteolytic enzymes (like aspartyl proteases) and hyaluronidase secreted by hookworm

It is postulated that, hookworm infection can protect the individual from asthma and malaria but predispose to human immunodeficiency virus (HIV), tuberculosis and other intestinal helminthic infections.

### Clinical Features

#### Affect Due to Migrating Larva

##### Local lesion (in previously sensitized persons)

- Infective larvae may provoke pruritic maculopapular dermatitis and rashes (“ground itch”) at the site of skin penetration and
- **Serpiginous tracks** may be formed due to subcutaneous migration of the larva similar to those of cutaneous larva migrans (described later).

##### Mild transient pneumonitis

Migrating larva through the lungs occasionally cause mild transient pneumonitis, but the severity and frequency of lung manifestation is less compared to ascariasis.

#### Affect due to Adultworm in Intestine

**Asymptomatic:** Most hookworm infections are asymptomatic.

**Early intestinal phase (less worm load):** Infected persons may develop epigastric pain (often with postprandial accentuation), inflammatory diarrhea, or other abdominal symptoms accompanied by eosinophilia.

**Late intestinal phase (chronic hookworm infection with heavy worm load):** Patients develop iron deficiency anemia and protein energy malnutrition resulting from blood loss.

Other features are weakness and shortness of breath and rarely impaired intellectual power and behavioral changes.

**Wakana disease:** When  $L_3$  larva of *A. duodenale* is ingested by the oral route, both gastrointestinal (due to larva develop in to adult worm in intestine) as well as pulmonary symptoms (due to larva migrating through pharynx) are observed. Common symptoms include nausea, vomiting, pharyngeal irritation, cough, dyspnea, and hoarseness. This is not seen with *N. americanus* as their  $L_3$  stage fails to develop after ingestion.

#### Laboratory Diagnosis

*Acylostoma duodenale*

- Stool microscopy—detects non bile stained oval segmented eggs
- Stool culture
  - Harada Mori filter paper tube method
  - Petridish (slant culture) technique
  - Baermann funnel technique
  - Charcoal culture method
  - Agar Plate technique (more sensitive)
- Other findings
  - Hypochromic microcytic anemia
  - Eosinophilia
  - Hypoalbuminemia

### Laboratory Diagnosis

#### Stool Microscopy

The diagnosis is established by finding of characteristic oval segmented hookworm eggs in the feces (Fig. 12.9A)

- Stool concentration procedures may be required to detect lighter infections
- Eggs of *A. duodenale* and *N. americanus* are indistinguishable



- In a stool sample that is not fresh, the eggs may hatch out to release rhabditiform larvae, which need to be differentiated from those of *Strongyloides* (Table 12.7) (Fig. 12.9C)
- **Egg counting:** Number of eggs per gram of stool can be counted to estimate the disease burden in the individual as well as in the community. Various methods (described in detail in chapter 15) are:
  - Kato Katz technique
  - Direct smear method of Beaver
  - Modified Stoll's Dilution egg count method.

**Stool Culture**

Since the eggs of *A. duodenale* and *N. americanus* are indistinguishable, so freshly passed stool samples can be cultured where the eggs hatch out to develop to L<sub>3</sub> stage filariform larva in 5–7 days.

- The filariform L<sub>3</sub> larva of *A. duodenale* is different from *N. americanus* (Table 12.6)
- The rhabditiform and filariform larva of hookworm and *Strongyloides* should also be differentiated (Table 12.7 and Figs 12.10 and 12.12)
- Various culture techniques used are (described in detail in chapter 15):
  - Harada Mori filter paper tube method
  - Petridish (slant culture) technique
  - Baermann funnel technique
  - Charcoal culture method
  - Agar Plate technique (more sensitive).

**Other Findings**

- Hypochromic microcytic anemia

- Eosinophilia
- Hypoalbuminemia.

Treatment	<i>Acyllostoma duodenale</i>
<b>Antiparasitic</b>	
<ul style="list-style-type: none"><li>• Antiparasitic drugs like albendazole (400 mg once), mebendazole (500 mg once), and pyrantel pamoate (11 mg/kg for 3 days) can be given</li><li>• However, due to the widespread use of the drugs, their efficacy is decreased compared to past. Resistance to albendazole and mebendazole has also been reported</li></ul>	
<b>Symptomatic Treatment</b>	
<ul style="list-style-type: none"><li>• Mild iron-deficiency anemia can often be treated with oral iron alone.</li><li>• Severe hookworm disease with protein loss and malabsorption warrants nutritional support and oral or parenteral iron replacement</li></ul>	

**Prevention**

**Personal care**

- Improved personal hygiene
- Proper disposal of feces
- Improved nutrition with dietary iron
- Treatment of infected persons
- **School based deworming:** It was launched by World Health Organization (WHO) in 2001 which aimed at reducing the hookworm morbidity by giving anthelmintic drugs to at least 75% of school going children by 2010.

**Vaccine approaches**

- Experimental immunization of animals with vaccines using larval or adult stage antigen was found to be effective.

**Table 12.7:** Differences between rhabditiform larva of hookworm and *Strongyloides stercoralis*

<i>Rhabditiform larva</i>	<i>Hookworm</i>	<i>Strongyloides</i>
Size	100–150 µm long × 16 µm width	250 µm long × 16 µm width
Mouth (buccal cavity)	Three times longer	Shorter
Genital primordium	Less prominent and small	Prominent and large
Anal pore (sub-terminal)	80 µm from the posterior end	50 µm from the posterior end

- Various human trials are going on targeting molecules like *Acylstoma* secreted protein (ASP).

## ■ STRONGYLOIDES STERCORALIS

### History

- *Strongyloides stercoralis* was known as the “**military worm**” as it was first found by Lois Normand in 1876 in the feces of French soldiers in Cochinchina.
- The life cycle and pathogenicity were described later during early 1900s.
- The name was coined by Stites and Hassall in 1902.

### Classification

*Strongyloides* belongs to superfamily Rhabditoidea and family Strongylidae.

It comprises of 53 species but human infection is mainly caused by *S. stercoralis* and rarely by *S. fuelleborni*.

### Epidemiology

*S. stercoralis* is distributed in hot, humid tropical areas.

- It is particularly common in South East Asia (including India), Sub-Saharan Africa, and South America (Brazil).
- In the Western World, the parasite is found in immigrants, refugees, travelers, and military personnel who have lived in endemic areas.

### Habitat

The parasitic female worms reside in the human intestine (duodenum and jejunum) whereas the free-living female worms multiply in the environment.

Male worms are always free-living. The existence of parasitic male worm is debatable for many years. Most believe that parasitic male worms do not exist. However some school of thought believes that they may exist

and fertilization may occur but they don't have penetrating power.

### Morphology

#### Adult Worm

Only female worms are seen in the human intestine, male worms are rarely encountered.

- **Size:** The parasitic female worm (in human intestine) measures 2–3 mm long and 30–50  $\mu\text{m}$  broad, whereas the free-living female worm is smaller and thicker (1 mm  $\times$  80  $\mu\text{m}$ ).
- **Alimentary tract:** Anterior portion is thicker bearing the mouth with three small lips, esophagus (with a posterior bulb and three esophageal glands) followed by the intestine with a mid ventral anus.
- Female reproductive organs consist of paired ovaries, oviducts and uteri which joined to form the vagina that leads to vulval opening at the junction of middle and posterior third of the body.
- The free living male worms are slightly smaller, having two spicules at the posterior end.
- Other features are similar to any nematode described at the beginning of the chapter.

### Eggs

Eggs are conspicuous within the gravid female worm and arranged anteroposteriorly in a single row of 5–10 eggs in each uterus.

- They are oval and measure 50–70  $\mu\text{m}$  long.
- Eggs of *Strongyloides* are ovoviviparous, i.e. they immediately hatch out to larvae.

### Larva

There are four stages of *Strongyloides* larva ( $L_1$  to  $L_4$ ).

- **First stage or rhabditiform larva ( $L_1$ ):** Eggs hatch out to form  $L_1$  larvae in the human intestine. They measure 250  $\mu\text{m}$  long  $\times$  16  $\mu\text{m}$  width. They have a short mouth (buccal cavity), a double bulb esophagus and prominent, large genital primordium. It is the diagnostic form found in human feces (Fig. 12.12).

- **Third stage or filariform larva ( $L_3$ ):** In the environment, the  $L_1$  larva molts twice to form filariform larva. It measures  $630\ \mu\text{m}$  long  $\times$   $16\ \mu\text{m}$  width and bears a long cylindrical esophagus and a notched tail. It survives few days in the environment and is the infective stage to human (Fig. 12.12).

### Life Cycle (Fig 12.13)

**Host:** *S. stercoralis* involves only one host (man). Rarely, domestic pets are recognized as reservoir of infection.

**Infective stage:**  $L_3$  larva (filariform).

**Mode of transmission:**

- Penetration of skin by the  $L_3$  larva (by walking bare foot). Larva releases hydrolytic enzymes that helps in penetration.
- Autoinfection (internal autoinfection)
- Though rare, but other routes of transmission of the larva has been reported like in utero, transmammmary routes or zoonotic transmission.

### Migratory Phase

Following penetration, the  $L_3$  larvae enter the subcutaneous small venules through the venous circulation, they reach to the right side of heart and finally to the lungs. Here, they enter into the alveolar space and migrate up to bronchi, trachea and finally by swallowing of sputum, they enter GIT.

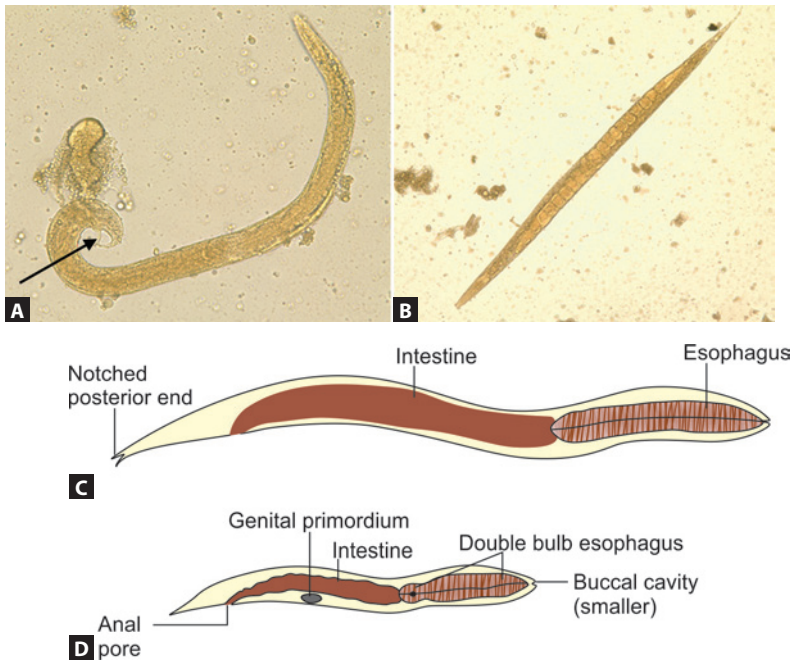
### Intestinal Phase

#### Develop into adults

The  $L_3$  larvae undergo third molt (mostly in the lungs or on reaching esophagus) to form  $L_4$  larvae that reach the small intestine where they undergo the final molt to develop into adult females. However, adult males are not found in human intestine.

#### Laying eggs

Only the female worms are seen buried in the intestinal mucosa. They can directly lay eggs without fertilization (called as



**Figs 12.12A to D:** *Strongyloides stercoralis* (A) adult male (arrow shows spicules); (B) adult female (containing single row of eggs); (C) filariform larva; (D) rhabditiform larva

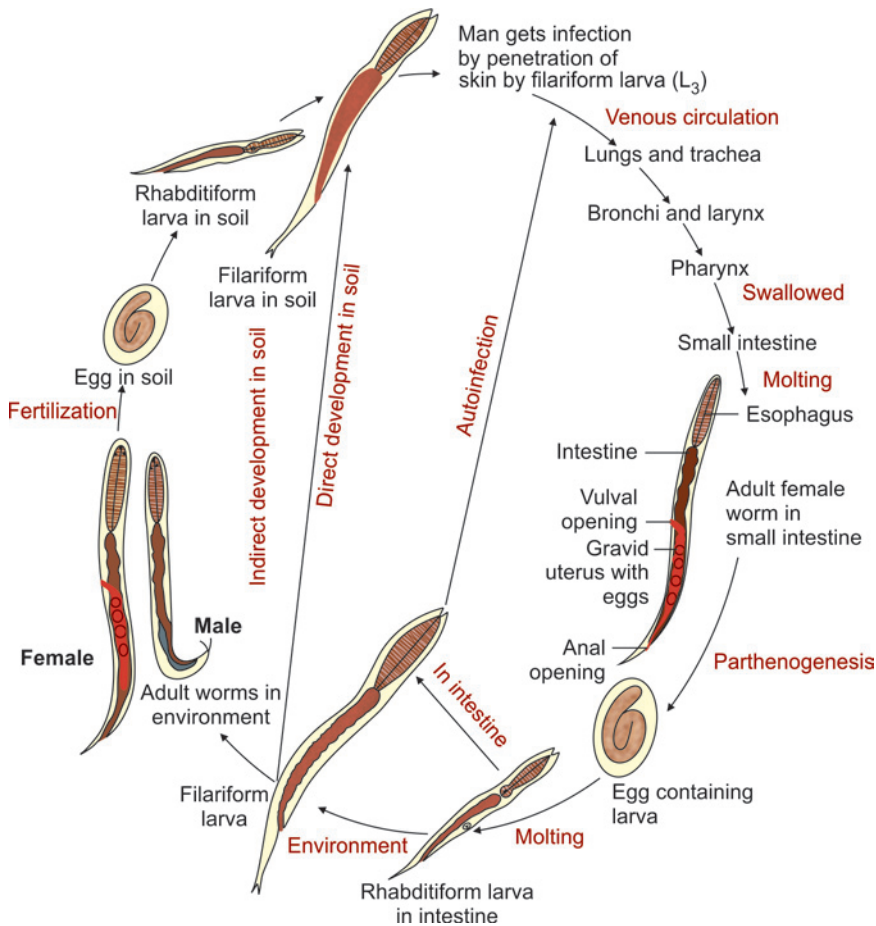


Fig. 12.13: Life cycle of *Strongyloides stercoralis*

**parthenogenesis**—a process by which the females produce offspring without fertilization with males)

- Eggs produced following fertilization with male worms have been postulated by some school of thoughts, but have never been confirmed
- Eggs soon hatch out liberating the rhabditiform (L<sub>1</sub>) larvae into the intestinal lumen and are passed in the feces
- **Autoinfection:** Some times, the L<sub>1</sub> larvae released in the human intestine don't pass in the feces but develop into filariform larvae that eventually penetrate the intestinal wall or perianal skin, enter the venous circulation and reach lungs. Autoinfection is

responsible for maintaining the infection as long as 30–40 years and can cause disseminated infection

### Development in Environment

In moist and warm soil, the rhabditiform (L<sub>1</sub>) larva molts twice to form the L<sub>3</sub> larva. Then, two type of development takes place: (direct and indirect), depending on the environmental conditions sensed by the chemosensory neurons present in the anterior end of the larva.

### Direct development

The L<sub>3</sub> larva acts as the infective form and infects man through the penetration of skin.

**Indirect development**

The L<sub>3</sub> larvae molt twice to develop into the adult worms (male and female) in the environment. The free-living adult worms become sexually matured; fertilization takes place to lay eggs that hatch out soon to L<sub>1</sub> larvae which molts twice to form the infective L<sub>3</sub> filariform larvae.

**Pathogenesis and Clinical Feature**

**Affect Due to Migrating Larva**

- **Asymptomatic infection:** More than 50% of chronically infected people may be asymptomatic
- **Rashes:** Some people develop recurrent maculopapular or urticarial rashes that involve primarily the buttocks, perineum, and thighs
- **Cutaneous larva migrans:** Migrating larvae may produce the pathognomonic serpiginous urticarial rash called as **larva currens** that advances as fast as 10 cm/hour
- **Pulmonary symptoms** are uncommon compared to ascariasis and hookworm. It occurs only secondary to underlying

chronic obstructive lung disease.

**Affect Due to Worm and Filariform Larva**

- **Mild to moderate worm load:** Adult worms and larvae traversing the upper small bowel mucosa may produce epigastric pain (resembling peptic ulcer), nausea, diarrhea, and blood loss
- **Heavy larva load:** Hyperinfection syndrome and disseminated strongyloidiasis are the important complications (Table 12.8).

**Laboratory Diagnosis**

- Microscopy [stool or duodenal aspirate (by Entero-test), rarely sputum]—detects rhabditiform larvae
- Stool culture
  - Harada Mori filter paper tube method
  - Petridish (slant culture) technique
  - Baermann funnel technique
  - Charcoal culture method
  - Agar Plate technique (more sensitive)
- Serology (detection of antibodies)—ELISA, luciferase immunoprecipitation assay
- Molecular diagnosis—real time PCR

**Strongyloides stercoralis**

**Table 12.8:** Complications of strongyloidiasis

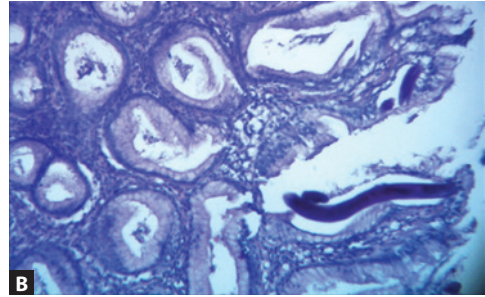
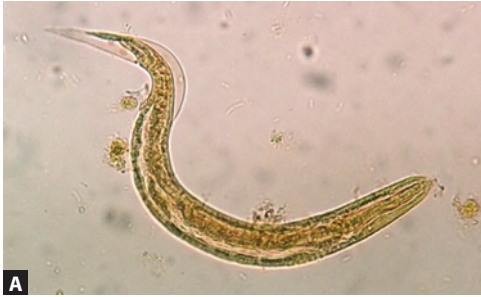**Hyperinfection syndrome**

- Repeated autoinfection cycles lead to generation of large number of filariform larvae
- **Risk factor:** Impaired host immunity favors larva multiplication
  - Glucocorticoid therapy is the main risk factor
  - Other risk factors include use of tumor necrosis factor alpha (TNF-α) inhibitors and other immunosuppressive drugs, hematologic malignancies, impaired gut motility, hypochlorhydria and diabetes or other debilitating chronic diseases
  - Hyperinfection syndrome is often co-infected with human T cell lymphotropic virus type I. Serum immunoglobulin E (IgE) level becomes low in the co-infected patients
  - Co-infection with HIV is rare. This may be due to a decrease in production of T helper (Th1) cytokines and increase in Th2 cytokines in strongyloidiasis
- **Features:** Colitis, enteritis, or malabsorption, and in severe cases disseminated strongyloidiasis may develop
- **Disseminated strongyloidiasis:**
  - Larvae may invade the GIT and migrate to various organs including central nervous system (CNS), peritoneum, liver, and kidneys
  - Moreover, the passage of enteric flora through disrupted mucosa lead to Gram-negative sepsis, pneumonia, or meningitis which may dominate the clinical course
  - CNS invasion, brain abscess and meningitis are common. Larvae can be seen in cerebrospinal fluid (CSF)
- Eosinophilia is often absent in severely infected patients
- The mortality rate in untreated patients approaches 100% and even with treatment it may exceed 25%.



**Table 12.9:** The differences between filariform larva of hookworm and *Strongyloides stercoralis*

Filariform larva	Hookworm	<i>Strongyloides</i>
Size	720 µm long	630 µm long × 16 µm width
Esophagus	Shorter	Long and cylindrical
Tail	Long pointed tail	Blunt and notched



**Figs 12.14A and B:** Rhabditiform larva of *Strongyloides stercoralis* (A) iodine mount; (B) histopathology from Intestinal biopsy (hematoxylin and eosin stain)

Source: B- HOD, Department of Pathology, Meenakshi Medical College, Chennai (with permission)

## Laboratory Diagnosis

### Microscopy

The rhabditiform larvae can be demonstrated in stool by direct microscopy or following concentration techniques (Fig. 12.14A).

- Sometime, the hookworm eggs may hatch in the stool releasing the rhabditiform larva which has to be differentiated from that of *S. stercoralis* (Table 12.7 and Figs 12.10 and 12.12).
- Single stool examination is less sensitive (30%) due to irregular and low output of larvae. Hence repeated stool examination (four consecutive samples) is required.
- **Enterotest:** Sometime duodenal aspirate can be collected by enterotest (described in Chapter 4) and examined for the presence of larva
- Disseminated strongyloidiasis can be readily diagnosed by examining stool, sputum, other body fluids, and tissues, which typically contain high numbers of filariform larvae.

### Stool Culture

Freshly passed stool samples should be cultured.

- L<sub>3</sub> stage filariform larvae are formed within 2 days which should be differentiated from that of hookworm (Table 12.9, Figs 12.10 and 12.12)
- Various culture techniques can be used (described in detail in Chapter 15). They are:
  - Harada Mori filter paper tube method
  - Petridish (slant culture) technique
  - Baermann funnel technique
  - Charcoal culture method
  - Agar plate technique (more sensitive).

### Serology

Enzyme-linked immunosorbent assay (ELISA) using crude larval antigens has a greater sensitivity (95%) and should be used when microscopic examinations are negative. However, it is less specific because of cross-reactivity with other helminthic infection. More so, antibody detection cannot differentiate recent and past infection.



Luciferase immune-precipitation assay has been developed to detect IgG antibodies to a recombinant *S. stercoralis* immunoreactive antigen. It has sensitivity and specificity approaching 100%.

**Molecular Diagnosis**

A real-time polymerase chain reaction (PCR) to detect *Strongyloides* DNA in fecal samples has been developed and it has achieved 100% specificity and high sensitivity.

**Prevention**

Same as for hookworm and other intestinal nematodes.

Treatment	Strongyloides stercoralis
<ul style="list-style-type: none"><li>• Even in the asymptomatic stage, strongyloidiasis must be treated because of the potential for subsequent fatal hyperinfection</li><li>• Ivermectin (200 mg/kg daily for 2 days) is more effective than albendazole (400 mg daily for 3 days)</li><li>• For disseminated strongyloidiasis: Prolonged course of Ivermectin should be given at least 5–7 days or until the parasites are eradicated.</li></ul>	

■ **STRONGYLOIDES FUELLEBORNI**

It is a parasite affecting monkeys and apes.

- Occasionally, it causes human infection
- **Swollen belly syndrome:** It is a serious life threatening condition characterized by diarrhea, respiratory distress and protein losing enteropathy leads to hypoalbuminaemia and edema
- It is seen commonly in infants of Western Papua and New Guinea
- It is diagnosed by detecting the eggs but not larvae in the stool (different from *S. stercoralis*).

■ **ASCARIS LUMBRICOIDES**

*Ascaris lumbricoides* is the largest nematode parasitizing the human intestine. The name

is derived from *Askaris* means intestinal worm and *Lumbricus* means resembling with common earthworm. It is commonly called as **round worm**.

**Epidemiology**

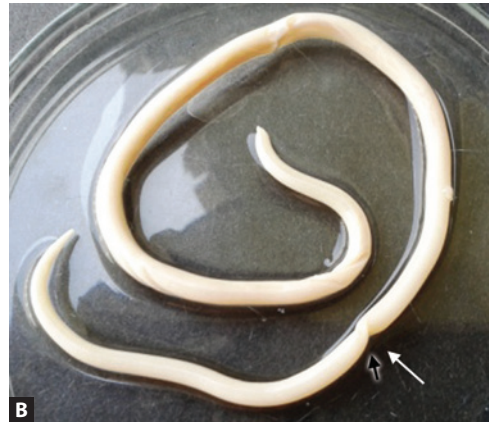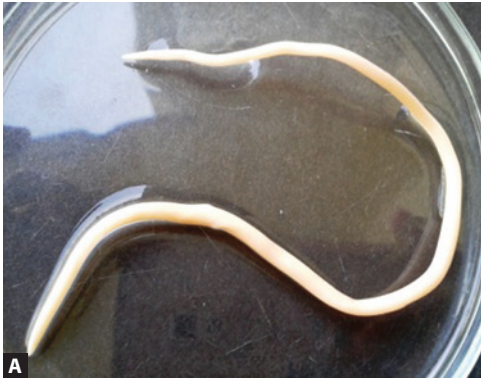*A. lumbricoides* is cosmopolitan in distribution, mainly affecting tropical countries including India.

- It is estimated that, 1470 million people are infected globally out of which around 120–250 million of people are symptomatic
- Transmission typically occurs through fecally contaminated soil and is due to either lack of sanitary facilities or use of human feces as fertilizer
- Clay soils are the most favorable for the development of *Ascaris* egg (in contrast to moist porous soil required for hookworm)
- **Risk factors:** Children (most important disseminator of the disease) and malnutrition.

**Morphology**

**Adult Worm**

- **Appearance:** Pinkish creamy in color when freshly passed from intestine, but gradually fades color and looks whitish
- **Size:** Female worms (20–35 cm) are longer than male worms (15–31 cm). Adult worms life span is 1–2 years
- **Shape:** Cylindrical (hence called as round worm); with tapering ends (tapering is more anteriorly)
- **Mouth part:** The mouth opens anteriorly and bears three characteristic toothed lips (one dorsal and two ventral). The character of the toothed lip is used to differentiate *A. lumbricoides* and *A. suum*
- **Body cavity:** Filled with a characteristic fluid called as **ascaron** or **ascarase** in which the intestine and genital organs float. This fluid is irritant in nature and if leaked, then can cause allergic manifestations
- **Male:** The posterior end is curved and



**Figs 12.15A and B:** *Ascaris lumbricoides* (A) adult male; (B) adult female (arrow shows vulvar waist)  
Courtesy: HOD, Department of Microbiology, Meenakshi Medical College, Chennai

pointed bearing two spicules. Rectum and genital duct open together at cloaca near the posterior end (Fig. 12.15 A)

- **Females:** Posterior end is straight and pointed. Anus is sub-terminal and situated posteriorly while the vulva is situated at the junction of anterior and middle third of the body (on the ventral surface). This portion of the worm is narrower and referred to as **vulvar waist** (Fig. 12.15B)
- Other features are similar to any nematode described in the beginning of the chapter.

### Egg

Two types of eggs are liberated from the female worm of *A. lumbricoides*—(1) fertilized and (2) unfertilized eggs (Table 12.10)

Sometime, the fertilized eggs may lose the thick mamillated albuminous coat. Such types of eggs are called as decorticated eggs.

### Larva

There are four stages of *Ascaris* larvae ( $L_1$  to  $L_4$ ).

### Life Cycle (Fig. 12.16)

**Host:** Involves only one host (man).

**Infective stage:** Embryonated eggs containing the  $L_2$  larvae.

**Mode of transmission:** Ingestion of embryonated eggs from the contaminated soil, food and water.

### Migratory Phase

Following ingestion, the eggs hatch out to liberate the  $L_2$  larvae (250  $\mu\text{m}$  long) in the duodenum.

- The  $L_2$  larvae molt once ( $L_3$ ) and penetrate the intestine, reach right side of heart via portal circulation and finally enter the lungs via pulmonary capillaries
- Within 6–10 days in lungs, the larvae mature to become 550  $\mu\text{m}$  long, molt to form next stage larvae ( $L_4$ )
- The larvae break up into the alveoli, migrate via bronchi, trachea and pharynx and finally swallowed to reach intestine.

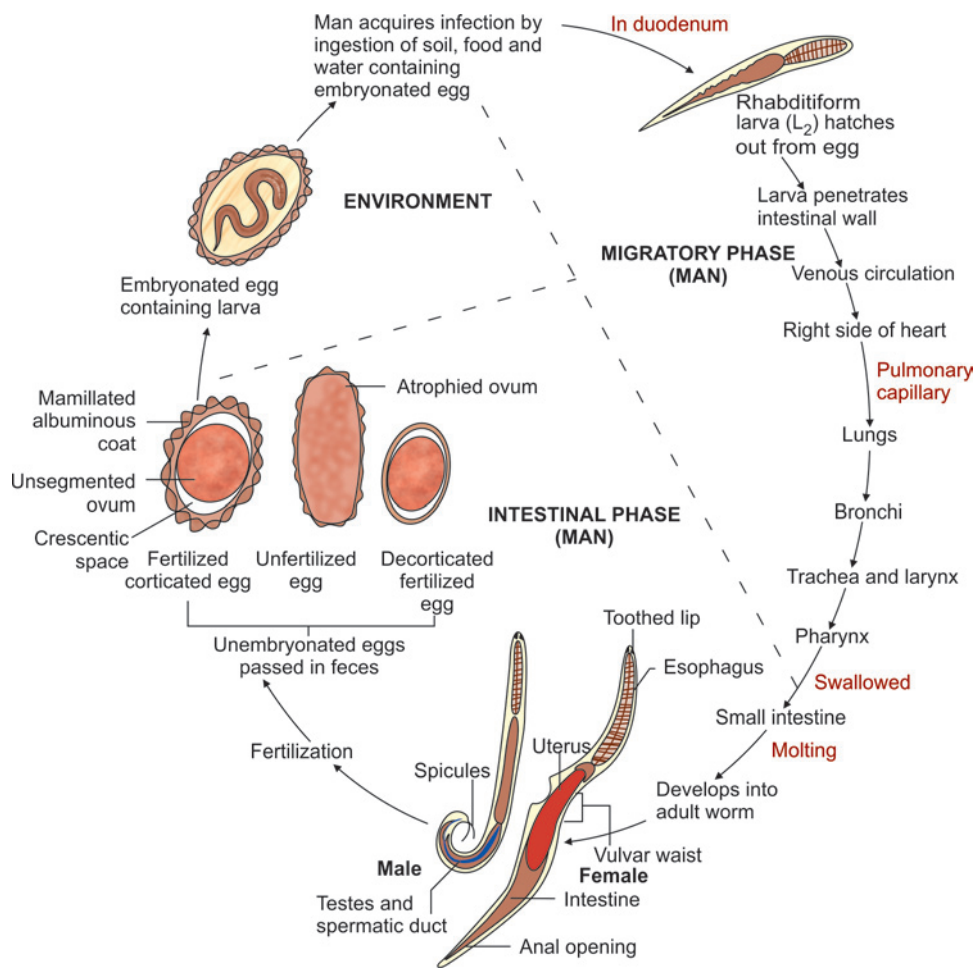
### Intestinal Phase

The larvae undergo final molt to develop into adult worms in the small intestine. Adults become sexually mature, fertilize and the female worms start laying the fertilized eggs which are passed in the feces. Sometime, before mating, the female worms may directly lay the unfertilized eggs.

**Pre-patent period:** It is the time from egg ingestion to egg passage in the feces and is around 8–12 weeks.

**Table 12.10:** Differences between fertilized and unfertilized eggs of *Ascaris* species

	<i>Fertilized eggs</i>	<i>Unfertilized eggs</i>
Shape	Round to oval	Elongated
Size	50–70 µm × 40–50µm	90 µm × 45 µm
Covering (egg shell)	Surrounded by a thick mamillated, albuminous coat	Albuminous coat is thin, distorted and scanty
Crescentic space at poles	Present	Absent
Bile staining	Yes, golden brown in saline mount	Yes, golden brown in saline mount
Saturated salt solution	Floats	Doesn't float
Ovum	Egg contains a large unsegmented ovum of granular mass with clear space at both the end	Egg contains an unsegmented, small atrophied ovum with a mass of disorganized highly refractile granules



**Fig. 12.16:** Life cycle of *Ascaris lumbricoides*

A gravid female can lay 2.4 lakh eggs/day. The female worm survives for 1–2 years.

### Development in Soil

The fertilized eggs become embryonated in 10–14 days under suitable conditions such as warm and clay soil, 22–30°C and 40% humidity.

- Rhabditiform larvae ( $L_1$ ) are produced inside the eggs which then molt to produce  $L_2$  larvae. Embryonated eggs containing the  $L_2$  larva are the infective stage.
- *Ascaris* embryonated eggs survive for as long as 15 years as they are highly resistant due to the characteristic thick egg shell. *Ascaroside*, a lipoprotein present in the egg shell is responsible for its resistant to disinfectants
- The unfertilized eggs are not infective, they disintegrate in some time.

### Pathogenesis and Clinical Feature

#### Affect Due to Migrating Larva

- **Pulmonary symptoms:** Observed in the second week after ingestion of eggs. Migrating larvae in lungs provoke an immune-mediated hypersensitivity response. Common symptoms include a non-productive cough, chest discomfort and fever
- **Eosinophilic pneumonia (Loeffler's syndrome):** In severe cases, patients develop dyspnea and an transient patchy infiltrates seen on chest X-ray along with peripheral eosinophilia.

#### Affect Due to Adult Worm

- **Asymptomatic:** Most people with mild *Ascaris* infections are asymptomatic
- **Malnutrition and growth retardation:** Robbing the nutrition from the host may result in chronic malnutrition and growth retardation (in children)
- **Intestinal complications:** A large bolus of entangled worms can cause acute pain

abdomen due to small-bowel obstruction, rarely perforation, **intussusception**, or volvulus

- **Extraintestinal complications:** Larger worms can enter and occlude the biliary tree, causing biliary colic, cholecystitis, pancreatitis, or (rarely) intrahepatic abscesses. Wandering worms may migrate to pharynx and can cause respiratory obstruction or may block the eustachian tube
- **Allergic manifestations** like fever, urticaria, angioneurotic edema and conjunctivitis may occur due to toxic fluid (ascaron or ascarase) released by the adult worm.

#### Laboratory Diagnosis

*Ascaris lumbricoides*

- Detection of the parasite.
  - Egg detection (stool examination)—fertilized and unfertilized eggs
  - Adult worm detection—X-ray (Trolley car lines), USG and Barium meal of GIT
  - Larva detection (sputum/gastric aspirate)
- Serology (antibody detection)—ELISA, IFA, IHA test
- Other findings such as eosinophilia and charcot leyden crystals in sputum and stool

### Laboratory Diagnosis

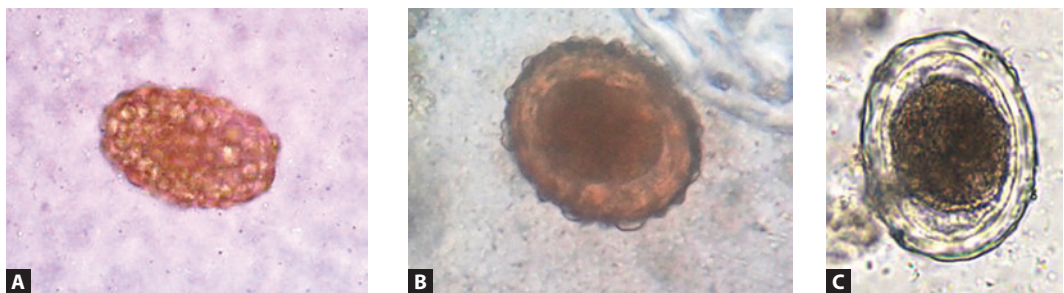
#### Detection of the Parasite

##### Egg detection

Both fertilized and unfertilized eggs can be detected by stool examination by saline and iodine wet mount. (Refer Table 12.10). Concentration techniques by sedimentation method should be done if direct stool microscopy is negative. Floatation method for stool concentration is not preferred as unfertilized eggs don't float on saturated salt solution (Figs 12.16 and 12.17).

##### Adult worm detection

Occasionally, adult worms may be detected in stool or sputum of the patients by naked eye.



**Figs 12.17A to C:** Eggs of *Ascaris lumbricoides* (saline mount) (A) unfertilized egg; (B) fertilized egg; (C) decorticated fertilized egg

Barium meal X-ray of the GIT may demonstrate the adult worms in the intestine. When two worms are lying parallel, gives *trolley car lines* appearance in X-ray. Ultrasound (USG) or cholangiopancreatography should be done to detect the adult worm in extraintestinal sites.

**Larva detection**

During the early pulmonary migratory phase, larvae can be found in sputum or gastric aspirates before the eggs appear in the stool.

**Serology**

Antibodies can be detected by methods such as:

- ELISA
- IFA (Indirect fluorescent antibody test)
- IHA (Indirect hemagglutination test)
- Micro precipitation test using larva

Serology is useful:

- In pulmonary phase (In case stool microscopy fails)
- For seroepidemiological purpose

**Other Methods**

- Eosinophilia is prominent during the early lung stage, but disappears later
- Presence of Charcot-Leyden crystals in sputum and stool.

Treatment	Ascaris lumbricoides
<b>Antiparasitic drugs</b>	
<ul style="list-style-type: none"><li>• Ascariasis should always be treated early to prevent potentially serious complications</li><li>• Albendazole (400 mg once), mebendazole (100 g twice daily for 3 days or 500 mg once) is effective</li><li>• Alternate drugs like ivermectin (150–200 mg/kg once) and nitazoxanide are also effective</li><li>• In pregnancy, pyrantel pamoate is safe</li></ul>	
<b>Symptomatic treatment</b>	
<ul style="list-style-type: none"><li>• Partial intestinal obstruction should be managed with nasogastric suction, intravenous (IV) fluid administration but complete obstruction and its severe complications like intussusception require immediate surgical intervention.</li></ul>	

**Prevention**

Same as for other soil transmitted helminths like hookworm and *Trichuris*.

**ASCARIS SUUM**

*Ascaris suum*, also known as large **round worm** of pig, causes **ascariasis** in pig. Some authors believe that *A. lumbricoides* is the ancestor, from which it is derived.



- **Life cycle:** The human (or pig) ingests the egg with an L<sub>2</sub> larva inside. Life cycle is similar to that of *A. lumbricoides*
- **Clinical feature:** Human infection is rare.
  - Most of the infections are asymptomatic
  - Rarely, the adult worms penetrate into the intestinal mucosa leading to intestinal manifestations
- Migration to lungs can cause *Ascaris* pneumonitis
- **Laboratory diagnosis:** It is done by detection of eggs by stool examination which is morphologically identical to that of *A. lumbricoides*. Only the adult worms are slightly different by the characteristic toothed lip at the anterior end.

### EXPECTED QUESTIONS

#### I. Write essay on:

- Classify intestinal nematodes. Describe the life cycle, pathogenesis and laboratory diagnosis of *Strongyloides stercoralis*?
- Describe the life cycle, pathogenesis and laboratory diagnosis of hookworm?

#### II. Write short notes on:

- Trichuriasis
- Enterobius vermicularis*
- Hyperinfection syndrome
- Ascariasis

#### III. Differentiate between:

- Acylostoma duodenale* and *Necator americanus*
- Filariform larva of *Acylostoma duodenale* and *Strongyloides stercoralis*
- Rhabditiform larva of *Acylostoma duodenale* and *Strongyloides stercoralis*
- Fertilized and unfertilized egg of *Ascaris*
- Male and female worm of *Acylostoma duodenale*

#### IV. Multiple choice questions:

- All of the following nematodes are oviparous EXCEPT:
  - Roundworm
  - Strongyloides*

- Hookworm
- Enterobius*

#### 2. Common name of *Trichuris trichiura* is:

- Pin worm
- Round worm
- Hook worm
- Whip worm

#### 3. *Ascaris* infects humans by:

- Penetration of skin by infective larvae
- Ingestion of unembryonated eggs present in contaminated food and water
- Ingestion of embryonated eggs present in contaminated food and water
- Autoinfection

#### 4. Larva currens is caused by:

- Ascariasis
- Cutaneous larva migrans
- Strongyloidiasis
- Toxocara canis*

#### 5. Number of eggs laid down by a female *Ascaris lumbricoides* in a day is about:

- 5,000
- 20,000
- 1,00,000
- 2,40,000

### Answer

1. (b)    2. (d)    3. (c)    4. (c)    5. (d)



# 13 Nematodes—II (Nematodes of Lower Animals that Rarely Infect Man)

## Chapter Outline

- Classification
- Larva migrans
  - General properties
  - Toxocariasis
  - Angiostrongylus species
  - Baylisascaris species
  - Lagochilascaris species
  - Anisakiasis
  - Gnathostoma species
- Other animal nematodes
  - Capillaria species
  - Trichostrongylus species (Pseudo hookworm)
  - Dioctophyme species
  - Oesophagostomum species
  - Ternidens species
  - Mammomonogamus laryngeus
  - Thelazia species
- Expected questions

## ■ CLASSIFICATION

This chapter reviews the less common zoonotic infections in humans caused by nematodes of lower animals. Humans are not the natural host for these parasites. Human infections are accidental; they are not able to complete their life cycle in humans as they do in the animal host. The disease process differs accordingly which may not resemble that of the animal host. The classification is given in Table 13.1. Filariar zoonotic infection is discussed in Chapter 14.

## LARVA MIGRANS

### ■ GENERAL PROPERTIES

The life cycle of most of the human nematodes involve penetration of the skin by the larval stage followed by migration of the larvae to intestine, lungs or other organs.

However, the larvae of lower animal nematodes when accidentally infect man, they are not able to complete their normal development (because humans are the unusual host for them) and their life cycle gets arrested. The larvae wander around aimlessly in the body. This is called as **larva migrans (LM)**.

Two types of larva migrans exists:

1. **Cutaneous larva migrans:** Also called as **creeping eruption**. Larva migration occurs in skin and subcutaneous tissue.
2. **Visceral larva migrans:** Larva migration takes place in viscera.

### Cutaneous Larva Migrans

#### Etiology

Cutaneous larva migrans (CLM) is mainly caused by filariform larvae of nonhuman hookworm species such as *Ancylostoma*

**Table 13.1:** Nematodes of lower animals that rarely infect humans

Genus	Species	Primary host	Localized in man	Infective form	Disease in man
<i>Toxocara</i>	<i>T. canis</i> (Dog round worm)	Dog	Liver or other viscera	Eggs (ingestion)	Visceral larva migrans (hepatomegaly)
	<i>T. cati</i> (Cat round worm)	Cat			
<i>Anisakis</i>	<i>A. simplex</i>	Sea mammal	Intestine	L <sub>3</sub> larva (ingestion)	Eosinophilic granuloma of bowel
<i>Angiostrongylus</i>	<i>A. cantonensis</i>	Rat lung worm	CNS	L <sub>3</sub> larva (ingestion)	Eosinophilic meningitis
	<i>A. costaricensis</i>	Rat	Ileocecum	L <sub>3</sub> larva (ingestion)	Abdominal angiostrongyliasis
<i>Baylisascaris</i>	<i>B. procyonis</i>	Raccoon	CNS	Eggs (ingestion)	Eosinophilic meningoencephalitis
<i>Lagochilascaris</i>	<i>L. minor</i>	Feline	Skin	Inggestion of larva	Subcutaneous lesions
<i>Ancylostoma</i>	<i>A. braziliensis</i>	Dog and cat	Skin	L <sub>3</sub> larva (skin penetration)	Cutaneous larva migrans
	<i>A. caninum</i>	Dog			
	<i>A. ceylanicum</i>	Cat			
<i>Gnathostoma</i>	<i>G. spinigerum</i>	Dog and cat	Skin, CNS and eye	L <sub>3</sub> larva (ingestion of fish)	Cutaneous larva migrans, cerebral and ocular infection
<i>Capillaria</i>	<i>C. philippinensis</i>	Fish eating bird	Intestine	L <sub>3</sub> larva (ingestion of fish)	Malabsorption
	<i>C. hepatica</i>	Rodent	Liver	Eggs (ingestion)	Hepatitis and hepatomegaly
	<i>C. aerophila</i>	Carnivores	Trachea and bronchus	Eggs (ingestion)	Tracheobronchitis
<i>Thelazia</i>	<i>T. callipaeda</i>	Dog	Conjunctiva	L <sub>3</sub> larva (insect bite)	Lacrimation and itching of eye
<i>Trichostrongylus</i>	<i>T. colubriformis</i>	Sheep, goat and camel	Intestine	L <sub>3</sub> larva (ingestion)	Mild anemia
	<i>T. orientalis</i>	Monkey	Intestine	L <sub>3</sub> larva (ingestion)	Nodular lesions of the intestinal wall
<i>Oesophagostomum</i>	<i>O. bifurcum</i>	Monkey	Intestine	L <sub>3</sub> larva (ingestion)	Chronic cough and hemoptysis
	<i>O. aculeatum</i>	Cattle	Larynx and trachea	L <sub>3</sub> larva (ingestion)	Pulmonary and intestinal symptoms
<i>Mammomonogamus</i>	<i>M. laryngeus</i>	Pig	Lungs and Intestine	Egg ingestion	Swollen belly syndrome
<i>Ascaris</i>	<i>A. suum</i>	Monkey	Intestine	L <sub>3</sub> larva (skin penetration)	Anemia, pseudotumors and abscess of bowel
<i>Strongyloides</i>	<i>S. fuelleborni</i>	Ape and monkey	Intestine	L <sub>3</sub> larva (ingestion)	Hematuria
<i>Ternidens</i>	<i>T. deminutus</i>	Carnivorous (mink)	Kidney	L <sub>3</sub> larva (ingestion)	
<i>Diactophyma</i>	<i>D. renale</i>	Carnivorous (mink)	Kidney	L <sub>3</sub> larva (ingestion)	

Abbreviations: CNS, central nervous system; L<sub>3</sub>, filariform larva

*brasiliensis*, *A. caninum* and *A. ceylanicum*. Others can rarely cause CLM (Table 13.2).

**Arrested Life Cycle and Pathogenesis**

**Host:** Felines act as natural hosts. Humans are abnormal accidental host.

**Infective stage:** Filariform larva (L<sub>3</sub>)

**Mode of transmission:** Penetration of skin by filariform larva (L<sub>3</sub>) present in moist and warm soil contaminated with animal feces.

Man being the unnatural host, they can neither develop further nor migrate to intestine. Instead, they wonder in the superficial layers of the skin of feet, legs and thigh, buttock and back and provoke allergic reaction in previously sensitized patients that leads to:

- **Ground itch:** Pruritic maculopapular dermatitis and rashes (ground itch) at the site of skin penetration of hookworm larva
- **Larva currens:** Migrating *Strongyloides* larvae produce the pathognomonic serpiginous urticarial rash called as **larva currens** near the legs.

**Laboratory Diagnosis**

Diagnosis is made mainly by clinical feature. Larvae are usually not detected in skin biopsy.

- No eosinophilia though there is cellular eosinophilic infiltration in the skin
- No immunological test is available.

Treatment	Cutaneous larva migrans
	<ul style="list-style-type: none"><li>• Oral and topical thiabendazole is effective</li><li>• Freezing the advancing end of creeping eruption in ethyl chloride is useful.</li></ul>

**Visceral Larva Migrants**

In visceral larva migrans (VLM) migration of the infective larva and arrest of life cycle takes place in visceral organs.

- It is caused primarily by infection with *Toxocara* but less frequently caused by other helminths (Table 13.2).
- The further discussion of VLM is done for toxocariasis. Other rare agents of VLM are described later.

**TOXOCARIASIS**

- *Toxocara* species belong to family ascariidae which also includes *Ascaris*, *Baylisascaris* and *Lagochilascaris*
- Two important species are *T. canis* (dog roundworm) and *T. cati* (cat round worm).

**Table 13.2:** Etiology of larva migrans (LM)

Causes of cutaneous larva migrans (CLM)	Causes of visceral larva migrans (VLM)
<ul style="list-style-type: none"><li>• Important cause (nonhuman <i>Ancylostoma</i> spp.)<ul style="list-style-type: none"><li>– <i>A. brasiliensis</i></li><li>– <i>A. caninum</i></li><li>– <i>A. ceylanicum</i></li></ul></li><li>• Occasional human nematodes may cause<ul style="list-style-type: none"><li>– <i>Strongyloides stercoralis</i></li><li>– <i>Ancylostoma duodenale</i></li><li>– <i>Necator americanus</i></li></ul></li><li>• Other rare nematodes<ul style="list-style-type: none"><li>– <i>Gnathostoma spinigerum</i></li><li>– <i>Uncinaria stenocephala</i></li><li>– <i>Bunostomum phlebotomum</i></li></ul></li><li>• Due to non-helminthic agents<ul style="list-style-type: none"><li>– <i>Hypoderma</i> spp.</li><li>– <i>Gastrophilus</i> spp.</li></ul></li></ul>	<ul style="list-style-type: none"><li>• Important cause<ul style="list-style-type: none"><li>– <i>Toxocara canis</i></li><li>– <i>Toxocara cati</i></li></ul></li><li>• Other agents<ul style="list-style-type: none"><li>– <i>Angiostrongylus</i>—<i>A. cantonensis</i> and <i>A. costaricensis</i></li><li>– <i>Gnathostoma spinigerum</i></li><li>– <i>Anisakis</i> spp.</li><li>– <i>Baylisascaris procyonis</i></li></ul></li></ul>

## Epidemiology

Toxocariasis is prevalent wherever dogs or cats are found and *Toxocara* eggs are able to survive.

## Risk Factor

- Children younger than 6 years
- Exposure to contaminated soil
- Rural area.

## Morphology

- Male and female worms measure 9–13 cm and 10–18 cm, respectively. Anterior end bears lateral cervical alae. Males have a curved caudal end (Fig. 13.1A).
- Eggs are oval to spherical with a pitted surface and measure from 72–85  $\mu\text{m}$ .

## Life Cycle (Arrested) and Pathogenesis

**Host:** Felines are the natural host. Humans act as abnormal host.

**Infective stage:** Embryonated eggs (Fig. 13.1B).

**Mode of transmission:** Ingestion of embryonated eggs contaminated in soil. Vertical transmission is observed in dogs.

## Development in Human/Felines

Larvae hatch out from the eggs in human intestine, penetrate the intestinal wall and carried via the portal circulation to the liver.

- The larvae may remain in liver or migrate to other organs like lungs or eye
- Since humans are the unusual host for these animal nematodes, further development of the larvae doesn't take place

- Instead, the larvae get encapsulated in dense fibrous tissue in liver (most common site) or lungs or may continue to wander around the body producing granuloma.

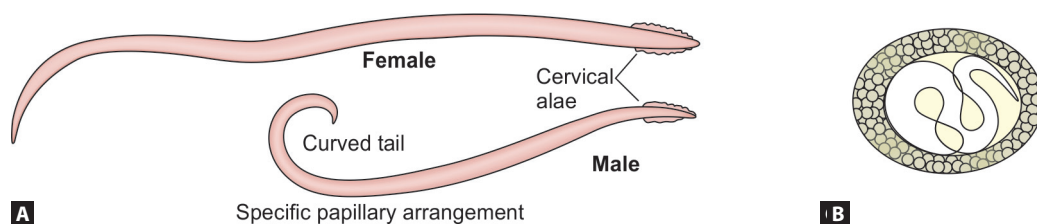
## Clinical Features

- **Hepatomegaly:** The liver is the most frequently involved organ. But any organ can be affected
- Other features includes lymphadenopathy, lung involvement, skin lesions (urticaria and nodules) and seizures
- **Ocular larva migrans:** Most common cause is *Toxocara* larva
  - Unilateral painless chorioretinal granuloma in the posterior pole is the most common presentation
  - But in some cases, diffuse pan-uveitis, retinal detachment and unilateral visual loss may occur.

## Laboratory Diagnosis

Diagnosis is often difficult and mainly stay on:

- **Serology:** Enzyme-linked immunosorbent assay (ELISA) employing excretory secretory antigen of larva of *T. canis* is highly sensitive and specific. It can confirm the infection but may also be elevated in asymptomatic patients
- Biopsy of the tissue from liver, lungs, brain may occasionally reveal the larvae
- Blood eosinophilia
- Increased gamma globulin level.



**Figs 13.1A and B:** *Toxocara* species (schematic diagram): (A) adult worms; (B) embryonated egg

Treatment	Toxocariasis
<ul style="list-style-type: none"><li>• Symptomatic treatment</li><li>• DEC (diethylcarbamazine)—100 mg thrice daily for 3 weeks can kill the larva and arrest the disease.</li></ul>	

■ **ANGIOSTRONGYLUS SPECIES**

- *A. cantonensis* causes **eosinophilic meningitis**
- *A. costaricensis* causes **abdominal angiostrongyliasis**
- *A. malaysiensis* rarely infect man, causes **abdominal angiostrongyliasis**.

**Eosinophilic Meningitis**

**Agent**

*A. cantonensis* is also called as the **rat lung worm**.

**Epidemiology**

This infection occurs principally in South-East Asia and the Pacific Basin but has also been reported from other areas of the world.

**Life Cycle**

**Host:** Rat is the natural **definitive host**. Humans are accidental **definitive host**. **Intermediate hosts** are land snails and slugs. **Mode of transmission:** Man (or rat) acquires infection by ingestion food or water contaminated with infective L<sub>3</sub> larvae (present in snail or slugs).

**Development in man**

The infective larvae penetrate the intestine and through the blood circulation, they migrate to the central nervous system (CNS). Here, they molt twice to become adult worms.

As man is an abnormal host, adult worms die soon and cause a serious condition known as **eosinophilic meningitis**.

**Development in rodents**

In rodents, from CNS the adults migrate to lungs via blood. Adult worms lay eggs in the

lungs, which are swallowed and are expelled in the feces.

Eggs are ingested by intermediate host (mollusks like land snails and slugs), where they develop into infective third-stage larvae.

**Clinical Features**

- Migrating larvae cause marked local eosinophilic inflammation and hemorrhage, with subsequent necrosis and granuloma formation around the dying worms
- Clinical symptoms develop 2–35 days after the ingestion of larvae
- Patients usually present with headache, neck stiffness, nausea and vomiting, and paraesthesia
- Fever, cranial nerve palsies, and seizures are the less frequent findings.

**Laboratory Diagnosis**

The diagnosis is generally based on the clinical presentation with epidemiologic history.

- Examination of cerebrospinal fluid (CSF) can reveal:
  - Elevated CSF pressure
  - White blood cell count
  - Eosinophilic pleocytosis of more than 20%
  - Elevated proteins
  - Normal glucose level
- Rarely, the larvae of *A. cantonensis* are seen in CSF
- Peripheral blood eosinophilia may be mild
- Western blot is available; detects antibody against 31-kDa antigen. But it may cross react with *Toxocara*.

Treatment	Eosinophilic meningitis
<ul style="list-style-type: none"><li>• Specific chemotherapy is not beneficial because larvicidal agents like albendazole may exacerbate inflammatory brain lesions</li><li>• Management consists of supportive measures, including the administration of analgesics, sedatives and in severe cases-glucocorticoid is given to reduce inflammation.</li></ul>	

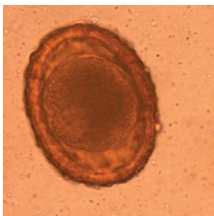
### Abdominal Angiostrongyliasis

- **Agent:** *A. costaricensis* (or rarely *Angiostrongylus malaysiensis*).
- **Epidemiology:** Infection has been recognized commonly in Central and South America, occasionally the Caribbean and Africa.
- **Life cycle:** Similar to *A. cantonensis* except that the adults migrate to arteries and arterioles of ileocecal region and lay eggs. Both eggs and adult worms provoke an inflammatory response in the ileocecal arteries and arterioles which results in occluded vessels, accompanying vasculitis and an eosinophilic granulomatous abdominal mass.
- **Clinical Features:** Characterized by abdominal pain, vomiting, and a right lower quadrant mass commonly in children.

### BAYLISASCARIS PROCYONIS

*Baylisascaris procyonis* belongs to the superfamily Ascaridoidea.

- The life cycle is similar to that of *Toxocara*
- Infection occurs after ingestion of eggs excreted in raccoon feces that subsequently contaminates soil and the environment (Fig. 13.2)
- Although the clinical manifestations are similar to those caused by dog and cat ascarids, severe and commonly fatal eosinophilic meningoencephalitis occurs in more than half of the cases



**Fig. 13.2:** Unfertilized egg of

*Baylisascaris procyonis* (under microscope)

Source: DPDx Image Library, Centre for Disease Control and prevention (CDC), Atlanta (with permission)

- Eye involvement can cause diffuse unilateral sub-acute neuroretinitis.
- The diagnosis is established by detecting typical larvae in tissues; an experimental serologic examination has been reported but is not routinely available
- There is no proven therapy. Amongst of the available drugs, albendazole and corticosteroids are most commonly tried.

### LAGOCHILASCARIS MINOR

- It belongs to the superfamily Ascaridoidea
- Females (15 mm) are longer than the males (9mm). Eggs are similar to that of *Toxocara*
- **Epidemiology:** It has been reported from Mexico, Central and South America. More than 100 cases are reported from Amazon region
- **Life cycle:** Felines (and rarely men) act as **definitive host** and wild rodents are the **intermediate hosts**. Humans get infection by ingestion of either uncooked or lightly cooked rodent meat containing encysted larvae
- **Clinical features:** Symptoms vary from mild subcutaneous purulent lesions or abscesses on the side of the neck (or over mastoid) to more severe manifestations involving the CNS
- **Diagnosis:** Recovery of eggs, larvae and adult worms from the lesions
- **Treatment:** Definite treatment is surgery. Levamisole is found to be effective.

### ANISAKIASIS

- *Anisakiasis* is caused by the accidental infection of humans by larvae found in saltwater fish and squid. **Definitive hosts** are marine mammals
- **Epidemiology:** The disease is first reported from Netherlands. Now cases are reported from the USA because of increased ingestion of raw fish, particularly Pacific salmon
- **Etiology:**
  - **Anisakis simplex:** Most common cause of Anisakiasis; acquired from saltwater



► **Other agents:**

- *Pseudoterranova* species
- *Contracaecum* species
- *Hysterothylacium* species
- *Porrocaecum* species.

- **Life cycle:** By ingestion of larvae found in saltwater fish and squid into the stomach or small intestine. Larvae make burrows into the stomach or intestine
- **Clinical feature:** It is characterized by upper or lower abdominal symptoms, or both
- **Laboratory diagnosis:** The diagnosis is suggested by a history of ingesting raw, salted, pickled, smoked, or poorly cooked fish.

Definitive diagnosis can be established by demonstration of the larva by endoscopy, radiographic studies, or pathologic examination of tissues.

Treatment	Anisakiasis
<ul style="list-style-type: none"> <li>• By removing worms lodged in the stomach during endoscopy.</li> <li>• Albendazole is effective.</li> </ul>	

## ■ GNATHOSTOMA SPECIES

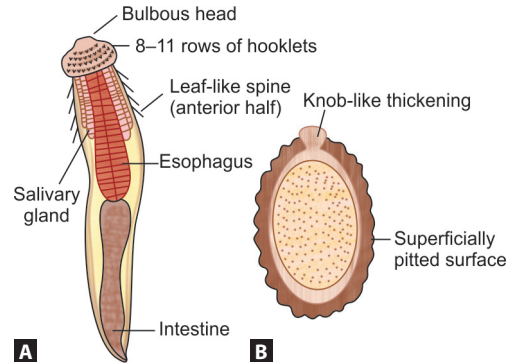
*Gnathostoma spinigerum* belongs to the order Spirurida and superfamily Gnathostomatoidea.

### Epidemiology

Endemic in Southeast Asia (Thailand) and parts of China and Japan.

### Morphology

- Adult males and females are 12–30 mm and 15–33 mm long respectively. Head bulb bears 8–11 rows of cuticular hooklets. Anterior half has leaf-like spines where as the posterior half is smooth. Esophagus is surrounded by four salivary glands (Fig. 13.3)



**Fig. 13.3A and B:** *Gnathostoma spinigerum* (schematic diagram) (A) adult worm; (B) egg

- Eggs are oval, 69  $\mu\text{m}$   $\times$  38  $\mu\text{m}$  size, superficially pitted and bear a knob-like thickening at one pole (Fig. 13.3)
- **L<sub>3</sub> larva:** 3–4 mm long, covered by cuticular spines and the bulbous head bears four rows of hooklets.

### Life Cycle

**Host:** There are two types of hosts:

1. **Definitive host:** Cat, dogs, and humans act as **accidental definitive host**
2. **Intermediate host:** **First intermediate host**-crustaceans (cyclops) and **second intermediate host**-fresh water fish.

**Modes of transmission:** Humans (or carnivores) usually acquire infection by ingestion of fish containing L<sub>3</sub> larva (or rarely cyclops containing L<sub>3</sub> larva).

### Development in Man

Humans are abnormal host, so the larvae don't develop further; instead they penetrate the intestine and wander aimlessly into cutaneous, visceral, neural, or ocular tissues.

### Development in Cats and Dogs

In cats and dogs, the larvae develop into adult worms that form nodules (tumor-like mass) in the stomach. Adult worms lay eggs; which are passed in feces and hatch out to L<sub>1</sub> larva

which again molts to form  $L_2$  larva in the environment.

### Development in Intermediate Hosts

$L_2$  larva is ingested by cyclops where it molts to form  $L_3$ . Freshwater fishes eat cyclops containing  $L_3$ , but they behave as **paratenic host**, i.e. only maintain the larva without any development and can be infective to humans or carnivores.

### Clinical Features

The migrating larvae of *G. spinigerum* can cause:

- Migratory cutaneous swellings
- Invasive masses of the eye and visceral organs (lungs)
- Eosinophilic meningoencephalitis.

### Diagnosis

- **Clinical diagnosis:** Cutaneous migratory swellings with marked peripheral eosinophilia, supported by an appropriate geographic and dietary history
- **CNS involvement:** CSF shows eosinophilic pleocytosis, but worms are never recovered from CSF
- Surgical removal of the worms or advanced  $L_3$  larvae from subcutaneous or ocular tissues. Speciation can be done based on the number of hooklets in each row of bulbous head
- ELISA using crude antigen extract or excretory secretory antigen has been developed to detect specific immuno-globulin (IgE) or IgG antibodies from serum or CSF.

#### Treatment

#### Gnathostoma

Both ivermectin (200 µg/kg for one dose) and albendazole (400 mg/day for 21 days) give cure rates of more than 90%.

## OTHER ANIMAL NEMATODES

### CAPILLARIA SPECIES

*Capillaria* and *Trichuris* belong to the same family Trichuridae. Their eggs are morphologically similar and often get confused.

It has more than 200 species but only three species infect humans:

1. *C. philippinensis* causes **intestinal capillariasis**
2. *C. hepatica* causes **hepatic capillariasis**
3. *C. aerophila* causes **pulmonary capillariasis**.

### Capillaria philippinensis

This parasite was first reported from Philippines by Chitwood in 1963.

### Epidemiology

It is widespread in Philippines (Northern Luzon area) and Thailand. Recent cases are also reported from Japan, Taiwan, Iran and Egypt.

### Morphology

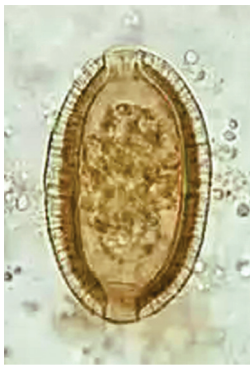#### Adult worm

It is similar to *Trichuris* except that it is a smaller whipworm (female is 2.5–4.3 mm long) and males (2.3–3.17 mm long). They reside in the small intestine.

#### Egg

Eggs also resemble with *Trichuris* eggs except (Fig. 13.4):

- **Size:** smaller (36–45 µm long × 20 µm wide)
- **Shape:** Peanut-shaped (less barrel-shaped)
- Surrounded by striated thick shell
- Mucons plugs present but they are less prominent and don't protrude out like in *Trichuris*.



**Fig. 13.4:** Egg of *Capillaria philippinensis* (under microscope)

Source: DPDx Image Library, Centre for Disease Control and prevention (CDC), Atlanta (with permission)

**Life Cycle**

**Host:** There are two types of hosts:

- 1. **Definitive host:** Fish eating birds are the **natural definitive host** and reservoir of infection. Humans act as the **accidental definitive host**
- 2. **Intermediate host:** Fresh and salt water fish containing the larval stage

**Mode of transmission:** Humans acquire infection by ingestion of undercooked or pickled fishes containing the infective larvae.

**Development in man/birds**

Larvae mature into adult worms in 10–11 days and live burrowed in to the mucosa of small intestine (jejunum).

Adult worms fertilize to lay unembryonated eggs in the feces. Eggs require 10–14 days in the soil to become embryonated.

Some of the eggs become embryonated in the intestine and develop into larval stage that can cause autoinfection. Heavy worm load can lead to hyperinfection.

**Development in fish**

Embryonated eggs in soil are infective to fishes. Following ingestion of the eggs, in the intestine of the fishes eggs hatch out into larval forms, which are infective to man and birds.

**Pathogenesis and Clinical Features**

- Mild to moderate worm load cause nonspecific abdominal pain and watery diarrhea
- Severe worm load can cause intestinal inflammation, loss of villi, crypt proliferation and eosinophilic granuloma
- This leads to severe malabsorption that in turn can cause protein-losing enteropathy and severe weight loss (wasting syndrome)
- Autoinfection is responsible for maintaining the worm load
- Heavy worm load sometime can cause super infection syndrome (like strongyloidiasis).

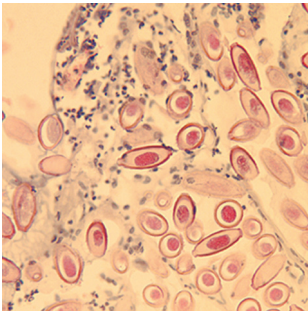
**Laboratory Diagnosis**

By identification of the characteristic peanut-shaped eggs on stool examination. (Fig. 13.4A).

Treatment	Capillaria philippinensis
	<ul style="list-style-type: none"><li>• Prolonged treatment with albendazole (200 mg twice daily for 10 days) is required</li><li>• Severely ill patients require fluid replacement and supportive therapy.</li></ul>

**Capillaria hepatica**

- **Epidemiology:** *C. hepatica* is a parasite of rodents and other small mammals  
Human infection is rare. Cases are reported from Zaire, Nigeria and other parts of West Africa where people eat rodents
- **Life cycle:**  
**Host:** Involves only one host (usually rodents, rarely humans)  
**Mode of transmission:** Ingestion of liver of rodents containing embryonated eggs  
**Development in man/rodents:** Eggs hatch out into larvae that penetrate the intestine and reach the liver via portal circulation where they develop into adult worms. After 4 weeks, the female worms start laying the eggs following fertilization. Eggs become embryonated and encapsulated in the liver parenchyma



**Fig. 13.5:** Egg of *Capillaria hepatica* in liver stained with hematoxylin and eosin

Source: DPDx Image Library, Centre for Disease Control and prevention (CDC), Atlanta (with permission)

- **Clinical feature:** Ranges from hepatitis, hepatomegaly, peritonitis and eosinophilia
- **Laboratory diagnosis:** Depends on the detection of characteristic eggs, larve or adult worms in the liver parenchyma  
Eggs are similar to *C. philippinensis* except that they are larger (51–68 µm long × 30–35 µm wide) (Fig. 13.5).

### Capillaria aerophila

- **Epidemiology:** They commonly infect carnivores, human infection is quite rare. Cases are reported from Russia, Morocco, and Iran
- **Life cycle:** The adult female worms reside in the respiratory tract (both upper and lower) where they lay eggs, that are swallowed, passed in the feces, get embryonated outside and infect another host
- **Clinical feature:** Heavy infection can cause tracheobronchitis and hemoptysis
- **Laboratory diagnosis:** Depends on the demonstration of eggs in the sputum. Eggs are similar to *C. philippinensis* except they are larger (59–80 µm long × 30–40 µm wide).

## TRICHOSTRONGYLUS SPECIES (PSEUDO HOOKWORM)

*Trichostrongylus* species are normally parasites of herbivorous animals (sheep, goat, camel, etc.)

### Epidemiology

Occasionally infect humans, particularly in Middle East (Iran), Asia, and North Africa. *Trichostrongylus orientalis* and *T. colubriformis* are the common species infecting man.

### Life Cycle

**Host:** It involves single host usually herbivorous animals, but rarely man.

**Mode of transmission:** Humans acquire the infection by accidentally ingesting *Trichostrongylus* L<sub>3</sub> larvae, present on the contaminated leafy vegetables.

### Development in Herbivorous Animals/Man

The larvae mature directly into adult worms in the small bowel in 3–4 weeks.

- The adult worms penetrate the intestinal mucosa and ingest blood (far less than hookworms)
- Adult worms lay eggs that are passed in the feces. In moist and warm soil, the eggs hatch out to form L<sub>1</sub> larva that molts twice to form infective L<sub>3</sub> larva.

### Clinical Features

Most infected persons are asymptomatic, but heavy infections may give rise to mild anemia and eosinophilia.

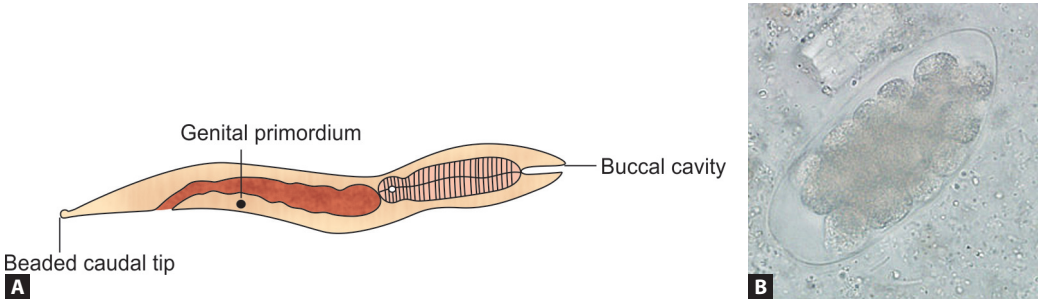
### Laboratory Diagnosis

#### Stool examination

Eggs are morphologically similar to those of hookworms but are larger. It contains segmented ovum with four or more blastomeres surrounded by an egg shell.

#### Stool Culture (Harada Mori Technique)

Eggs hatch out in the culture to form rhabditiform larva that can be differentiated from that of hookworm (Table 13.3 and Fig. 13.6).



**Figs 13.6A and B:** *Trichostrongylus* species (A) schematic diagram of rhabditiform larva; (B) egg with segmented ovum (under microscope)

Source: DPDx Image Library, Centre for Disease Control and prevention (CDC), Atlanta (with permission)

**Table 13.3:** Differences between *Trichostrongylus* species and hookworm

Features	<i>Trichostrongylus</i>	Hookworm
Mode of transmission	Ingestion of L <sub>3</sub> larva	Skin penetration by L <sub>3</sub> larva
Lung migration phase	Absent	Present
Natural host	Herbivorous animals	Humans
Eggs	Longer and thinner, Pointed at one pole 73–95 µm long x 40–50 µm wide Four blastomeres, egg shell present	Smaller Blunt poles 60 µm long x 40 µm wide Four blastomeres, egg shell present
Rhabditiform larva	No distinct buccal cavity; Tail end has a bead-like swelling or knob	Prominent buccal cavity Pointed tail end
Blood loss	Sucks less blood	Sucks more blood
Epidemiology	Middle East (Iran), Asia and North Africa	Throughout tropics and temperate regions

Treatment	<i>Trichostrongylus</i>
Patients respond well to mebendazole or albendazole.	

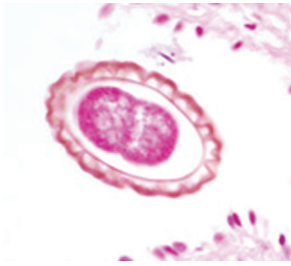
■ **DIOCTOPHYME RENALE**

*Dioctophyme renale* is commonly known as “giant kidney worm” because of its large size and ability to infect the kidneys.

- **Epidemiology:** *D. renale* is distributed commonly in the temperate region, affecting fish eating mammals. Human infection are quite rare. Only few cases are reported so far mainly from region surrounding Caspian Sea (Iran), Africa and Oceania

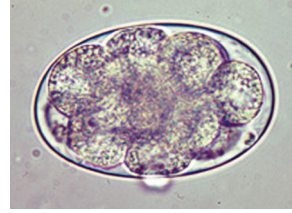- **Morphology:** Adult male worms are 20–40 cm long and 5–6 mm wide; females can grow more than 100 cm in length with a width of 10–12 mm and probably, the largest nematode infecting men.  
Eggs are oval shaped, measures 60–80 µm × 40 µm size, contain an embryo surrounded by characteristic thick sculptured egg shell (i.e. surface appears to be pitted except at the poles) (Fig. 13.7)
- **Life cycle:**  
**Host:** There are two types of hosts:
  1. **Definitive hosts:** Carnivorous mammals (mink)
  2. **Intermediate hosts:** Freshwater fishes or frogs





**Fig. 13.7:** Egg of *Dioctophyme renale*  
(hematoxylin and eosin stain)

Source: DPDx Image Library, Centre for Disease Control and prevention (CDC), Atlanta (with permission)



**Fig. 13.8:** Egg of *Oesophagostomum*  
species (under microscope)

Source: DPDx Image Library, Centre for Disease Control and prevention (CDC), Atlanta (with permission)

**Mode of transmission:** Transmission to humans occurs by ingestion of freshwater fish or frog infected with larva of *D. renale*

**Development in carnivorous animals:** Larval inside the fresh water fish or frog are ingested by carnivorous animals, penetrates the intestine and reach the kidney (right kidney affected commonly) and transform into adult worms.

Adult worms are larger in size and can block the kidney and ureter. Adult worms lay eggs that are passed in urine which further infect fresh water fishes or frog

- **Clinical features:** It include hematuria and renal colic
- **Laboratory diagnosis:** Condition is diagnosed by demonstration of characteristic eggs in urine
- **Prevention:** Proper cooking of fish prior to consumption.

### ■ OESOPHAGOSTOMUM SPECIES

- *Oesophagostomum* species is a parasite of the large intestine of ruminants, swines and monkeys in Africa, Asia and South America
- Human infection is very rare
- *O. bifurcum* is common in Africa where as *O. aculeatum* infection occurs in South-East Asia
- It belongs to the superfamily *Strongyloidea*
- **Transmission:** Ingestion of  $L_3$  larva
- The larvae develop into adult worms. Both

larvae and adult worms form nodular lesions in the intestinal wall.

- **Diagnosis:** The eggs of *O. bifurcum* are nearly identical to hookworm eggs, and therefore stool culture with identification of the larvae is needed to establish this diagnosis (Fig. 13.8).
  - ELISA to detect parasite specific IgG-4 is available and is found to be 95% specific
  - Polymerase chain reaction (PCR) have also been developed to distinguish *O. bifurcum* and hookworm.

Treatment	Oesophagostomum
Pyrantel pamoate and albendazole are affective.	

### ■ TERNIDENS DEMINUTUS

It is a small nematode belonging to super-family Strongyloidea.

- **Epidemiology:** It usually affects apes and monkeys in South Africa and Asia. Humans are also accidental hosts
- **Life cycle:**
  - Host:** There is only one definitive host (Man, cat babbon, etc)
  - Mode of transmission:** Hosts become infected by ingestion of infective filariform larvae in contaminated food.  $L_3$  larva has paired sphincter cells at esophageal-intestinal junction



**Development in definitive host:** Larvae develop into adult worms and attach to the intestinal mucosa by their mouths. Adult worms lay eggs in 30–40 days of infection. Eggs hatch out in the soil and become rhabditiform larvae and then develop into filariform larvae (infective form)

- **Clinical feature:** Asymptomatic. Rarely it can produce anemia, pseudotumors and abscesses of the bowel
- **Laboratory diagnosis:** By demonstration of eggs and adult worms in the feces. Both eggs and adult worms are morphologically similar to hookworm (hence called as **false hookworm**) except that eggs are larger in size ( $81\text{ }\mu\text{m} \times 51\text{ }\mu\text{m}$ ).

Treatment	<i>Ternidens deminutus</i>
Albendazole is found to be effective.	

## MAMMOMONOGAMUS LARYNGEUS

- It is a parasite of cattle and other ruminants
- Human infection is rare. Cases are reported mainly from Africa, Brazil and Southeast Asia
- It belongs to the family Syngamidae; hence the disease is sometime called as **syngamiasis**
- **Transmission:** By ingestion of larva (or egg containing larva)

- **Life cycle** in human is not fully understood. Probably, the larvae penetrate the intestinal wall and reach lungs via blood and then ascend to reach trachea and larynx
- **Main symptoms** are chronic cough, hemoptysis and other upper respiratory tract symptoms
- **Diagnosis:** Adult worm can be demonstrated by endoscopy. Occasionally eggs may be seen in sputum samples. Eggs are ellipsoidal, measure  $80\text{ }\mu\text{m} \times 45\text{ }\mu\text{m}$  in size.

Treatment	<i>Mammomonogamus laryngeus</i>
Albendazole is found to be effective.	

## THELAZIA SPECIES

- *Thelazia* species have been recovered from human conjunctiva. They can cause lacrimation, itching and foreign body sensation in the eye
- Human infection is caused by two species:
  1. *T. californiensis* has been reported from California
  2. *T. callipaeda* has been reported from South-East Asia
- The worms are thread like measure 1–1.5 cm long
- The  $L_3$  larvae are transmitted to man from insect (Genus *Fannia*)

## EXPECTED QUESTIONS

### I. Write Short notes on:

- (a) Cutaneous larva migrans
- (b) Visceral larva migrans
- (c) Eosinophilic meningitis
- (d) Anisakiasis
- (e) *Gnathostoma spinigerum*

### II. Differentiate between:

- (a) *Trichostrongylus* and hookworm
- (b) Eggs of *Trichuris trichiura* and *Capillaria philippinensis*

### III. Multiple choice questions (MCQs):

#### 1. Eosinophilic meningoencephalitis is caused by:

- (a) *Toxocara canis*
- (b) *Naegleria fowleri*
- (c) *Acanthamoeba*
- (d) *Angiostrongylus cantonensis*

#### 2. Oval shaped eggs with thick sculptured egg shell can be demonstrated in urine of patients infected with?

- (a) *Schistosoma mansoni*
- (b) *Dioctophyme renale*

Contd...

- (c) *Schistosoma haematobium*
- (d) *Enterobius vermicularis*

**3. True about Anisakiasis is:**

- (a) Transmitted by ingestion of larvae found in saltwater fish and squid
- (b) Transmitted by Ingestion of adult worm
- (c) Marine mammals serve as intermediate host
- (d) Transmitted by Ingestion of meat containing eggs

**4. Cutaneous larva migrans is mainly caused by:**

- (a) *Ancylostoma brasiliensis*
- (b) *Necator americanus*
- (c) *Ancylostoma duodenale*
- (d) *Strongyloides stercoralis*

**5. Visceral larva migrans is caused by:**

- (a) *Ancylostoma duodenale*
- (b) *Necator americanus*
- (c) *Ancylostoma caninum*
- (d) *Toxocara canis*

**Answers**

1. (d)    2. (b)    3. (a)    4. (a)    5. (d)

# 14 Nematodes—III (Somatic Nematodes)

## Chapter Outline

- Classification
- Filarial nematode
- Lymphatic filarial nematodes
  - *Wuchereria bancrofti*
  - *Brugia* species
- Other filarial nematodes
  - *Loa loa*
  - *Onchocerca volvulus*
  - *Mansonella* species
  - *Dirofilaria* species
- Other Somatic nematodes
  - *Dracunculus medinensis*
  - *Trichinella spiralis*
- Expected questions

## ■ CLASSIFICATION

Somatic nematodes inhabit in the extraintestinal sites. They can be grouped into filarial and non-filarial nematodes (Table 14.1).

## FILARIAL NEMATODE

## ■ GENERAL PROPERTIES

- **Habitat:** Filarial worms reside in the lymph-

**Table 14.1:** Somatic nematodes

<i>Filarial nematodes</i>	<i>Other somatic nematodes</i>
Lymphatics <ul style="list-style-type: none"><li>• <i>Wuchereria bancrofti</i></li><li>• <i>Brugia malayi</i> and <i>Brugia timori</i></li></ul>	Skin and subcutaneous tissue <ul style="list-style-type: none"><li>• <i>Dracunculus medinensis</i> (guinea worm)</li></ul> Muscle <ul style="list-style-type: none"><li>• <i>Trichinella spiralis</i></li></ul>
Skin and subcutaneous tissue <ul style="list-style-type: none"><li>• <i>Loa loa</i> (eye also)</li><li>• <i>Onchocerca volvulus</i> (eye also)</li><li>• <i>Mansonella streptocerca</i></li></ul>	Somatic animal nematodes (Described separately in chapter 13) <ul style="list-style-type: none"><li>• <i>Toxocara</i></li><li>• <i>Angiostrongylus</i></li><li>• <i>Anisakis</i></li><li>• <i>Gnathostoma</i></li></ul>
Serous cavity <ul style="list-style-type: none"><li>• <i>Mansonella ozzardi</i></li><li>• <i>Mansonella perstans</i></li></ul>	
Zoonotic filariasis: <i>Dirofilaria</i>	

hatic system, skin, subcutaneous tissue and rarely body cavity

- **Adult worm:** The adult worms are slender, round measuring 2–10 cm in length (except the female *Onchocerca* 35–50 cm). Some adult filarial worms can survive for many years in humans causing a number of chronic obstructive and inflammatory conditions including elephantiasis and hydrocele
- **Microfilariae:** The female worm produces large number of L<sub>1</sub> larvae called as **microfilariae** which are highly motile thread like larvae. They are usually non pathogenic

but sometimes, hypersensitivity reactions can occur against the microfilarial antigen resulting in tropical pulmonary eosinophilia (TPE).

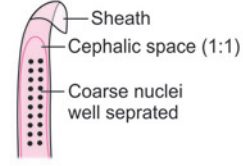
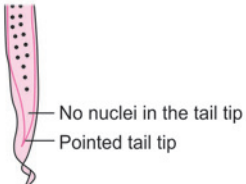
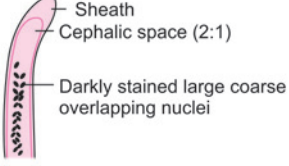
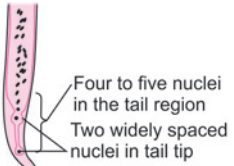
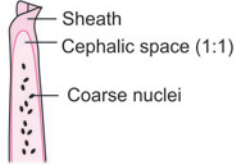
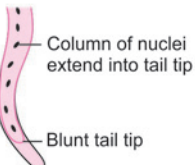
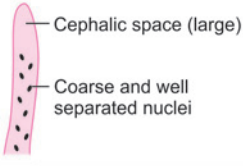
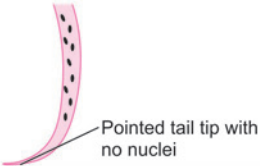
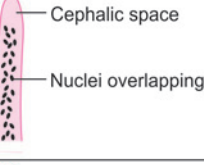
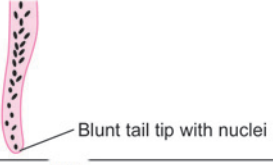
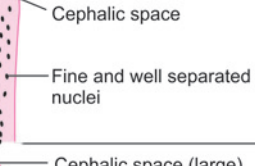
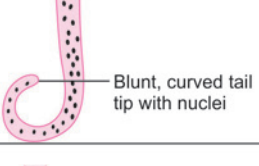
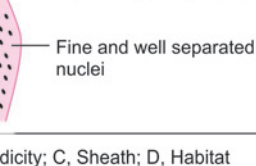

## ■ CLASSIFICATION

Filarial nematodes belong to class Secernentea, superfamily Filarioidea and family Onchocercidae. They can be differentiated by a number of properties such as (Table 14.2 and Fig. 14.1):

- **Habitat:** Whether they reside in lymphatics or subcutaneous tissues or body cavities

**Table 14.2:** Differences between various filarial nematodes

Parasite	Location of adult	Location of microfilaria	Microfilaria periodicity	Vector	Epidemiology
<b>Lymphatic filariasis</b>					
<i>Wuchereria Bancrofti</i>	Lymphatic tissue	Blood	Nocturnal (mostly)	<i>Culex</i> -Worldwide <i>Anopheles</i> in rural Africa	Cosmopolitan, (South America, Africa, South Asia)
			Subperiodic (Rare)	<i>Aedes</i>	Pacific islands
<i>Brugia malayi</i>	Lymphatic tissue	Blood	Nocturnal (mostly)	<i>Mansonia</i> <i>Anopheles</i>	South-East Asia, Indonesia and India
			Subperiodic (rare)	<i>Coquillettidia</i> and <i>Mansonia</i>	South-east Asia
<i>Brugia timori</i>	Lymphatic tissue	Blood	Nocturnal	<i>Anopheles</i>	Indonesia
<b>Subcutaneous filariasis</b>					
<i>Loa loa</i>	Subcutaneous tissue and conjunctiva	Blood	Diurnal	<i>Chrysops</i> (deerflies)	West and Central Africa
<i>Onchocerca volvulus</i>	Subcutaneous tissue	Skin and eye	None	<i>Simulium</i> (blackflies)	South and Central America and Africa
<i>Mansonella streptocerca</i>	Subcutaneous tissue	Skin	None	<i>Culicoides</i> (midges)	West and Central Africa
<b>Serous cavity</b>					
<i>Mansonella perstans</i>	Body cavities and mesentery	Blood	None	<i>Culicoides</i> (midges)	South and Central America and Africa
<i>Mansonella ozzardi</i>	Body cavities	Blood	None	<i>Culicoides</i> (midges)	South and Central America
				<i>Simulium</i> (blackflies)	Caribbean islands

Microfilaria	Head end	Tail end	Features*
<i>Wuchereria bancrofti</i>	 <p>Sheath Cephalic space (1:1) Coarse nuclei well separated</p>	 <p>No nuclei in the tail tip Pointed tail tip</p>	<p>A: 240–300 <math>\mu\text{m}</math> B: Nocturnal C: Sheathed D: Blood</p>
<i>Brugia malayi</i>	 <p>Sheath Cephalic space (2:1) Darkly stained large coarse overlapping nuclei</p>	 <p>Four to five nuclei in the tail region Two widely spaced nuclei in tail tip</p>	<p>A: 220 <math>\mu\text{m}</math> B: Nocturnal C: Sheathed D: Blood</p>
<i>Loa loa</i>	 <p>Sheath Cephalic space (1:1) Coarse nuclei</p>	 <p>Column of nuclei extend into tail tip Blunt tail tip</p>	<p>A: 250–300 <math>\mu\text{m}</math> B: Diurnal C: Sheathed D: Blood</p>
<i>Onchocerca volvulus</i>	 <p>Cephalic space (large) Coarse and well separated nuclei</p>	 <p>Pointed tail tip with no nuclei</p>	<p>A: 200–360 <math>\mu\text{m}</math> B: Non periodic C: Unsheathed D: Skin, eye</p>
<i>Mansonella perstans</i>	 <p>Cephalic space Nuclei overlapping</p>	 <p>Blunt tail tip with nuclei</p>	<p>A: 190–200 <math>\mu\text{m}</math> B: Non periodic C: Unsheathed D: Blood</p>
<i>Mansonella streptocerca</i>	 <p>Cephalic space Fine and well separated nuclei</p>	 <p>Blunt, curved tail tip with nuclei</p>	<p>A: 180–240 <math>\mu\text{m}</math> B: Non periodic C: Unsheathed D: Skin</p>
<i>Mansonella ozzardi</i>	 <p>Cephalic space (large) Fine and well separated nuclei</p>	 <p>Hooked and pointed tail tip with no nuclei</p>	<p>A: 200–230 <math>\mu\text{m}</math> B: Non periodic C: Unsheathed D: Blood</p>

\*A, Size; B, Periodicity; C, Sheath; D, Habitat

**Fig. 14.1:** Comparison of microfilariae of various filarial worms

- Geographical distribution
- Vector responsible for transmission
- Structure of their larvae (microfilariae) (Fig. 14.1) such as presence of sheath and nuclei at the tail tip
- **Microfilarial periodicity:** It is defined as the time when most of the microfilariae are found in the peripheral blood
  - Microfilariae of various filarial worms exhibit different periodicity and are found in the peripheral blood in different time of the day such as:

- **Nocturnal periodicity** (night time, between 9 pm and 2 am): e.g. *Wuchereria* and *Brugia*
- **Diurnal periodicity** (day time): e.g. *Loa loa*
- **Sub-periodic** (present throughout; with slight increase in the afternoon): Rarely *Wuchereria* and *Brugia* can be sub-periodic
- **Non periodic** (Any time): e.g. *Mansonella* and *Onchocerca*

- Periodicity occurs due to biological and evolutionary co-adaptation of the microfilariae to the feeding habit of the mosquito (*Culex* bites in night, *Aedes*-bites in daytime)
- However, other factors like sleeping pattern of the individual, temperature and other climatic conditions also contribute
- When not in peripheral blood, the microfilariae are found in the pulmonary blood vessels.

## LYMPHATIC FILARIAL NEMATODES

Lymphatic filariasis is caused by *Wuchereria bancrofti*, *Brugia malayi* and *B. timori*.

### ■ WUCHERERIA BANCROFTI

#### History

The existence of lymphatic filariasis has been recorded in ancient Indian, Chinese,

Persian and Egyptian writings. Indian physician Sushruta was the first to describe elephantiasis.

- Microfilaria of *W. bancrofti* was first discovered by Demarquay (1863) in hydrocele fluid from a patient in Cuba
- Wucherer (1868) had detected the microfilaria in urine and Lewis (1872) in blood
- Bancroft was the first to describe the female worm in 1877, followed by the discovery of adult male by Bourne (1888)
- Manson (1899) had described the periodicity of the microfilaria and the role of insect vector.

#### Epidemiology

##### World

- *W. bancrofti*, is the most widely distributed filarial parasite of humans
- Approximately two billion people residing in 80 countries are at risk; while an estimate of nearly 110 million people are infected
- It is found throughout the tropics and subtropics with highest prevalence in Asia (India-5%, China) and Sub-Saharan Africa (8%) and other places like Pacific Islands, areas of South America, and the Caribbean basin
- In general, *W. bancrofti* is nocturnally periodic, except in Pacific Islands; where it is sub-periodic.

##### India

- It is estimated that about 600 million people are at risk, residing in 250 districts of 20 states in India
- Highly endemic states are Uttar Pradesh, Bihar, Jharkhand, Odisha, Andhra Pradesh, Tamil Nadu, Kerala and Gujarat
- Prevalence is low in North-eastern states, Jammu and Kashmir and the Punjab
- Sub-periodic *W. bancrofti* (transmitted by *Aedes*) has been reported from Nicobar Island.



## Morphology

### Adult Worm

Adult worms are located in the lymphatic vessels and lymphnodes.

- They are long, slender, creamy white thread like filariform shaped with tapering ends
- Adult males ( $4\text{ cm} \times 0.1\text{ mm}$ ) are smaller than females ( $6\text{--}10\text{ cm} \times 0.2\text{--}0.3\text{ mm}$ ) (Fig. 14.2)
- Male worms can be differentiated from female worms by their small size, cork-screw like tail and presence of two spicules (helps in copulation) at posterior end
- Both adult male and female remain coiled together
- Females are **viviparous** and they directly discharge larvae without any eggs.

### Larva

Like other nematodes, there are four larval stages. The first stage larva is called as **microfilaria**. The third stage larva is called as **filariform larva**; which is the infective form to humans.

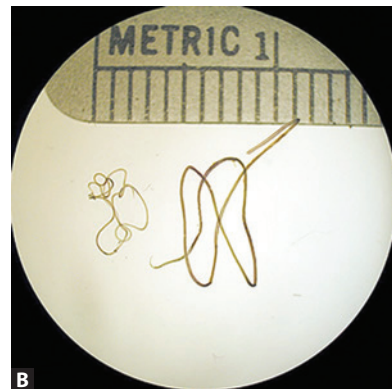
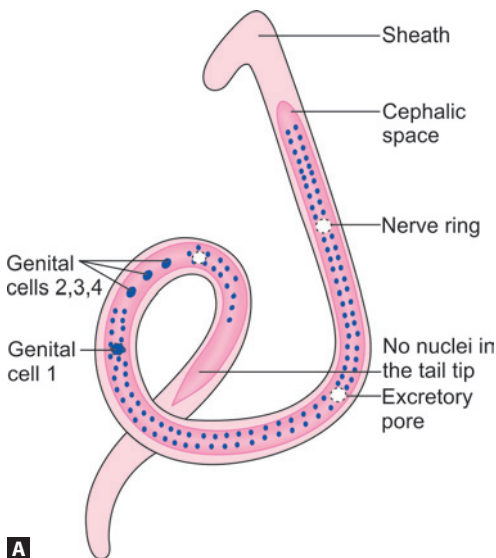
### Microfilaria

Microfilariae are the diagnostic forms, found in the blood vessels (Fig. 14.2).

- It measures  $240\text{--}300\text{ }\mu\text{m} \times 7.5\text{--}10\text{ }\mu\text{m}$  covered by a long hyaline sheath ( $360\text{ }\mu\text{m}$ ) within which it moves
- The head end is blunt while the tail end is pointed
- In unstained film, microfilariae are transparent and colorless. But when stained with Giemsa or other Romanowsky stains they look pink with a column of violet nuclei
- The nuclei are present throughout the body except near the head and the tail end. Nuclei are also absent in few places which represent various primordial organs like nerve ring, excretory pore, anal pore and genital cells
- Based on the structure of microfilaria, different filarial nematodes can be differentiated (Fig. 14.1).

### Cultivation

Limited success has been achieved to cultivate the filarial worms.



**Figs 14.2A and B:** *Wuchereria bancrofti* (A) microfilaria (schematic diagram); (B) microscopic view of adult worm male (left) and female (right)

Source: DPDx Image Library, Centre for Disease Control and prevention (CDC), Atlanta (with permission)

**Cell line:** *W. bancrofti* and *B. malayi* can be cultivated in mosquito cell line (like *Aedes togoi* and *Anopheles maculatus*) grown in modified RPMI-1640 medium or medium-TC199 supplemented with 20% newborn calf serum and LLC-MK2 cells. Human embryonic kidney cell line is also used as a feeder layer

- Microfilariae ex-sheath and molt twice to L<sub>3</sub> stage larvae in 12–16 days
- However, culture methods are not employed in diagnosis. They are used for the maintenance of the parasite for:
  - Preparation of antigen for immunological tests
  - Antifilarial drug susceptibility testing
  - Research purpose

**Laboratory animals:** African green leaf monkeys (*Presbytis melalophos*) are highly

susceptible to subcutaneous inoculation of L<sub>3</sub> larva that transform to microfilaria in 4–6 weeks.

### Life Cycle (Fig. 14.3)

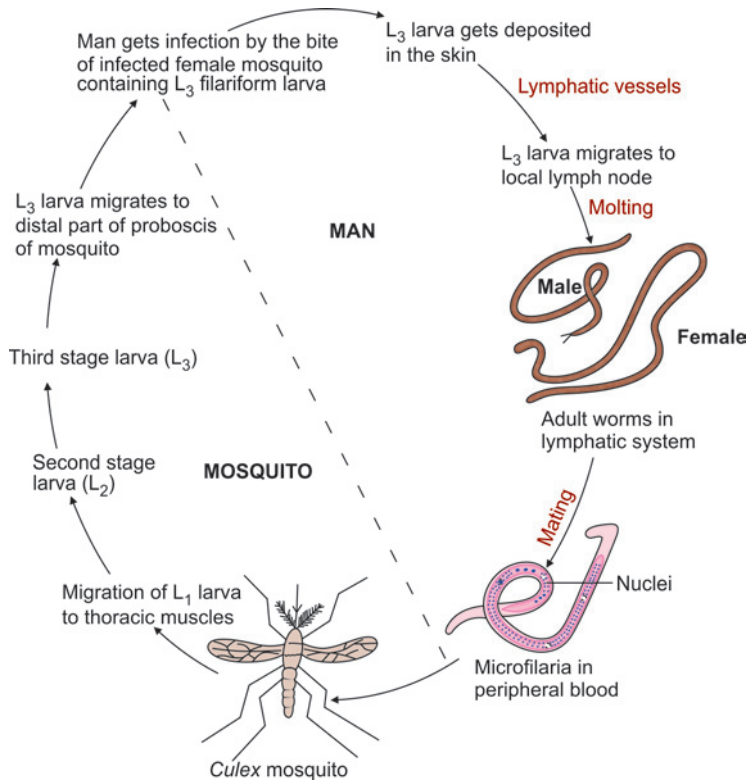
**Host:** *W. bancrofti* completes its life cycle in two hosts.

**1. Definitive host:** Man

**2. Intermediate host:** Mosquito named *Culex quinquefasciatus* is the principle vector worldwide. Rarely *Anopheles* (rural Africa) or *Aedes* (Pacific Island) can serve as a vector.

**Infective form:** Third stage filariform larvae are the infective form found in the proboscis of the mosquito.

**Mode of transmission:** L<sub>3</sub> filariform larvae get deposited in skin by the insect bite. Residents



**Fig. 14.3:** Life cycle of *Wuchereria bancrofti*

living in the endemic areas are exposed to about 50–300 L<sub>3</sub> larvae every year.

### Human Cycle

- **Develop into adults:** Larvae penetrate the skin, enter into lymphatic vessels and migrate to the local lymph nodes where they molt twice to develop into adult worms in few months (4–6 weeks for *B. malayi*)
- **Adults lay L<sub>1</sub> larvae (microfilariae):** Adult worms reside in the afferent lymphatics or cortical sinuses of the lymph nodes where they mate and start laying the first stage larvae (microfilariae). Male worms die after mating where as the female worms live for 5–10 years. A gravid female can discharge 50,000 microfilariae/day
- **Prepatent period:** It is the time period between the infection (entry of L<sub>3</sub> larvae) and diagnosis (detection of microfilariae in blood). This is variable ranging from 80 days to 150 days.

### Mosquito Cycle

- **Transmission:** When the mosquito bites an infected man, the microfilariae are ingested. *Culex* bites in night where as *Aedes* bites in daytime
- **Exsheathing:** Microfilariae come out of the sheath within 1–2 hours of ingestion
- **Migration to thoracic muscle:** L<sub>1</sub> larvae penetrate the stomach wall and migrate to thoracic muscle in 6–12 hours where they become sausage shaped (short and thick)
- **Develop to infective L<sub>3</sub> larvae:** L<sub>1</sub> larvae molt twice to develop L<sub>2</sub> (long and thick form) followed by L<sub>3</sub> (long and thin form). The highly active L<sub>3</sub> larvae migrate to the labella (distal part of proboscis) of the mosquito and serve as the infective stage to man
- **Extrinsic incubation period:** Under optimum conditions, the mosquito cycle takes around 10–14 days.

### Pathogenesis and Pathology

The pathologic changes occur as a result of inflammatory damage to the lymphatics which in turn is due to summation of many effects such as:

- Tissue alterations related to migration of live adult worms such as lymphatic dilatation and thickening of the vessel walls
- Tissue alterations related to antigen and toxic metabolites released from dead adult worm
- Secondary bacterial and fungal infections
- Host's inflammatory response to both live and dead parasite
  - Infiltration of plasma cells, eosinophils, and macrophages in the infected vessels, along with endothelial and connective tissue proliferation
  - This leads to tortuosity of the lymphatics and damage to lymph valves resulting in lymph edema of limbs and brawny edema on the overlying skin
- As long as the worm remains viable, the lymphatic vessels though damaged, still remains patent
- However, the death of the worm leads to enhanced granulomatous reaction, thrombi formation and fibrosis of the lymph vessels with extensive perilymphangitis
- This results in severe lymphatic obstruction. The lymphatic function is severely compromised
- **Endosymbiosis:** Pathogenic *W. bancrofti* is found to be infected with a *Rickettsia* group of bacteria called *Wolbachia* and maintain an endosymbiotic relationship. It is proved that this symbiosis is essential for the parasite survival, fertility and larval development.

### Host Immune Response

Both cellular and humoral immune response are altered. Antigens of both adult worms and microfilariae are processed by the

antigen presenting cells (macrophages) and presented to T helper cells. T helper cells are stimulated and differentiated into T helper 1 cells and or T helper 2 cells.

### **In Early Infection (Amicrofilaremic Individuals)**

- There is activation of parasite specific delayed type of hypersensitivity response
- Parasite specific Th cell proliferation occurs and both T helper 1 cells and T helper 2 cells are stimulated
- This leads to a mixed cytokine response. Both Th1 cytokines such as interleukin-2 (IL-2) and interferon- $\gamma$  (IFN- $\gamma$ ) and T helper 2 cells cytokines (IL-4 and IL-5) are elevated
- There is profound eosinophilia and higher titers of immunoglobulin (IgE) antibody level.

### **Microfilaraemic Individuals (Asymptomatic and Acute Stage)**

- Diminished parasite specific T cell proliferation occurs
- Predominant T helper 2 cells response is seen that leads to:
  - Elevation of IL-4, IL-5 and IL-13 and IL-10
  - Low production of IFN- $\gamma$  and IL-2
- Profound eosinophilia
- Increase parasite specific IgG-4 antibodies
- **Hyper IgE levels:** Total IgE level is maximum in acute filariasis where as the parasite specific IgE level is maximum in asymptomatic microfilaraemic individuals and in occult filariasis, suggestive of the protective role of parasite specific IgE in containing the disease.

### **In Chronic Filariasis**

- There is increase production of T helper 2 cells induced cytokines like IL-4, IL-5 and IL-13
- Elevation of parasite specific IgG-1, IgG-2 and IgG-3.

## **Clinical Features**

Incubation period is about 8–16 months. Clinical manifestations can be categorized into:

1. Lymphatic filariasis
2. Tropical pulmonary eosinophilia (TPE)/ (Occult filariasis)
3. Immune complexes mediated manifestations.

### **Lymphatic Filariasis**

#### **Endemic normal**

These are the normal people residing in endemic area. Their prevalence ranges from 0 to 50%. They are not infected by the parasite. This might be due to:

- Insufficient exposure
- Immunological resistance
- Prepatent period at the time of study.

#### **Asymptomatic microfilaraemia**

In endemic area, many infected individuals don't exhibit any symptoms of filarial infection.

- These people have a down regulated T helper 1 cells response (low IFN- $\gamma$ ) and elevated T helper 2 cells response ( $\uparrow$ IL-4)
- However, it is observed that most of the asymptomatic people have some degree evidence of subclinical infection like:
  - Microfilaremia demonstrated in their peripheral blood
  - Microscopic hematuria and/or proteinuria
  - Dilated and tortuous lymphatics (visualized by imaging)
  - Filarial dance sign (ultrasound showing motile adult worm in scrotal lymphatics).

#### **Acute filariasis (acute adenolymphangitis)**

It is characterized by recurrent episodes of:

- Filarial fever (high-grade fever)
- Lymphatic inflammation (lymphangitis and lymphadenitis):
  - Common lymph nodes enlarged are inguinal, axillary and epitrochlear nodes

- In addition, lymphatics of the male genital organs are frequently involved that leads to funiculitis, epididymitis and orchitis

- **Transient local edema:** Early pitting edema; reversible on limb elevation
- **Dermatolymphangitis:** Plaque like lesion is formed over the affected skin with fever, chill and lymphatic inflammation
- In Brugian filariasis, the episodes are more frequent and abrupt in onset.

### **Chronic filariasis**

It develops 10–15 years after infection.

- Chronic host immune response against the dead worm leads to enhanced granuloma, thrombi formation and fibrosis of the lymph vessels leading to severe lymphatic obstruction and pedal edema
- **Grading of edema:** Early pitting edema (grade-1) becomes nonpitting and irreversible on limb elevation (grade-2) followed by brawny edema with thickening of the skin (grade-3), finally lead to fibrosis and fissuring (grade-4)
- The manifestations in descending order of occurrence are (Fig. 14.4):
  - **Hydrocele** (most common manifestation): Accumulation of fluid in the cavity of tunica vaginalis of testes
  - Elephantiasis (swelling of lower limb

or less commonly arm, vulva or breast)

- Chronic funiculitis and epididymitis
- Chyluria excretion of chyle, a milky white fluid in urine. This occurs rarely.

### **Occult Filariasis or**

### **Tropical Pulmonary Eosinophilia (TPE)**

Also called as **Weingarten's syndrome**: It is a distinct syndrome that develops in some infected individuals of endemic places.

### **Pathogenesis**

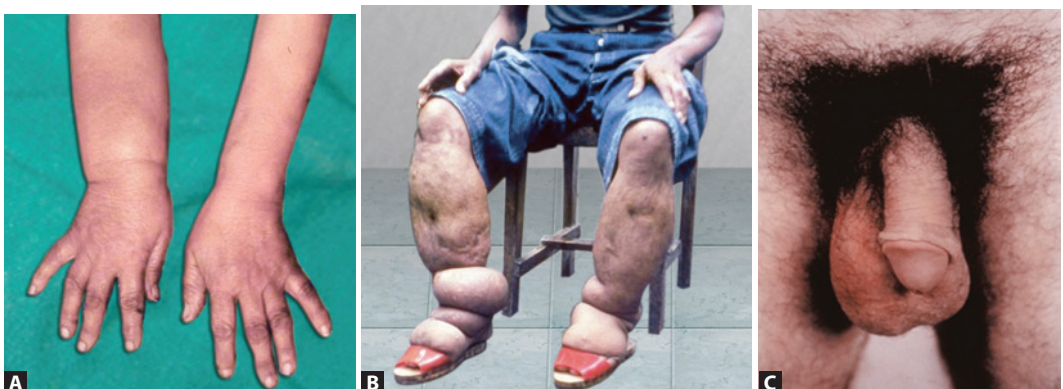It represents a hypersensitivity reaction to microfilaria antigen. Microfilariae are rapidly cleared from the blood stream and filtered, lodged and destroyed in lungs initiating an allergic response. Hence, microfilariae are not detected in peripheral blood.

### **Epidemiology**

The majority of cases have been reported from India, Pakistan, Sri Lanka, Brazil, Guyana, and Southeast Asia. Males are affected more than females (4:1), mainly in the third decade of life.

### **Clinical features**

Common features include nocturnal paroxysmal cough and wheezing (due to nocturnal periodicity of microfilariae), weight loss, low-grade fever (Table 14.3).



**Fig. 14.4:** Clinical features of filariasis (real images) (A) lymphoedema; (B) elephantiasis; (C) hydrocele of scrotum  
Source: B- ID#-373; C- ID# 354, Public Health Image Library, Centre for Disease Control and prevention (CDC), Atlanta (with permission)



**Table 14.3:** Differences between classical filariasis and occult filariasis

Characters	Classical filariasis	Occult filariasis
Causative Agent	Inflammatory changes to adult worm	Hypersensitivity reaction to microfilaria antigen
Diagnostic form	Microfilaria in blood and in fluid	Microfilaria absent in blood
Organs affected	Lymph nodes and lymphatic vessels	Lungs, liver and spleen
Pathology	Lymphangitis and lymphadenitis	Eosinophilic granuloma
Serology	Antibody not diagnostic	Antibody [Immunoglobulin E (IgE)]—diagnostic

Occasionally, microfilariae are entrapped in other organs like spleen, liver and lymph-node leading to hepatosplenomegaly and lymphadenopathy. This is sometimes called as **Meyers Kouwenaar Syndrome**.

### Laboratory Diagnosis

- Blood eosinophilia (absolute eosinophil count more than 3000/ $\mu$ L)
- Chest X-ray: Shows diffuse infiltration
- Elevated serum IgE levels
- Pulmonary function test shows obstructive changes in lungs.

### Treatment

It responds well to Diethylcarbamazine (DEC), 4–6 mg/kg for 14 days. Relapse may occur in 12–25% of cases.

### Immunocomplexes Mediated Manifestations

Circulating immunocomplexes containing microfilarial antigens are found to be deposited in various organs such as:

- Kidney (causes nephrotic syndrome hematuria and proteinuria)
- Joints (causes filarial arthritis of knee or ankle).

**Laboratory Diagnosis** Wuchereria bancrofti

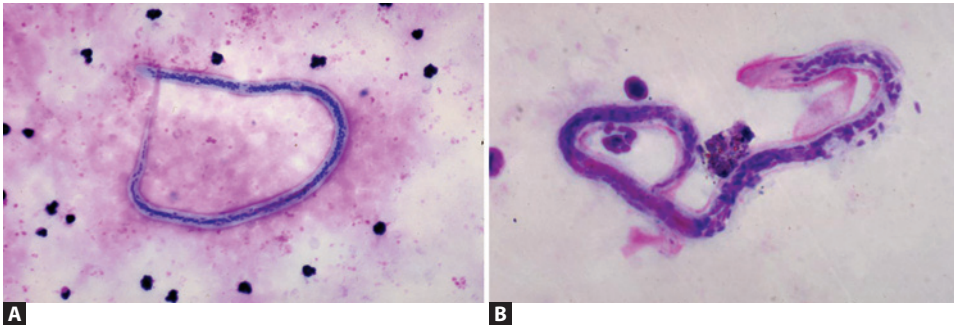
- Demonstration of microfilariae
- Antigen detection—ELISA, ICT
- Antibody detection—IHA, IFA, ELISA
- Imaging methods—USG, X-ray
- Molecular methods—PCR, PCR-RFLP
- Xenodiagnosis
- Other methods—eosinophil count, cellular assay, etc

### Laboratory Diagnosis

#### Microscopy (To Detect Microfilariae)

- **Sample:** Microfilariae can be found in blood, and occasionally in hydrocele fluid, urine or other body fluids
- **Direct wet mount:** Demonstrates serpentine movement of microfilariae
- **Thick smear stained** with Leishman's, Giemsa or hematoxylin and eosin stain can be performed to observe the sheath and nuclei of microfilaria. (Fig. 14.5)
- **Concentration techniques:** Blood can be examined after concentration techniques to increase sensitivity (detail is given in Chapter 15)
  - Membrane filtration technique
  - Knott's centrifugation technique
- **Collection time:** It is critical and should be based on the periodicity of the microfilariae. For nocturnal periodicity, blood should be collected between 9 pm and 2 am.
- **DEC provocation test:** This test is done to collect the blood in the day time
  - Patient takes a tablet of DEC orally (2mg/kg) so that the nocturnal microfilariae are stimulated and come to peripheral blood within 30 minutes
  - This test is contraindicated in *Onchocerca* and *Loa loa* infection
- **QBC (Quantitative buffy coat examination):** This test is commonly performed for malaria diagnosis, however it can also be used to detect microfilariae. It involves centrifugation of blood, staining with acridine orange stain and examined under fluorescent microscope. This technique is more sensitive than smear microscopy





**Figs 14.5A and B:** Thick blood smears stained with Giemsa showing microfilaria of (A) *Wuchereria bancrofti*; (B) *Brugia* species  
 Source: A- ID# 3009/, B- ID# 3003, Dr. Mae Melvin, Public Health Image Library, Centre for Disease Control and prevention (CDC), Atlanta,

- Microfilariae may not be found in blood because of many reasons such as:
  - Occult filariasis
  - Chronic filariasis and endemic normal people
  - Wrong time of blood collection.

### Antigen Detection

Circulating antigens of *W. bancrofti* can be detected by using monoclonal antibodies against Og4C3 and AD12 antigens.

- Both enzyme-linked immunosorbent assay (ELISA) and rapid immunochromatographic test (ICT) are commercially available
- ELISA is 100% sensitive and 99–100% specific, whereas ICT is 96–100% sensitive and 95–100% specific
- No antigen detection methods are available for *Brugia* infection
- Advantages of antigen detection:
  - More sensitive than microscopy
  - Can be detected in day time
  - Can differentiate the current and past infection. Antigen disappears after clinical cure
  - Can be detected in urine.

### Antibody Detection

#### Older methods

Earlier, crude parasitic extract was used to

detect serum antibodies. Various formats are used like indirect hemagglutination (IHA), indirect fluorescent antibody test (IFA) and ELISA. They are useful for Seroepidemiological purpose. These tests suffered a lot of criticism because:

- **Low specificity:** Due to cross reactivity with other parasites
- **Cannot differentiate the current from the past infection:** Antibodies persist even after clinical cure

#### Newer approach

- Improvements have been made by detecting specific IgG-4 antibodies against recombinant *W. bancrofti* antigens.
- They show less cross reactivity and correlate well with intensity, duration of filarial exposure and level of microfilaremia
- Anti-sheath antibodies are raised even before microfilariae appear in the blood
- Can also be used to diagnose *Brugia* infection.

### Imaging Methods

#### Ultrasound

High-frequency ultrasound with doppler techniques are employed to detect:

- Anatomical abnormalities of lymphatics, dilated and tortuous vessels
- **Filarial dance sign:** Serpentine movement of adult worms within the lymphatic vessels of scrotum—positive in 80% of cases.

### Lymphoscintigraphy

Lymphoscintigraphy of the limbs reliably demonstrates the functional abnormalities of lymphatics (like flow abnormalities) even in asymptomatic microfilaremic persons.

### X-Rays

It can detect:

- Dead and calcified worms
- Pulmonary infiltrates in patients with TPE.

### Molecular Methods

- Polymerase chain reaction (PCR) based assays have been developed to detect DNA of *W. bancrofti* and *B. malayi* in blood. PCR is highly sensitive and can detect as little as one microfilaria per/mL of blood
- PCR-RFLP based assay using ITS 1- rRNA gene as primer can differentiate all the species of human and animal filarial parasites.

### Xenodiagnosis

Mosquitoes are allowed to feed on the infected patients and are dissected 4–6 weeks later to demonstrate microfilariae. This may be helpful in detecting low density microfilaremia.

### Other Methods

- Eosinophilia (absolute eosinophil count > 3000/ $\mu$ L)
- Elevated serum concentrations of immunoglobulin (IgE) (> 1000 ng/mL)
- **Cellular assays:** Filarial skin test and lymphocyte response to filarial antigen, both are less specific
- Biopsy of enlarged lymph node to demonstrate adult worm.

Treatment	Wuchereria bancrofti
<b>Diethylcarbamazine (DEC)</b>	
<ul style="list-style-type: none"> <li>• It is the drug of choice for the treatment of filariasis</li> <li>• It is given 6 mg/kg daily for 12 days</li> </ul>	

Treatment	Wuchereria bancrofti
<ul style="list-style-type: none"> <li>• Can kill both adult worms and microfilariae. However, adults are cleared slowly</li> <li>• In India, DEC is administered in three ways:                             <ol style="list-style-type: none"> <li>1. <b>Mass therapy:</b> It is given as 6 mg/kg single dose of DEC to everyone in endemic area irrespective of symptoms and microfilaremia except children less than 2 years, pregnant women and severely ill patients</li> <li>2. Selective treatment for the diseased and asymptomatic microfilaremic persons</li> <li>3. DEC medicated salt</li> </ol> </li> </ul> <p><b>Albendazole:</b> 400 mg twice daily for 21 days) has also demonstrated efficacy against adult worms and microfilariae</p> <p><b>Ivermectin:</b> 400/kg single dose can kill the microfilariae but has no effect on adult worms. High rate of recurrence occurs, hence not used in India (used only in Africa)</p> <p><b>Doxycycline:</b> It is given to target the intracellular <i>Wolbachia</i>. It also shows significant microfilaricidal activity as DEC</p>	

### Prevention

#### Mass Chemoprophylaxis

Global Programme to eliminate **lymphatic filariasis** (launched by WHO, 1997) had aimed at administrating:

- Single annual doses of DEC plus albendazole. In India and other non-African endemic area
- Albendazole plus ivermectin in Africa.

### Vector Control

#### Antilarval measures

Antilarval measures are highly expensive hence mainly restricted to urban areas. Chemicals can be used like:

- Mosquito larvicidal oil
- Pyrethrum based oil (pyrosene oil-E)
- Organo-phosphorus larvicides like fenthion, temephos.

#### Antiadult measures

Antiadult measures like pyrethrum spray

can be used. However, DDT and hexachloro-cyclohexane (HCH) are not effective.  
Personal care by using mosquito net.

**Filariasis Control Programme**

The National Filariasis Control Programme has been in operation since 1955. It is now merged with National vector borne disease control programme.

**Elimination of lymphatic filariasis by 2015:** Launched in India in 2002, by National Health Policy.

- **Target:** Lymphatic filariasis ceases to be a public health problem when the number of microfilaria carriers will be < 1% and children will be free from circulating antigens.
- **Strategies** employed are—(1) Annual mass administration of DEC or DEC + Albendazole (2) Home based management for lymphedema cases and up scaling of hydrocele operations.

■ **BRUGIA MALAYI**

**History**

- Microfilariae were described first by Lichtenstein in blood films from natives in Indonesia
- Brug had described it as a new species (1927)

- Rao and Maplestone (India) were the first to describe the adult worm (1940).

**Epidemiology**

There is considerable overlapping in the geographical distribution of brugian filariasis and bancroftian filariasis.

- *B. malayi* occurs primarily in eastern India, Indonesia, Malaysia and Philippines
- It also shows two types of periodicity of microfilaremia

The nocturnal form is more common, transmitted in areas of coastal rice fields, while the sub-periodic form is rare, found in the forests of Malaysia and Indonesia

- In India, the major states involved are Kerala, Odisha, Assam and West Bengal.

**Morphology**

The adult worms are essentially similar to that of *W. bancrofti* except they are smaller in size; males (3.5 cm × 0.1 mm) and females (5–6 cm × 0.1 mm).

Microfilariae measure 175–230 µm × 5–6 µm in size. Like that of *W. bancrofti*, the microfilaria of *B. malayi* is also sheathed with some minor differences (Table 14.4).

**Life Cycle**

The life cycle is similar to *W. bancrofti* except:

- **Vector:** *Mansonia* (*M. annulifera* and

**Table 14.4:** Microfilariae of *Wuchereria bancrofti* and *Brugia malayi*

Microfilariae	<i>Wuchereria bancrofti</i>	<i>Brugia malayi</i>
Appearance	Graceful and sweeping curves	Crinkled with secondary curves
Size	240–300 µm long	Smaller and average 220 µm long
Cephalic space	Length to width ratio is 1:1	Longer (length to width ratio is 2:1)
Excretory pore	Not prominent	Prominent
Nuclei column	Large, coarse and well separated	Darkly stained, large, coarse, overlapping and extended till the tail tip
Tail	<ul style="list-style-type: none"><li>• Pointed tail tip</li><li>• No nuclei in the tail region</li></ul>	<ul style="list-style-type: none"><li>• Pointed tail tip</li><li>• Four to five nuclei are present in the tail region</li><li>• Two widely spaced nuclei at the tail tip—terminal and sub terminal</li></ul>

*M. uniformis*) is the main vector for the nocturnal strains, *Anopheles* and *Aedes* also can transmit the infection.

The sub-periodic strains are transmitted by *Coquillettidia* and *Mansonia*

- **Reservoir:** Humans are the main reservoir; except for the sub-periodic strains of *B. malayi* where monkeys, cats and dogs are the animal reservoirs.
- **Shorter pre-patent period:** 3–4 months.
- **Shorter life cycle in mosquito** (external incubation period).

### Clinical Features

Both lymphatic filariasis and tropical pulmonary eosinophilia syndrome are observed in brugian filariasis. Clinical features are similar to bancroftian filariasis except:

- More frequent episodes of acute adenolymphangitis and filarial abscesses
- Chronic manifestations (lymphedema and elephantiasis) occur less frequently
- The genital involvement is not seen
- Elephantiasis: Swelling is limited to leg below the knee
- Chyluria is not marked.

### Laboratory Diagnosis

As in bancroftian filariasis, the diagnosis of brugian filariasis depends on:

- **Microscopy:** To detect microfilaria in blood by staining methods like Giemsa stain (Table 14.4, Fig.14.5B)
- **Antibody detection methods:** Both ELISA and ICT formats are available detecting IgG-4 antibodies against recombinant BmR1 antigen of *B. malayi*. It shows good sensitivity and specificity
- However, there is no antigen detection method available
- Imaging methods like ultrasound can be employed
- **Molecular methods:** PCR can differentiate between *B. malayi* and *W. bancrofti*.

### Treatment

Same as for bancroftian filariasis.

### Prevention

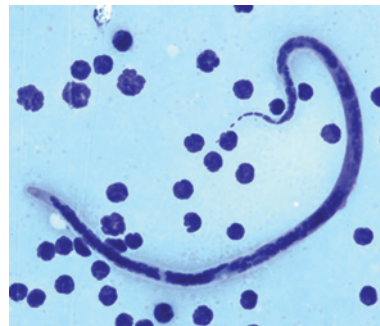
Same as for bancroftian filariasis (i.e both chemoprophylaxis and vector control).

**Removal of pistia plants:** In South India and Srilanka where the *Mansonia* is the main vector, breeding is best controlled by removing the supporting plant *Pistia stratiotes* from all water collections and converting ponds to fish or lotus cultures. Herbicidal agents like phenoxyline 30 and shell weed killer-D may be used to destroy the plants.

## ■ BRUGIA TIMORI

*B. timori* was first detected by David and Edeson on 1965.

- Its distribution is limited to the Timor islands of southeastern Indonesia
- Morphologically microfilariae are similar to that of *B. malayi* except (Fig. 14.6):
  - **Longer:** Measures 265–325  $\mu\text{m}$  (average 310  $\mu\text{m}$  long)
  - Cephalic space—length to width ratio is 3:1
  - 5–8 nuclei are present in the tail region (with two nuclei in tail tip)
  - Sheath doesn't stain with Giemsa stain



**Fig. 14.6:** Microfilariae of *Brugia timori* (stained with Giemsa)

Source: DPDx Image Library, Centre for Disease Control and prevention (CDC), Atlanta (with permission)

- Transmitted by *Anopheles barbirostris*
- Clinical feature, lab diagnosis, treatment are similar to that of *B. malayi*.

## OTHER FILARIAL NEMATODES

### LOA LOA

#### History

*Loa loa* (also called as African eye worm) was first reported in West Indies in 1770.

Later in 1895, Argyll-Robertson described the adult worm from the subcutaneous swelling of the eye of a woman residing in Calabar from West Africa. Hence, this condition is named as **Calabar swelling**.

#### Epidemiology

*Loa loa* is restricted to the rain forests of West and Central Africa.

Approximately, 13 million people are infected.

#### Morphology

Adult worms (females, 50–70 mm long and 0.5 mm wide; males, 30–35 mm long and 0.3

mm wide) live in subcutaneous tissues.

Microfilariae circulate in the blood with a diurnal periodicity that peaks between 12:00 noon and 2:00 p.m. They are sheathed, measure 250–300  $\mu\text{m}$  long and bear a column of nuclei extending till the tail tip (Figs 14.1 and 14.7).

#### Life Cycle

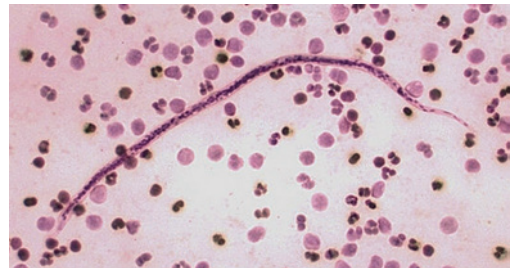
Life cycle is similar to that of *W. bancrofti* except the vector is female *Chrysops* species (deerflies, mango flies, red flies or tabanid flies)

- **Mode of Transmission** Infective ( $L_3$ ) larvae are transmitted by the bite of female *Chrysops* species during the blood meals in the daytime
- Larvae transform into adult worms over 6–12 months and migrate in subcutaneous tissues and eyes. Microfilariae released from gravid female worms migrate to the blood and exhibit a diurnal periodicity
- Microfilariae are ingested by the deerflies during the blood meal, loose sheath, penetrate the gut wall, then migrate to fat body and molt twice to become the infective  $L_3$  larvae in about 10–12 days of time.

## Pathogenesis and Clinical Feature

### Calabar Swellings

This is the most common form of loiasis, also called as **fugitive swelling**.



**Fig. 14.7:** *Loa loa* microfilaria (under microscope)

Source: Public Health Image Library, ID# 914/  
Dr. Lee Moore, Centre for Disease Control and  
prevention (CDC), Atlanta (with permission)

#### Zoonotic *Brugia* Infection

- There are few other species of *Brugia* that can be transmitted from lower animals to man such as:
  - *B. beaveri* (transmitted from raccoon)
  - *B. leporis* (transmitted from swamp rabbit)
- Around 50 cases are reported so far, mainly from USA
- **Clinical features:** Usually systemic manifestations are not seen. Most of the patients present with a tender mass in the cervical, axillary or inguinal region
- ***Brugia pahangi*:** It is a common parasite of dogs and cats in Malaysia. It has been reported to cause lymphangitis and lymphadenitis in men
- Apart from this, even sub periodic strains of *B. malayi* can also be transmitted to man from monkeys, cats and dogs in Malaysia and Indonesia.



- It is a subcutaneous swelling developing on the extremities (knee or wrist) and less frequently at other sites
- Swelling develops rapidly in few hours, preceded by localized pain, pruritus and urticaria and last for 3–4 days
- It occurs due to host inflammatory response to the migrating adult worm (at a speed of 1cm/minute) or its metabolic products. Microfilariae are not pathogenic.

### Ocular Manifestations

It includes conjunctival granuloma, edema of eye lid leading to proptosis (bulging).

### Complications

Nephropathy, encephalopathy and cardiomyopathy can occur but are rare.

#### Native vs travelers to the endemic zone

Manifestations are more severe and frequent in the visitors going to the endemic areas of Africa. Eosinophilia and increased levels of antifilarial antibodies are characteristic. However, microfilaremia is less common

The native people of endemic areas are often asymptomatic with microfilaremia (90%) or may show episodic Calabar swellings (10%), moderate eosinophilia and variable levels of antibodies.

#### Laboratory Diagnosis

Loa loa

- Microscopy—to detect microfilariae in blood and adult worm from eye/subcutaneous tissue
- Molecular methods—nested PCR
- Antibody detection
- Other methods—hypergammaglobulinemia, elevated serum IgE, elevated eosinophil count, etc

### Laboratory Diagnosis

#### Microscopy

Definite diagnosis of loiasis requires:

- Detection of microfilariae in the peripheral blood (Fig. 14.1 and 14.7)

- Isolation of the adult worm from the eye or biopsy of subcutaneous swelling
- However, the microfilariae usually appear in blood after few years of infection and travelers are often negative for microfilaremia.

### Molecular Methods

Nested PCR-based assays for the detection of *L. loa* DNA in blood are available in specialized laboratories and are highly sensitive (95%) and specific.

### Antibody Detection

It is done by using recombinant antigen.

### Other Methods

Other clinical findings in the travelers include:

- Hypergammaglobulinemia
- Elevated levels of serum IgE
- Elevated leukocyte and eosinophil counts
- Characteristic history and clinical presentation.

#### Treatment

Loa loa

- **Diethylcarbamazine (DEC)** is the drug of choice—multiple courses are necessary to resolve loiasis completely
  - **Dose:** DEC is given in a dose of 8–10 mg/kg per day for 21 days
  - It is effective against both the adult and the microfilarial forms of *L. loa*
- **Glucocorticoids:** It is required in heavy microfilaremia, to reduce the allergic or other inflammatory reactions against microfilariae
- **Albendazole or ivermectin** is effective in reducing microfilarial loads, but ivermectin is contraindicated in heavily infected patients with loiasis
- **Surgical removal** of the adult worms is rarely required if they migrate through the bridge of the nose or through the conjunctiva

## ONCHOCERCA VOLVULUS

*Onchocerca volvulus* is the causative agent of “river blindness” in man. *O. gutturosa* is



a cattle parasite, rarely infects man causing skin nodules.

### History

O'Neill was the first to describe about the microfilaria in 1875; Leuckart in 1893 described the adult worm from skin nodules in Africa. Robies (1917) from Guatemala had suggested the role of the vector—Black flies for transmission.

### Epidemiology

Worldwide, about 37 million individuals from 35 countries are infected.

**Endemic area:** The majority of individuals infected with *O. volvulus* live in the rural poor region of Sub Saharan Africa, particularly West Africa. The infection is also found in Yemen and in part of central and South America.

### Morphology

#### Adult Worm

The adult worms are long thin, tapering at both the ends.

- **Cuticle:** They bear transverse striations on the cuticle with annular and oblique thickening. This helps in differentiating from other filarial worms
- Female worms are longer (35–50 cm × 400 µm) than males (2–4 cm × 0.2 cm). The female worms of *O. volvulus* are much longer than any other filarial worms (2–10 cm)
- Adult worms are mainly found coiled within the subcutaneous nodules.

#### Microfilaria

They are usually found in skin dermis (90%) or rarely in the subcutaneous nodules, blood, sputum or urine.

- They measure 200–360 µm long, pointed tail tip without any nuclei (Fig. 14.1)
- They are unsheathed, non periodic.

### Life Cycle

Life cycle is similar to that of *W. bancrofti* except the vector *Simulium* (black flies).

- **Mode of Transmission:** Infective form (i.e L<sub>3</sub>/filariform larva) is transmitted by *Simulium* (blackflies or buffalo gnats) flies during the blood meals
- Within the dermis, the L<sub>3</sub> larvae molt twice to transform to adult worms over 12 months and migrate in subcutaneous tissues and eyes. Microfilariae are released from gravid female worms within 15 months after infection (pre-patent period)
- Microfilariae are ingested by the black flies during the blood meal, penetrate the gut wall, migrate to the flight muscles and molt twice to become the infective larvae (L<sub>3</sub>) in about 6–12 days of time (extrinsic incubation period).

### Clinical Features

Patients are asymptomatic when the worm load is less. However, in heavy infections the major manifestations include skin (dermatitis), subcutaneous fibrous nodule (onchocercoma), lymphadenitis and ocular changes. Except for the skin nodules (occurs due to adult worms), the other manifestations are due to hyper reactive immune response to the microfilarial antigens.

#### Skin (Dermatitis)

Intense pruritus and generalized papular rashes are the most common manifestations.

- Prolonged infection results in loss of elastic fibers and epidermal atrophy which can lead to loose, redundant wrinkling of skin
- **Leopard skin:** Skin may be hypo to hyper-pigmented. The spots of repigmentation within a depigmented area are known as **leopard skin**
- Lichenoid changes and hyperkeratosis may occur in late stages
- **Sowda:** It is a chronic hyper reactive form of dermatitis, results from formation of auto

antibodies against defensins. It occurs in a subset of individuals from Arabica, Sudan, Guatemala and West Africa.

### **Onchocerca (Subcutaneous Nodules)**

Subcutaneous nodules are firm, non tender, variable in size containing the coiled adult worms and rarely microfilariae.

In African patients, nodules are common over the trunk (sacrum and hip area), while in patients from South and Central America, they tend to develop on the head, neck and shoulders.

### **Ocular Involvement**

Bilateral blindness (river blindness) is the most serious complication of onchocerciasis. Lesions may develop in all parts of the eye.

- **Conjunctivitis with photophobia:** It is the most common early finding
- **Punctate keratitis:** It is a self resolving, acute inflammatory reactions to surrounding dying microfilariae seen in younger patients and presented as “**snowflake opacities**”
- **Sclerosing keratitis** occurs in 1–5% of infected persons and is the leading cause of **Onchocercal blindness** in Africa
- **Other manifestations:** Anterior uveitis and iridocyclitis (Africa), retinal pigmentation, secondary glaucoma (seen in Latin America).

### **Lymph Nodes**

Lymphadenopathy in the inguinal and femoral areas is commonly noted.

The enlarged nodes may hang down (“**hanging groin**”) and may predispose to hernia.

### **Host Immune Response**

The asymptomatic microfilaremic people residing in endemic area have a suppressed cellular immune response to the parasitic antigens.

However, symptomatic patients especially with Sowda have a marked (T helper) Th2

response and increase in interleukin-4 (IL-4) and IL-5 that leads to increase in the levels of IgE, IgG4 and eosinophilia.

#### **Laboratory Diagnosis**

*Onchocerca*  
volvulus

- Detection of microfilariae—skin snip technique
- Detection of adult worm—biopsy of subcutaneous nodule
- Serology—IgG-4 specific dip stick assay
- Molecular method—PCR
- Mazzoti skin test (DEC patch test)
- Eosinophilia and elevated serum IgE

### **Laboratory Diagnosis**

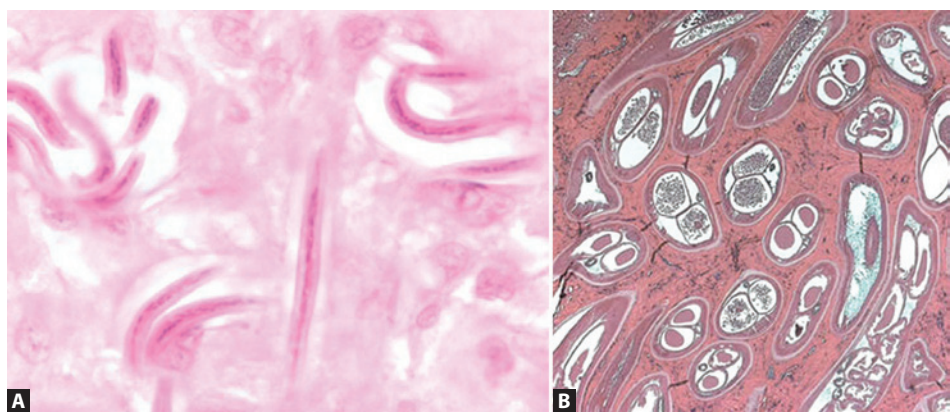
#### **Detection of the Microfilariae**

Detection of microfilariae in a skin snip smear is the gold standard method for diagnosis of onchocerciasis. Microfilariae are found either in the skin (90%) or in nodules (10%).

- **Skin snips technique:**
  - **Most common sites:** Both iliac crests or sometimes from calves and the shoulders
  - **Procedure:** Skin is lifted by a needle and a small piece (1 to 3 mm) is excised with a sterile scalpel blade
- After incubating the biopsy tissue in saline, microfilariae emerge from the skin (60% within 30 minutes, 75% in 24 hours)
- The movement can be seen by direct microscopy. However, differentiation from other microfilariae can be done following Giemsa or hematoxylin and eosin (H & E) staining (Figs 14.1 and 14.8)
- Quantification of microfilariae can be done (number of microfilariae per mg of skin) which is an accurate tool to measure the endemicity of infection in the community.

#### **Detection of the Adult Worm**

It can be done from the biopsy of the subcutaneous nodules but it is less sensitive.



**Figs 14.8A and B:** *Onchocerca volvulus* from a skin nodule stained with hematoxylin and eosin stain (H & E) (A) microfilariae; (B) adult worms—transverse section  
Source: DPDx Image Library, Centre for Disease Control and prevention (CDC), Atlanta (with permission)

**Serology**

Cocktail of recombinant antigens of *O. volvulus* can be used to detect specific antibodies which show better specificity and don't cross react with other nematodes.

However, it cannot differentiate the current from the past infection.

But currently developed IgG4 specific dip stick assay can detect the active infection. There is no licensed antigen detection method available.

**Molecular Methods**

PCR detecting onchocercal DNA in skin snips or even from skin scrapings is available in specialized laboratories and is highly sensitive and specific. It can differentiate the *Onchocerca* species and also the various strains of *O. volvulus*.

**Other Methods**

Eosinophilia and elevated serum IgE

**Mazzotti Skin Test (DEC Patch Test)**

Topical application of DEC on the skin leads to local reaction (erythema and itching) to the dead worm. Sometime, the reaction is

much severe in heavy infection. Hence this is done only in light infection without eye involvement.

Treatment	Onchocerca volvulus
Ivermectin is the drug of choice for onchocerciasis.	
• It is active against the microfilariae but not against the adult worms	
• It is given orally in a single dose of 150 µg/kg, either yearly or semiannually	
• It is contraindicated in areas of Africa co-endemic for <i>O. volvulus</i> and <i>L. loa</i> .	
Surgical excision is recommended when nodules are located on the head	

**Prevention**

Vector control is useful in highly endemic areas. Insecticide spraying can be carried to destroy the breeding sites.

Mass administration of ivermectin every 6–12 months is being used to interrupt the transmission in endemic areas.

**MANSONELLA SPECIES**

They are named after Patric Manson. They rarely infect humans and are either non

pathogenic or asymptomatic in most of the individuals.

### ■ MANSONELLA PERSTANS

- **Epidemiology:** It is found mainly in the center of Africa and in North-Eastern South America
- **Transmission:** It is transmitted by *Culicoides* (midges)
- **Life cycle:** It is similar to other filarial worms. Adult worms reside in serous cavities, mesentery and perirenal tissues. Microfilariae circulate in the blood without periodicity
- **Clinical features:** Usually nonpathogenic, but occasionally it can cause manifestations like angioedema, urticaria, and pruritus
- **Laboratory diagnosis:** Microfilariae in peripheral blood are non-periodic, non-sheathed, measures 190–200  $\mu\text{m}$  long with a straight tail with blunt end. Body nuclei are extended till the tail tip (Figs 14.1 and 14.9A).

Treatment	Mansonella perstans
DEC or albendazole are found to be effective lowering the level of microfilaremia.	

### ■ MANSONELLA STREPTOCERCA

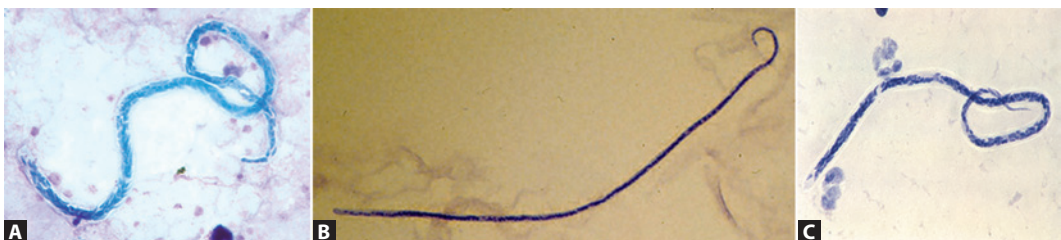
- **Epidemiology:** *M. streptocerca* is found mainly in the tropical forest of Africa such as Ghana, Nigeria, Zaire and Uganda

- **Transmission:** It is transmitted by the biting midges (*Culicoides granhami*)
- **Life cycle** is similar to other filarial worms
- **Clinical feature:** Many infected individuals are asymptomatic, although some people develop inguinal lymphadenopathy and a chronic dermatitis with pruritus
- **Laboratory diagnosis:** The diagnosis is made by detection of the characteristic microfilariae in skin snips. It is non periodic, non-sheathed, measures 180–240  $\mu\text{m}$  with a curved tail (looks like **shepherd's crook**). Nuclei are extended till the blunt tail tip. (Figs 4.1 and 14.9B).

Treatment	Mansonella streptocerca
DEC is effective for streptocerciasis.	

### ■ MANSONELLA OZZARDI

- **Epidemiology and transmission:**
  - *M. ozzardi* is found mainly in Central and South America and transmitted by *Culicoides* (midges)
  - Rarely, it is also found in certain Caribbean islands and transmitted by *Simulium amazonicum* (blackflies)
- **Life cycle:** It is similar to other filarial worms. Adult worms are rarely recovered from humans. Microfilariae circulate in the blood without periodicity
- **Clinical features:** Most infections are asymptomatic, but occasionally cause lymphadenopathy, urticaria, pruritus,



**Fig. 14.9:** (A) Microfilariae of *Mansonella perstans* (stained with Giemsa); (B) microfilaria of *Mansonella streptocerca* (stained with hematoxylin and eosin); (C) *Mansonella ozzardi* microfilaria (Giemsa stain)  
Source: A and B- DPDx Image Library, Centre for Disease Control and prevention (CDC), Atlanta (with permission); C- Public Health Image Library, ID# 909/ Centre for Disease Control and prevention (CDC), Atlanta (with permission)

pulmonary symptoms, arthralgia and keratitis

- **Diagnosis:** Microfilariae can be detected in peripheral blood; which are non-periodic, non-sheathed, measures 200–230 µm long with a fine attenuated hooked and pointed tail tip without any nuclei (Figs 14.1 and 14.9C).

Treatment	Mansonella ozzardi
Ivermectin is effective in lowering the level of microfilaraemia. Use of DEC is controversial.	

### ■ DIROFILARIA SPECIES

*Dirofilaria* species are parasites of lower animals. Humans are unusual hosts. Hence the parasite undergoes an incomplete development in humans either in the lungs, eyes and or subcutaneous tissue

- **Transmission:** Man acquires infection by the bite of mosquito containing L3 filariform larvae. Larvae undergo only partial development and immature adults are lodged in subcutaneous tissue from which they may migrate to other organs
- **Various species** are:
  - Infection with *D. repens* (from dogs) or *D. tenuis* (from raccoons) or *D. ursi* (bears) can cause local subcutaneous nodules in humans
  - *D. immitis* (dog heart worms) can cause pulmonary infection in humans
  - *D. conjunctivae* can cause ocular manifestations in sclera and conjunctiva
- **Epidemiology:** Less than 1,000 cases are reported so far, mainly from the USA, Africa, Southeast Asia and Mediterranean countries
- **Diagnosis:** By identification of the adult worms by surgery or autopsy. Microfilariae are not found in blood or tissue.

Treatment	Dirofilaria
Surgical removal of the worm is the only treatment available. No drugs are found to be effective.	

## OTHER SOMATIC NEMATODES

### ■ DRACUNCULUS MEDINENSIS

*Dracunculus medinensis* causes **Guinea worm disease** or **dracunculiasis**.

#### Epidemiology

- The incidence has been reduced from southern Asia due to proper global eradication programme. Asia has now been deemed as dracunculiasis free
- It is eliminated from India (and also from Pakistan)
- Currently, dracunculiasis is limited to few countries in Sub-Saharan Africa such as Sudan (the highest burden), Ghana, Mali, and Niger.

#### Life Cycle (Fig. 14.10)

**Host:** There are two types of hosts:

1. **Definitive host:** Man

2. **Intermediate host:** Copepods (*Cyclops*)

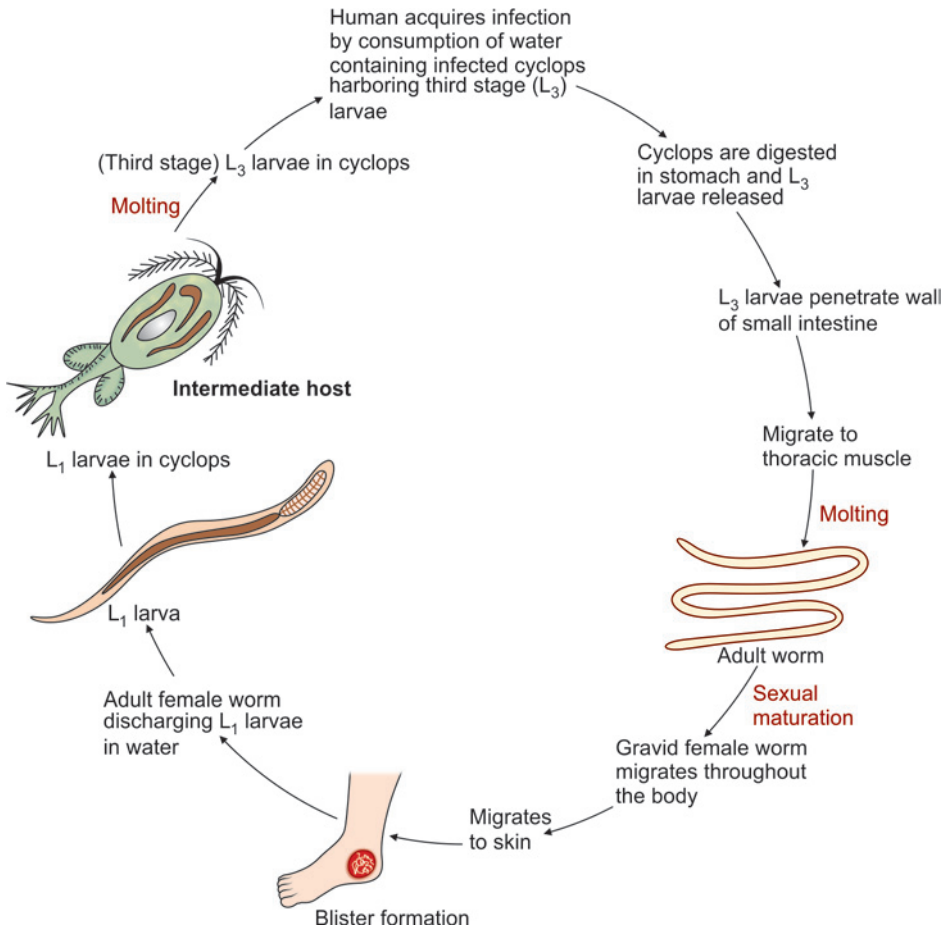
**Infective form:** Third stage filariform larvae.

**Mode of transmission:** Man gets infection by drinking fresh water from stagnant pools containing minute fresh water crustaceans (*Cyclops*) infected with L<sub>3</sub> larvae.

#### Development in Man

- **Migration to thoracic muscle:** Cyclops are digested in stomach releasing the L<sub>3</sub> larvae. They penetrate the wall of the small intestine and migrate through the thoracic musculature. Larvae molt twice to form adult worms which later sexually mature
- Gravid female worms mature over 10 to 14 months, migrate throughout the body, and ultimately reach the skin, particularly over the ankles, feet, and lower legs
- When skin comes in contact with water, the female worm (1 meter long) induces a local blister that eventually ruptures. Large numbers of L<sub>1</sub> larvae are released into the water when prolapsed loops of the uterus of female worm contracts.





**Fig. 14.10:** Life cycle of *Dracunculus medinensis*

### Development in Cyclops

The motile free-swimming  $L_1$  larvae infect *Cyclops*. They molt twice to form  $L_3$  larvae which are infective to man over a period of 2 weeks.

### Pathogenesis and Clinical Feature

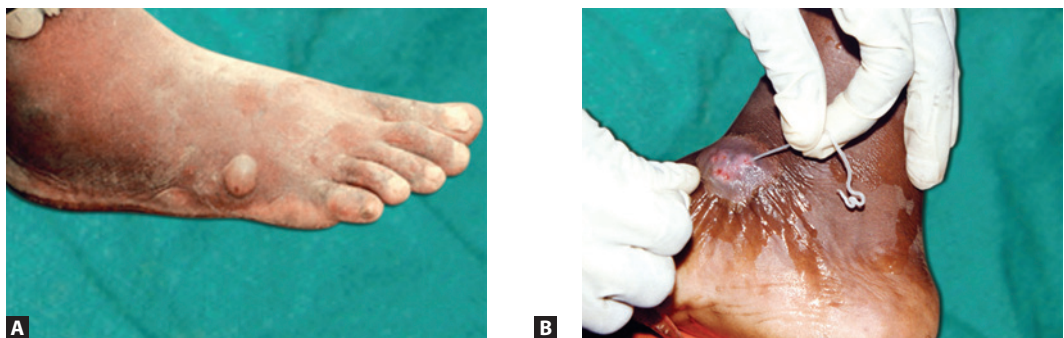
Signs and symptoms appear approximately 1 year after the infection; when gravid adult female worm emerges near the surface of the skin.

- The initial presentation is a painful papule that enlarges over hours to days to form

a blister from which the worm emerges. (Fig. 14.11)

- The blister may be accompanied by local erythema, urticaria, fever, nausea and pruritus. The entire worm may emerge over a period of several weeks
- Complications include secondary bacterial infections that may lead to sepsis, local abscesses and pyogenic arthritis
- The most common site—lower leg, ankle and foot
- The prevalence of dracunculiasis is a strong indicator of poor socioeconomic development of the community such as inadequate





**Figs 14.11A and B:** Real image of (A) blister formed in dracunculiasis; (B) *Dracunculus medinensis* (adult female worm) emerging from the blister  
Source: DPDx Image Library, Centre for Disease Control and prevention (CDC), Atlanta (with permission)

treatment of drinking water and improper separation of bathing and drinking facilities

- The manifestations are seasonal (June to September); due to appearance of stagnant water pools (containing *Cyclops*).

**Laboratory Diagnosis**

Dracunculus medinensis

- Detection of adultworm (from blister)
- Detection of L<sub>1</sub> larvae
- Antibody detection—ELISA
- Peripheral blood Eosinophilia.

**Laboratory Diagnosis**

Dracunculiasis is diagnosed by:

- **Detection of adult worm:** This is possible when the gravid female worms appear in the blisters. The calcified adult worms from the deeper tissue can be detected by X- ray
- **Detection of L<sub>1</sub> larvae:** On contact with cold water placed on the leg ulcer, a large number of motile larvae are discharged which can be examined under microscope
- **Antibody detection:** Antibodies to *D. medinensis* can be detected by ELISA.
- Peripheral blood *Eosinophilia*.

Treatment	Dracunculus medinensis
	<ul style="list-style-type: none"><li>• <b>Worm removal:</b> Worms are slowly and gently extracted over a period of 15–20 days using a small stick and wounding out daily with small traction. Heavy pressure should be avoided because breaking the worm can lead to allergic reactions and secondary bacterial infection</li><li>• There are no anti-helminthic drugs known to be effective against <i>D. medinensis</i></li><li>• <b>Symptomatic treatment:</b> Includes application of wet compresses to the affected skin, administration of analgesics and prevention of secondary bacterial infection by the use of topical antibiotics</li></ul>

**Reasons for Eradication of Guinea Worm Disease from India**

The national Guinea worm eradication programme was launched in 1984 with technical assistance from World Health Organization (WHO).

Simple and cost-effective measures were taken to eradicate the disease such as:

- **Provision of safe drinking water:** Filtration of drinking water, installing hand pumps and pipes

- **Cyclops control:** Killing copepods in sources of drinking water by application of abate (temephos) larvicide
- Provision of clean drinking water from bore-holes or wells
- Health education of people in matter related to boiling or filtering of drinking water
- Treatment of cases.

## ■ TRICHINELLA SPIRALIS

*Trichinella spiralis* causes **trichinellosis** (or trichinosis) which is a zoonotic infection acquired from domestic pigs or other carnivores.

### History

*T. spiralis* was first detected by James Paget and Richard Owen (1835) from a cadaver muscle. Later on, in 1859 Virchow had described the lifecycle.

### Classification

*Trichinella* belongs to the class Adenophorea, superfamily Trichinelloidea and family Trichinellidae.

- DNA analysis had shown that it comprises of at least 11 species. *T. spiralis* is the predominant species distributed Worldwide affecting humans
- Other species infect usually animals, some of them rarely infect humans: *T. pseudospiralis*, *T. native*, *T. nelsoni*, *T. britovi*, *T. murrelli*, *T. papuae*, *T. zimbabwensis*.

### Epidemiology

Human trichinellosis is widely prevalent in the pork eating countries (more in temperate zone than tropics) like Europe, South America and North America including the USA. More so, meats of horses and wild boars have also been implicated to cause disease.

### In India

Few cases of animal trichinellosis has been reported. Human infection is very rare. The first case was reported from the Punjab. In

2010, an outbreak of human trichinellosis had occurred in Uttarakhand affecting 18 people eating roasted wild bear meat called **kachmoli**.

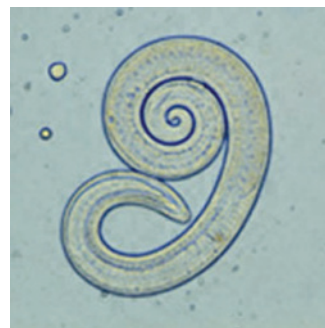### Morphology

#### Adult Worm

- **Size:** It is one of the smallest intestinal nematode. Female worm (3 mm long) is longer than male worm (1.5 mm long)
- **Shape:** Thread like just visible to naked eye
- Esophagus occupies one-third to half of the body and bears a row of esophageal glands (stichocytes). Esophagus leads to intestine and ending at anus
- **Male worm:** Identified by presence of pair of copulatory organs (papillae) at the tail end called as **claspers**, but there is no copulatory bursa
- **Female worm:** Females have single ovary, uterus, vagina and vulva opened in the middle. They are viviparous, i.e they directly lay larvae; there is no egg stage.

#### Larva

- There are four larval stages ( $L_1$ - $L_4$ )
- The newborn larva ( $L_1$ ) measures 80  $\mu$ m long, its esophagus has a stylet (a sphere like organ helps in entering into the cells)
- The infective  $L_1$  larva in muscle measures 1 mm long. Inside the muscle cyst, the larva remains coiled; hence, the species name is given as "*spiralis*" (Fig. 14.12).



**Fig. 14.12:** Larvae of *Trichinella* liberated from bear meat (microscopic view)

**Life Cycle (Fig. 14.13)****Host:**

- Pig is the **optimum host** and is the principal reservoir of infection
- Animals like rats horses or other carnivores can also serve as the host
- Transmission usually occurs in nature from one flesh eating animal to other. Common cycles are pig to pig, rat to rat, pig to rat
- Man is an **accidental host** and acts as dead end

**Infective form:** First stage ( $L_1$ ) larvae.

**Mode of transmission:** By ingestion of raw or uncooked pork or other animal meat containing  $L_1$  larvae.

**Intestinal Phase**

- **$L_1$  larvae transform to adults:** Ingested  $L_1$  larvae are immediately freed from the animal flesh by digestive enzymes in stomach. Then, they are carried to the small intestine (upper two third). They penetrate the intestinal mucosa where they undergo

four molts to develop into adult worms in 2–3 days

- **Female worms lay  $L_1$  larvae:** Male worms mate with females and die soon. Females are viviparous. After 5 days of fertilization, they start laying the first stage larvae.

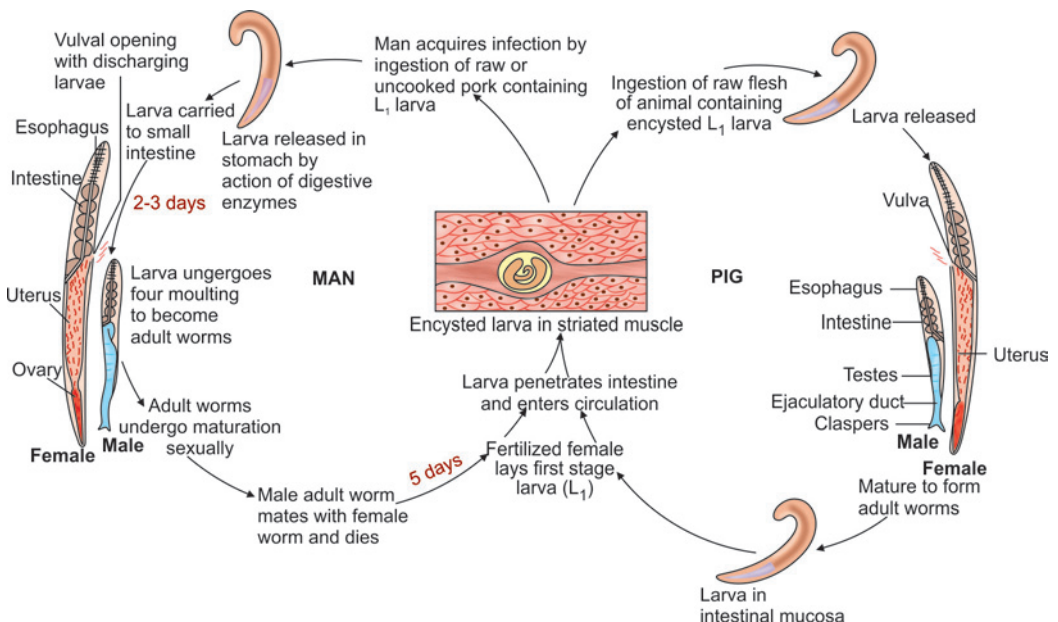
**Migration Phase**

The  $L_1$  larvae penetrate the intestine and carried to skeletal muscle via lymphatic and venous circulation.

**Encystment**

$L_1$  larvae enter inside the skeletal muscle cells and behave as obligate intracellular anaerobic parasite.

- The secretion of esophageal glands modulates the host DNA to alter the hostile environment
- The muscle cells are modified within 20 days; to form **nurse cells**, surrounded by blood vessels which provide the required environment for the containment of the parasite for years.



**Fig. 14.13:** Life cycle of *Trichinella spiralis*

Only skeletal muscle cells are infected, encystment doesn't occur in cardiac and smooth muscles.

### Organization

After some years, the nurse cell-larva complex undergoes changes such as fibrosis and degeneration and calcification.

### Pathogenicity and Clinical Feature

Clinical symptoms of trichinellosis depend on the phase of parasitic invasion—enteric invasion, larval migration, and muscle encystment.

#### Enteric Stage

- Most of the light infections are asymptomatic; however, heavy infections can be life-threatening. Symptoms start appearing during the first week of infection
- Invasion of the gut by large number of parasites can provoke watery diarrhea (most common feature) during the first week after infection
- Abdominal pain, constipation, nausea or vomiting may also be seen.

#### Stage of Larval Migration (Parenteral Stage)

- Symptoms appear in the second week after infection
- Hypersensitivity reaction: The migrating *Trichinella* larvae provoke a marked local and systemic hypersensitivity reaction, with fever and hypereosinophilia
- Periorbital and facial edema is common
- Hemorrhages are seen in the sub-conjunctiva, retina and nail beds ("splinter" hemorrhages)
- Maculopapular rash
- Migration to heart, CNS and lungs is common—leading to myocarditis, encephalitis, or pneumonia that become severe after 4–8 weeks. Myocarditis is transient as the larvae don't encapsulate in cardiac muscle.

### Stage of Muscle Encystment

- Occurs 2–3 weeks after infection
- Common symptoms are myositis with myalgia, muscle edema, and weakness
- **Most commonly involved muscles:** extra-ocular muscles followed by biceps; and muscles of the jaw, neck, lower back, and diaphragm
- *T. pseudospiralis* infection is rare and its larvae do not encapsulate in muscles. It causes prolonged polymyositis like illness.

#### Laboratory Diagnosis

*Trichinella spiralis*

- Demonstration of larvae in muscle biopsies—By direct slide technique and H and E stain
- Serology (antibody detection)—ELISA, CIEP
- Bachman intradermal test
- Animal inoculation in rats
- Other method—blood eosinophilia, elevated WBC count, elevated muscle enzyme, etc

### Laboratory Diagnosis

#### Demonstration of Larvae

**Definite diagnosis** by demonstration of larvae in muscle biopsy:

- **Sample:** Muscle biopsy near tendon insertions of deltoid (at least 1g) gives better yield
- **Direct slide technique:** The fresh muscle tissue should be compressed between glass slides and examined microscopically
- **Histopathologic study:** Can be done using H & E stain but larvae may be missed by examination of routine histopathologic sections alone (Fig. 14.14)
- **Enzymatic digestion** of muscle mass by trypsin and mounting the digested tissue may yield better result.

#### Serology

- Parasite specific antibody can be detected by ELISA or countercurrent immunoelectrophoresis (CIEP)
- Positive after 2 weeks of infection
- It confirms the diagnosis but cannot differentiate past and present infection.

**Bachman Intradermal Test**

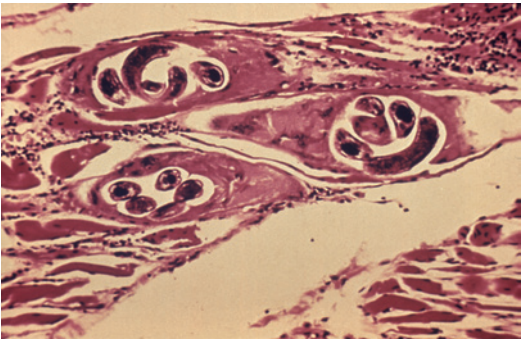
Intradermal injection of Bachman antigen (prepared from *Trichinella* larva obtained from rabbit muscle) causes an immediate small induration surrounded by erythema of 5 cm diameter in 15–20 minutes. It becomes positive in 2–3 weeks of infection and persists for life, hence cannot differentiate past infection present infection.

**Animal inoculation**

Rats are fed with muscle tissue of suspected patients and after appropriate time, they are examined for *T. spiralis* larvae in the diaphragm.

**Other Tests**

- **Blood Eosinophilia:** Elevated in more than 90% symptomatic patients and levels may peak at 2–5 weeks after the infection and remains elevated for 4–8 weeks.
- **Increase in white blood cells (WBC) count**
- **Elevated muscle enzymes:** Elevated serum creatine phosphokinase
- History of consumption of pork or wild animal meat
- **X-ray** to detect the calcified muscle cyst.



**Fig. 14.14:** *Trichinella* cysts within human muscle tissue (hemotoxylin and eosin stain)  
Source: Public Health Image Library, ID# 5234/ Centre for Disease Control and prevention (CDC), Atlanta (with permission)

Treatment	Trichinella spiralis
<ul style="list-style-type: none"><li>• <b>Mild infection:</b> Symptomatic treatment is required with bed rest, antipyretics, and analgesics</li><li>• <b>Moderate infection:</b> Mebendazole and albendazole are active against enteric stages of the parasite, but their efficacy against encysted larvae has not been conclusively demonstrated</li><li>• <b>Severe infection:</b> Glucocorticoid is added which is beneficial for severe myositis and myocarditis</li></ul>	

EXPECTED QUESTIONS

**I. Write essay on:**

(a) Describe the life cycle, pathogenesis and laboratory diagnosis of bancroftian filariasis?

(b) Classify somatic nematodes? Describe the life cycle, pathogenesis and laboratory diagnosis of *Brugia malayi*?

**II. Write short notes on:**

(a) Onchocerciasis

b) Loiasis (c) Guinea worm infection

**III. Differentiate between:**

(a) Microfilaria of *Wuchereria bancrofti* and *Brugia malayi*

(b) Classical filariasis and occult filariasis

**IV. Multiple choice questions (MCQs):**

**1. Causative agent of Calabar swelling is:**

(a) *Dracunculus medinensis*

(b) *Wuchereria bancrofti*

(c) *Brugia malayi* (d) *Loa loa*

**2. Which of the following infection is eradicated from India?**

(a) *Wuchereria bancrofti*

(b) *Brugia malayi*

(c) *Dracunculus medinensis*

(d) *Ascaris lumbricoides*

**3. Which of the following microfilariae is sheathed?**

Contd...

Contd...

- (a) *Mansonella perstans*
  - (b) *Onchocerca volvulus*
  - (c) *Brugia malayi*
  - (d) *Mansonella streptocerca*
4. **Microfilaria of *Brugia malayi* differs from that of *Wuchereria bancrofti* by all except:**
- (a) Coarse, overlapping and darkly stained nuclei
  - (b) Tail-tip free from nuclei
  - (c) Possesses secondary kinks
  - (d) Cephalic space longer
5. **Which of the following microfilaria comes to peripheral blood in the day time?**
- (a) *Wuchereria bancrofti*
  - (b) *Brugia malayi*
  - (c) *Loa loa*
  - (d) *Brugia timori*

**Answer**

1. (d)    2. (c)    3. (c)    4. (b)    5. (c)





# Section 4

---

## Miscellaneous

**Chapter 15** Laboratory Diagnosis of Parasitic Diseases

**Chapter 16** Medical Entomology



# 15 Laboratory Diagnosis of Parasitic Diseases

## Chapter Outline

- Introduction
- Morphological identification techniques
- Culture techniques in parasitology
- Immunodiagnostic methods
- Molecular methods
- Intradermal skin tests
- Xenodiagnostic techniques
- Animal inoculation methods
- Imaging techniques
- Expected questions

## INTRODUCTION

Laboratory diagnosis plays a vital role in the diagnosis of parasitic infections. Following diagnostic techniques are used for diagnosis of parasitic infections:

- Morphological identification techniques either macroscopically or microscopically
- Culture methods
- Immunodiagnostic methods
- Molecular methods
- Intradermal skin tests
- Xenodiagnostic techniques
- Animal inoculation methods
- Imaging techniques.

## MORPHOLOGICAL IDENTIFICATION TECHNIQUES

The parasites can be identified by their morphology either macroscopically or microscopically. Various morphological forms of different parasites can be seen in different specimens (Table 15.1).

Microscopically they can be visualized directly by wet mount (saline/iodine) for stool specimen or either by different staining techniques.

## Examination of Feces

### Specimen Collection

- Stool specimens should be collected in a wide-mouthed, clean, leak-proof, screw capped containers and should be handled carefully to avoid acquiring infection from organisms present in stool
- **Timing:** Specimen should be collected before starting antiparasitic drugs and closer to the onset of symptoms
- **Frequency:** At least three stool specimens collected on alternate days are adequate to make the diagnosis of intestinal parasitic diseases (third specimen should be obtained after purgatives).
- **When to examine:** Liquid stool specimens should be examined within 15–30 minutes,

**Table 15.1:** Various morphological forms of parasites seen in different specimens

<b>Specimen</b>	<b>Morphological form</b>	<b>Parasite</b>
Feces	Trophozoite	<ul style="list-style-type: none"> <li>• <i>Entamoeba histolytica</i></li> <li>• <i>Giardia lamblia</i></li> <li>• <i>Balantidium coli</i></li> <li>• <i>Trichomonas hominis</i></li> </ul>
	Cyst	<ul style="list-style-type: none"> <li>• <i>E. histolytica</i></li> <li>• <i>G. lamblia</i></li> <li>• <i>B. coli</i></li> </ul>
	Adult worm	<ul style="list-style-type: none"> <li>• <i>Ascaris lumbricoides</i></li> <li>• <i>Enterobius vermicularis</i></li> <li>• <i>Fasciolopsis buski</i></li> </ul>
	Adult worm segments	<ul style="list-style-type: none"> <li>• <i>Taenia solium</i>, <i>T. saginata</i></li> <li>• <i>Diphyllobothrium latum</i></li> </ul>
	Egg	<ul style="list-style-type: none"> <li>• <i>Schistosoma</i> spp.</li> <li>• <i>Fasciola hepatica</i></li> <li>• <i>Fasciolopsis buski</i></li> <li>• <i>Clonorchis sinensis</i></li> <li>• <i>Opisthorchis felineus</i></li> <li>• <i>Heterophyes heterophyes</i></li> <li>• <i>Metagonimus yokogawai</i></li> <li>• <i>D. latum</i></li> <li>• <i>Taenia</i> spp.</li> <li>• <i>Hymenolepis nana</i></li> <li>• <i>H. diminuta</i></li> <li>• <i>Dipylidium caninum</i></li> <li>• <i>A. lumbricoides</i></li> <li>• <i>Ancylostoma duodenale</i></li> <li>• <i>Necator americanus</i></li> <li>• <i>Enterobius vermicularis</i></li> <li>• <i>Trichuris trichiura</i></li> <li>• <i>Capillaria</i> spp.</li> <li>• <i>Trichostrongylus</i></li> </ul>
Peripheral blood smear	Ring form, schizont and gametocyte	<ul style="list-style-type: none"> <li>• <i>Plasmodium</i> spp.</li> </ul>
	Amastigote	<ul style="list-style-type: none"> <li>• <i>Leishmania</i> spp.</li> </ul>
	Trypomastigote	<ul style="list-style-type: none"> <li>• <i>Trypanosoma</i> spp.</li> </ul>
	Microfilaria	<ul style="list-style-type: none"> <li>• <i>Wuchereria bancrofti</i></li> <li>• <i>Brugia malayi</i></li> <li>• <i>Loa loa</i></li> <li>• <i>Mansonella</i> spp.</li> </ul>
Bone marrow, liver, lymph node and spleen aspirate	Tachyzoite	<ul style="list-style-type: none"> <li>• <i>Toxoplasma gondii</i></li> </ul>
	Amastigote	<ul style="list-style-type: none"> <li>• <i>Leishmania donovani</i></li> </ul>
Liver aspirate	Trophozoite	<ul style="list-style-type: none"> <li>• <i>Entamoeba histolytica</i></li> </ul>
Lymph node aspirate	Trypomastigote	<ul style="list-style-type: none"> <li>• <i>Trypanosoma</i> spp.</li> </ul>
Lymph node biopsy	Adult worm	<ul style="list-style-type: none"> <li>• <i>W. bancrofti</i></li> <li>• <i>B. malayi</i></li> </ul>

Contd...

Contd...

Specimen	Morphological form	Parasite
Cerebrospinal fluid (CSF)	Trypomastigote	• <i>Trypanosoma</i> spp.
	Larva	• <i>Angiostrongylus</i> spp.
	Trophozoite	• <i>Naegleria fowleri</i> • <i>Acanthamoeba</i>
Urine	Trophozoite	• <i>Trichomonas vaginalis</i>
	Microfilaria	• <i>W. bancrofti</i>
	Egg	• <i>Schistosoma haematobium</i> • <i>Diocotophyma renale</i>
Sputum	Adult worm	• <i>Paragonimus</i> spp.
	Egg	• <i>Paragonimus</i> spp. • <i>Capillaria aerophila</i>
	Larva (migrating)	• <i>A. lumbricoides</i> • <i>Strongyloides stercoralis</i> • <i>A. duodenale</i> • <i>N. americanus</i>
	Trophozoite	• <i>E. histolytica</i>
Duodenal aspirate	Trophozoite	• <i>G. lamblia</i>
	Larva	• <i>S. stercoralis</i>
Corneal scrapings	Trophozoite	• <i>Acanthamoeba</i> spp.
Skin	Amastigote	• <i>Leishmania</i> spp.
	Microfilaria	• <i>Onchocerca volvulus</i>
	Larva in skin ulcer fluid	• <i>Dracunculus medinensis</i>
Muscle tissue	Encysted larva	• <i>Trichinella spiralis</i>
	Cysticercus cellulosae	• <i>T. solium</i>
Perianal area	Egg	• <i>Enterobius</i> spp. • <i>T. saginata</i>

semisolid stools within 1 hour and formed stools up to 24 hours after collection. On prolonged storage, trophozoites may disintegrate, become non motile and may appear as artifacts

- Several preservatives (e.g., 10% formalin or polyvinyl alcohol) can be used to maintain the morphology of the parasitic cysts and eggs
- **Specimens other than stool:**
  - **Perianal swabs (cellophane tape or NIH swab):** Useful for detecting Eggs of *Enterobius vermicularis* deposited on the surface of perianal skin. It is also

used for eggs of *Schistosoma mansoni* and *Taenia* species

- **Duodenal contents:** It is very useful for the detection of small intestine parasites like, *Giardia intestinalis* and larva of *Strongyloides stercoralis*. Duodenal fluid can be collected by intubation or by enterotest (discussed in Chapter 4).

### Macroscopic Examination

- **Mucoid bloody stool:** Found in acute amoebic dysentery, intestinal schistosomiasis, and invasive balantidiasis



- Dark red stool indicates upper gastrointestinal (GIT) bleeding and a bright red stool is suggestive of bleeding from lower GIT
- Frothy pale offensive stool (containing fat) found in giardiasis
- Adult worms like round worm, thread worm or segments of tapeworm may be seen.

### Microscopic Examination

#### Direct wet mount (saline and iodine mount)

Drops of saline and Lugol's iodine are placed on two corners of a slide. A small amount of feces is mixed by a stick to form a uniform smooth suspension. Cover slip is placed on the mount and examined under low power objective (10X); followed by high power objective (40X).

Following structures can be visualized by microscopic examination of stool specimen:

- **Normal constituents:** Such as plant fiber, starch cells (stains blue black with iodine), muscle fibers, animal hair, pollen grains, yeast cells, bacteria, epithelial cells, fat globules, and air bubbles are present (Fig. 15.1)
- **Cellular elements:** Like pus cells (in inflammatory diarrhea), red blood cells (RBC) (in dysentery) may be present
- **Charcot Leyden crystals (diamond shaped):** They are the breakdown products of eosinophils and may be seen in the stool or sputum of patients with parasitic diseases

such as amoebic dysentery, ascariasis, and allergic diseases like bronchial asthma (sputum)

- Trophozoites and cysts of protozoa and eggs and larvae of helminths are seen (See appendix VI).

#### Saline mount

##### Advantages

- Useful in the detection of trophozoites and cysts of protozoa and eggs and larvae of helminths
- Motility of trophozoites and larvae can be demonstrated in acute infection
- Bile staining property can be appreciated—bile stained eggs appear golden brown and non bile-stained eggs appear colorless.

#### Iodine mount

##### Advantages

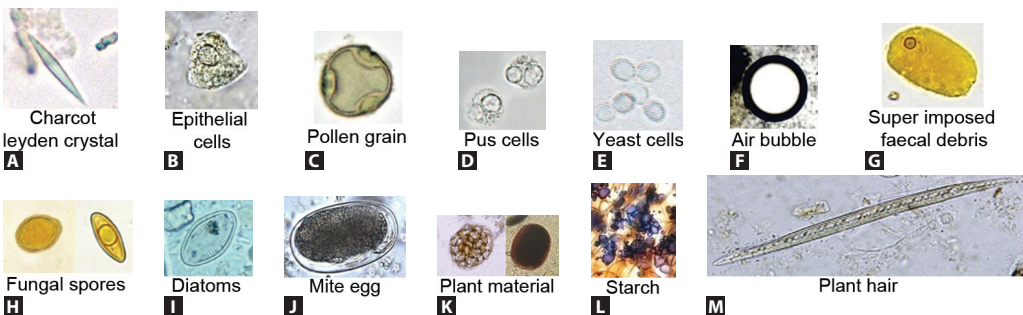
Nuclear details of cysts, helminthic eggs and larvae are better visualized; helps in species identification.

##### Disadvantages

- Iodine immobilizes and kills parasites, hence motility of the protozoan trophozoites and helminthic larvae cannot be appreciated
- Bile staining property cannot be appreciated.

#### Types of iodine stains

- **Lugol's iodine:** Potassium iodide (KI)



**Figs 15.1A to M:** Normal constituents and artifacts found in stool in wet mount examination

Source: A to H- Giovanni Swierczynski, Bruno Milanese "Atlas of Human Intestinal Protozoa Microscopic Diagnosis" (with permission); I to M- DPDx Image Library, Centre for Disease Control and prevention (CDC), Atlanta (with permission)

10g + iodine crystals (5 g) + 100 mL of distilled water

- **D'Antoni's iodine:** KI 1g + Iodine crystals (1.5 g) + 100 mL of distilled water
- **Dobeil's iodine:** KI 2.0 g + iodine 1.0 g + 50 mL of distilled water.

### Permanent stained smear

Permanent stained smears are required for accurate diagnosis of intestinal parasites.

Commonly used methods are:

- Iron-hematoxylin stain
- Trichrome stain
- Modified acid-fast stain

All these permanent stained smears help in the accurate diagnosis of cysts and trophozoites by staining their internal structures.

**Iron-hematoxylin stain:** A thin smear of feces is fixed in Schaudinn's solution (for 15 minutes) and immersed in 70% alcohol containing iodine and then in 50% alcohol for 2–5 minutes each and washed with tap water. Then the slide is immersed in 2% aqueous ferric ammonium sulphate solution for 5–15 minutes followed by washing in tap water for 5 minutes. It is then stained in 0.5% aqueous hematoxylin for 5–10 minutes and washed in tap water for 5 minutes. Finally the smear is immersed in aqueous solution of picric acid for 10–15 minutes and dehydrated by immersing in 50%, 70%, 80% and 95% alcohol for 5 minutes each. Stained smear is placed in xylene (2–5 minutes); then mounted in Canada balsam and covered with coverslip.

**Trichrome stain:** Fecal smear is prepared, fixed and treated with alcohol containing iodine as in case of iron-hematoxylin staining. Then it is stained with trichrome solution for 10 minutes and differentiated in acid alcohol (1 part glacial acetic acid in 99 parts of 90% alcohol) for 2–3 seconds. It is rinsed in absolute alcohol several times and dehydrated in absolute alcohol for 2–5 minutes. Stained smear is placed in xylene (2–5 minutes); mounted in Canada balsam

and covered with coverslip.

**Modified acid-fast stain:** Modified acid-fast stain is used for detection and identification of *Cryptosporidium parvum*, *Cyclospora* and *Isospora belli*. The acid-fast oocyst stains red with carbol fuchsin and the non-acid-fast background stains blue.

- **Hot method:** A thin smear of feces is heat fixed and flooded with carbol fuchsin for 9 minutes. The slide is intermittently heated till carbol fuchsin starts steaming. Then slide is washed with tap water and decolorised with 5% aqueous sulphuric acid for 30 seconds, followed by washing with tap water and counter staining with methylene blue for 1 minute
- **Kinyon's cold method:** Fecal smear is methanol fixed (1 minutes), stained with Kinyon's carbol fuchsin for 5 minutes. Then it is rinsed with 50% ethanol followed by tap water. It is then decolorized with 1% sulfuric acid for 2 minutes, washed with tap water and counter stained with alkaline methylene blue for 1 minute.

### Concentration Techniques

If the parasite output is low in feces (egg, cysts, trophozoites and larvae) and direct examination may not be able to detect the parasites, then the stool specimens need to be concentrated. These methods are also useful in epidemiological analysis and for assessing the response to treatment. Eggs, cysts and larvae are recovered after concentration procedures; however, the trophozoites get destroyed.

Commonly used concentration techniques are:

- **Sedimentation techniques:** Eggs and cysts settle down at the bottom following centrifugation
  - Formalin-ether concentration technique
  - Formalin-ethyl acetate concentration technique
  - Formalin-acetone sedimentation technique

- **Floatation techniques:** The eggs and cysts float at the surface due to specific gravity gradient
  - Saturated salt (sodium chloride) solution technique
  - Zinc sulphate floatation concentration technique
  - Sheather's sugar floatation technique (useful for *Cryptosporidium*, *Isospora* and *Cyclospora*)

Two commonly used concentration techniques are formalin-ether and saturated salt solution technique.

### Sedimentation Techniques

**Principle:** It involves concentration of stool specimen by centrifugation. The protozoan cysts and helminthic eggs are concentrated at the bottom of the tube because they have greater density than the suspending medium.

#### Formol-ether sedimentation technique

##### Procedure (nine steps)

**Step 1:** About half teaspoonful (~ 4g) of feces is transferred to a tube containing 10 mL of 5–10% formalin, mixed thoroughly and allowed to stand for 30 minutes

**Step 2:** Then the mixture is filtered into a 15 mL conical centrifuge tube covered with two layers of gauze. About 8 mL of the filtrate is

collected (3–4 mL for formalin persevered stool)

**Step 3:** 0.85% saline (or 5–10% formalin) is added almost to the top of the tube containing the filtrate and centrifuged for 10 minutes at  $500 \times g$

**Step 4:** The supernatant is discarded and 0.5–1 mL of the sediment is resuspended in saline or formalin (filled up to the top of the tube) and centrifuged again for 10 minutes at  $500 \times g$

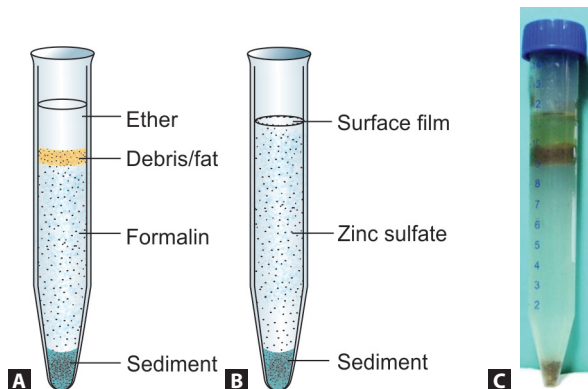
**Step 5:** The sediment is resuspended in 5–10% formalin (filled half of the tube) and centrifuged. This step may be eliminated if the supernatant fluid is clear after the first wash

**Step 6:** 4–5 mL of ether (or ethyl acetate) is added and the tube is closed with a stopper and shaken vigorously to mix well. The stopper is removed and the tube is centrifuged at  $500 \times g$  for 10 minutes

**Step 7:** Four layers are formed. Top layer consists of ether, second is a plug of debris, third is a clear layer of formalin and the fourth is the sediment (Fig. 15.2)

**Step 8:** The debris is removed from the side of the tube with the help of a glass rod and supernatant is discarded

**Step 9:** With a pipette, the sediment is removed and the saline or iodine mount is made and examined under the microscope.



**Figs 15.2A to C:** (A) Formol-ether sedimentation technique (schematic diagram); (B) zinc sulfate flotation concentration technique (schematic diagram); (C) formol ether sedimentation technique (real image)

Courtesy: C- Dr Anand Janagond, Associate professor, Velammal Medical College, Madurai, Tamilnadu (with permission)

**Note**

- Substitute for ether: Since ether is explosive; it can be replaced by ethyl acetate or acetone or clearing agent Hemo-De, which are much safer with equal efficacy
- If the stool is formalin preserved, then the Step 1 is omitted
- If stool contains lot of mucus, then following Step 1, the mixture is centrifuged for 10 minutes at  $500 \times g$  and the sediment is directly mounted
- If the stool is polyvinyl alcohol (PVA) preserved, then following Step 1, the saline or formalin mixed stool is filtered immediately. Then the procedure is same from Step 3
- One should start monitoring the centrifugation time only after reaching the recommended speed by the centrifuge
- The woven gauze should never be more than two layers.

**Advantages**

- The sensitivity of detecting the ova or cysts increases by 8–10 folds
- The size and shape of the parasitic structures are maintained
- Inexpensive, easy to perform
- Fecal odor is removed
- As formaline kills the fecal parasites, no risk of acquiring laboratory acquired infection.

**Disadvantages**

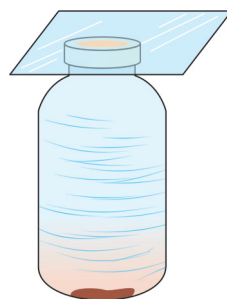
- Trophozoite forms are killed and hence not detected in this method.

**Flotation Techniques**

**Principle:** Flotation involves suspending the specimen in a medium of greater density than that of the helminthic eggs and protozoan cysts. The eggs and cysts float to the top and are collected by placing a glass slide on the surface of the meniscus at the top of the tube.

**Saturated salt flotation technique****Procedure**

- About half tea spoon (~ 4g) of fresh stool is placed in a flat bottomed container of



**Fig. 15.3:** Flotation technique (schematic diagram)

less than 1.5 inches diameter and 20 mL capacity (Fig. 15.3)

- Then, few drops of saturated salt solution (specific gravity 1.200) is added and stirred to make a fine emulsion
- More salt solution is added with stirring throughout to fill the container up to the brim, until a convex meniscus is formed
- A glass slide (3"×2") is carefully laid on the top of the container so that the center is in contact with the fluid
- Preparation is allowed to stand for 20 minutes after which the glass slide is quickly lifted, and examined under the microscope after putting a coverslip.

**Disadvantages**

- Flotation technique is not useful for heavier eggs that do not float in the salt solution such as:
  - Unfertilized eggs of *A. lumbricoides*
  - Larva of *Strongyloides*
  - *Taenia* eggs
  - Operculated eggs of trematodes
- If left for more than 20 minutes, protozoan cysts and thin walled nematode eggs get collapsed and become distorted due to high specific gravity of the solution

**Zinc sulphate flotation concentration technique**

**Step 5:** First five steps are same as that of formol-ether sedimentation technique

**Step 6:** After the second wash, the clear supernatant is poured off and the sediment

is added to a tube containing 2–3 mL of 33% zinc sulfate (specific gravity 1.18). More zinc sulfate solution is added to fill the tube up to the top and the tube is centrifuged again at 500 × g for 2 minutes

**Step 7:** Three layers are formed (Fig. 15.2B). Sample is taken from the surface film by a wire loop (make sure not to dip below the surface film), mounted on a glass slide. Then the supernatant is discarded and the sediment is also mounted and examined.

**Note:**

- The protozoan cysts and lighter helminth eggs are concentrated in the surface film where as operculated and heavy eggs, larvae are deposited in the bottom
- Zinc sulfate of specific gravity 1.20 should be used for formalin preserved stool.

**Preservation of Fecal Specimen**

Preservation of fecal specimens is essential for following reasons:

- To maintain morphology of the parasitic cysts, eggs and larvae
- To prevent further development of some helminthic eggs and larvae
- For teaching purpose
- For epidemiological analysis
- Transport of specimen to a referral lab for further identification.

Several preservation methods are available (Table 15.2):

- **Formalin fixative method:** 5% formalin is recommended for protozoan cysts and 10% formalin for helminthic eggs and larvae
- **Sodium acetate formalin (SAF) fixative method:** Neutral formalin buffered with sodium phosphate buffer is used to maintain the morphology of the parasites
- **Merthiolate-iodine formalin (MIF) solution fixative method:** It contains formalin and Lugol’s iodine; acts both as fixative and stain
- **Schaudinn’s fluid:** It is a mixture of mercuric chloride and ethyl alcohol. It fixes and

**Table 15.2:** Comparison of Stool preservation methods

Preservatives	Advantages	Disadvantages
Formalin	Easy to prepare, long shelf life Overall good for stool concentration Can be used for fecal immunoassay kits	Not good for permanent smear Trophozoites are distorted
MIF (Merthiolate-iodine –Formalin)	Both fixes and stains the stool sample Easy to prepare, long shelf life Useful for the field study Good for stool concentration	Not good for permanent smear Trophozoites are distorted Contains mercury compounds (disposal problem) Not good for faecal immunoassay kits
SAF (Sodium acetate formalin)	Useful for – Stool concentration Permanent smear by iron haematoxylin Faecal immunoassay kits Easy to prepare, long shelf life	Adheres poorly to the slide (albumin coated slide is recommended) Not good for trichrome permanent smear Trophozoites are distorted
Schaudinn’s fluid	Fixative for the fresh stool Excellent for preservation of stool	Contains mercury compounds Not good for concentration Trophozoites are distorted Not good for faecal immunoassay kits
PVA (Polyvinyl alcohol)	Best for trichrome stain Long shelf life (in tight container at room temperature) Excellent for stool preservation, specimens can be shipped to distant places.	Difficult to prepare. Not good to preserve <i>Giardia</i> cyst, <i>Trichuris</i> egg, <i>Isospora</i> oocysts and <i>Strongyloides</i> larvae Trophozoites are distorted Not good for faecal immunoassay kits Contains mercury compounds



preserves the specimen for 1 year or more

- **Polyvinyl alcohol (PVA) fixative method:** PVA powder is incorporated to Schaudinn's fluid. PVA is a plastic resin serves as adhesive for stool specimen where as Schaudinn's fluid helps in fixation. Liquid stool is added to PVA at 1:3 ratio
- **Modified PVA:** It uses copper sulfate or zinc base instead of mercury chloride.

### Egg Counting (Egg quantification)

#### Methods

The intensity of intestinal helminthic infection can be estimated using egg counting in the feces by following methods:

#### *Direct smear counting method of beaver*

- Smear is made by using 2 mg of feces mixed in a drop of saline on a slide and examined under microscope (low power)
- Number of eggs in 2 mg feces is counted and then multiplied by factor 500 to calculate the number of eggs per gram of feces
- It is simple and accurate when performed by an experienced technologist.

#### *Kato's cellophane tape*

Approximate number of eggs per gram of feces in a concentrated stool specimen (sedimentation technique) can be calculated by **Kato's cellophane tape** covered thick smear examination

#### *Stoll's method or dilution egg counting method*

- 4 g of feces is mixed thoroughly with 56 mL of N/10 NaOH in a calibrated Stoll's flask and a uniform suspension is made
- 0.15 mL of this mixture is transferred to the slide. The slide is kept over a mechanical stage and examined under a low power objective and the total number of eggs is counted (n)
- The number of eggs per gram of feces (N) is calculated by multiplying the count (n) with 100

- Estimated daily output of eggs is calculated by multiplying the number of eggs/gram with the weight of 24 hour fecal sample

**Note:** The above mentioned calculation is applied for formed feces. However, the estimate (eggs per gram) will vary according to the consistency of the stool. If feces is not formed, then 'N' is multiplied by the correction factor as given below:

- **Mushy stool (pulpy or soft):**  $N \times 2$
- **Mushy formed:**  $N \times 1.5$
- **Mushy diarrhoeic:**  $N \times 3$

### Examination of Blood

Blood examination is useful in diagnosis of infection caused by blood parasites like *Plasmodium*, *Trypanosoma*, *Leishmania*, *Babesia*, *Wuchereria bancrofti*, *Brugia malayi*, *Loa loa* and *Mansonella*.

Various methods of examination of blood include:

- Direct wet mount examination
- Examination of blood smears after permanent staining
- Examination of buffy coat region (quantitative buffy coat)
- Concentration of blood.

#### Search for tapeworm scolex

- This is very useful for proper identification of species
- 24 hours stool sample is mixed with water, make watery suspension
- The watery suspension is filtered through a double layered sieve
- The cleansed debris is examined with hand lens to look for scolices and proglottids
- If no scolices are found, then the filtration step is repeated and cleansed debris is examined with a magnifying hand lens against the background to increase the contrast
- Tapeworm segments are picked with an applicator stick, rinsed with saline and placed between two slides and observed under low power objective



**Direct Wet Mount Examination**

- A drop of blood is collected by finger prick and placed on a glass slide. A coverslip is placed over the blood drop and examined under low power objective
- Useful for detection of microfilariae and trypanosomes by their motility
- Counting of microfilariae may be done by examining the blood on a neubauer counting chamber.

**Examination of Blood Smears After Permanent Staining**

- Thick and thin blood smears are made from peripheral blood and stained with Romanowsky stains
- Romanowsky's stains include Leishman's stain, Geimsa stain, Field's stain and Jaswant Singh and Bhattacharya (JSB) stain. These stains are a combination of methylene blue and eosin. They also contain oxidation products of methylene blue called **azures**; which provide further contrast in the stained peripheral smears. Stock solutions of these stains are prepared by dissolving the stains in pure methanol.
- Different types of Romanowsky stains
  - Water based stains, e.g., Geimsa, JSB, Field's stain
  - Methanol based stains, e.g., Leishman's and wright's stain.

**Note:**

- For staining thick blood smear, dehemoglobinization is must. While staining with water-based stains, this occurs when the stain is poured on the thick smear; but, for methanol-based stains, additional step of dehemoglobinization by adding water is necessary before pouring the stain.
- Thin blood smears must be methanol fixed before staining to prevent dehemoglobinization. When methanol-based stains are used, this occurs when the stain is poured on the smear; but for water-based stains, additional step of methanol fixation

is necessary before pouring the stain

- Details of the stain composition and procedures are discussed in Appendix 4. Method to make the smears is given in Chapter 6.

**Quantitative Buffy Coat (QBC)**

- This involves collection of blood in a capillary tube coated internally with acridine orange stain, centrifugation at 12,000 rpm for 5 minutes and examination of the buffy coat region under ultraviolet (UV) rays
- This extremely useful for the detection of the malaria parasites and microfilariae
- Detail is given in Chapter 6.

**Concentration of Blood**

Concentration techniques are useful for detection of microfilariae from blood specimen.

Various concentration methods are:

- Sedimentation technique
- Cytocentrifugation (cytospin)
- Knott's concentration
- Gradient centrifugation
- Membrane filtration

**Sedimentation technique**

5–10 mL of blood is collected and centrifuged at 500×g for 2 minutes. Supernatant is discarded and the sediment is used to prepare a smear. The smear is air dried, fixed and stained.

**Knott concentration**

10 mL of 2% formalin is mixed thoroughly with 1 mL of venous blood in a centrifuge tube and centrifuged at 500×g for 2 minutes. Sediment is collected; smear is prepared, stained and examined for microfilariae.

**Gradient centrifugation**

Heparinized venous blood (4 mL) is mixed with 4 mL of Ficoll-hypaque solution and centrifuged at 400×g for 40 minutes. Three distinct layers are formed; lower most white blood cell (WBC) layer, middle Ficoll-hypaque layer and upper most plasma layer. The middle layer is examined for presence of microfilariae.

### Membrane filtration

- Blood (1 mL) is lysed by shaking gently with 10 mL of distilled water in a syringe. Then the lysed blood is passed through 25 mm membrane filter of pore size 5 µm such as millipore or Nucleopore membrane filters. The microfilariae are liberated from the blood on the filter. The filter is removed, stained and examined
- For detection of *Mansonella perstans* microfilariae, 3 µm size membrane filter is used.

### Examination of Skin Tissue

#### Skin Snips

Skin snips are thin horizontal slices of epidermis, which are used for demonstration of *Onchocerca volvulus*. Collected skin snips are incubated in saline, to allow the microfilariae to emerge.

#### Skin Biopsy

Useful for histopathological examination.

### Examination of cerebrospinal fluid (CSF)

Direct wet mount examination of cerebrospinal fluid (CSF) is useful for the detection of motile free living amoebae, (*Naegleria* and *Acanthamoeba*), trypanosomes and larvae of *Angiostrongylus cantonensis*.

### Examination of Aspirates from Lymph Node, Spleen, Liver and Bone Marrow

#### Direct Microscopy

- Wet mount preparation or stained smears are very useful in detecting intracellular parasites such as *Leishmania* and *Trypanosoma* species
- Aspirate from hydatid cyst of liver or lung is useful for diagnosis of cystic echinococcosis
- Wet mount preparation of aspirated amoebic liver pus, is useful in the diagnosis of amoebic liver abscess.

### Biopsy

Histopathological examination of affected tissues is very useful in detection of localized or disseminated infections caused by the parasites.

### Examination of Sputum

Examination of sputum is useful in demonstration of eggs of *Paragonimus* in cases of pulmonary paragonimiasis and trophozoites of *E. histolytica* in cases of pulmonary amoebiasis.

### Examination of Urogenital Specimen

Examination of vaginal discharges is useful in detection of *Trichomonas vaginalis* trophozoites. The trophozoites can be identified by their typical jerky motility.

## CULTURE TECHNIQUES IN PARASITOLOGY

### Culture Methods for Protozoa

The protozoa feed on bacteria, so the culture media are supplemented with bacterial growth. Accordingly there are four types of culture media are used for protozoa:

1. **Axenic cultures:** If the parasites are grown as pure culture without any bacterial associate, the culture is referred as axenic culture
2. **Xenic cultures:** Cultures of parasite grown in association with an unknown microbe are referred as xenic cultures
3. **Monoxenic culture:** If the parasites are grown with a single known bacterium, the culture is referred as monoxenic culture, e.g., corneal biopsy specimens cultured with *E. coli* for recovering *Acanthamoeba*
4. **Polyxenic culture:** It contains multiple bacterial supplements, starch and serum providing nourishment to amoeba.

### Uses of Culture Media

Culture media are not routinely used in diagnostic parasitology. They are useful in research and teaching purpose.

- Polyxenic media is used for cultivation of protozoa from the suspected patients

- Axenic culture is useful when the bacterial flora interferes with the result such as:
  - Studying pathogenicity
  - Drug susceptibility testing
  - Preparation of antigen for serological tests.

### Culture Media Used for *Entamoeba histolytica*

Culture media used for *E. histolytica* are given in Table 15.3.

### Culture Media Used for Free-Living Amoebae

- **Non nutrient agar:** Useful for the isolation of *Acanthamoeba* and *Naegleria*.
  - **Composition:** Page's saline, Difco agar, distilled water and monoxenic cultures of *E. coli* or *Enterobacter aerogenes*. Page's saline is a mixture of NaCl, CaCl<sub>2</sub>, MgSO<sub>4</sub>, Na<sub>2</sub>HPO<sub>4</sub> and KH<sub>2</sub>PO<sub>4</sub>
  - **Procedure of cultivation:** The sample (CSF, contact lens solutions or tissue samples) is inoculated on the center of the nonnutrient agar plate coated with bacterial overlay. The surface of the plate is examined under low power objective for 10 days for the presence of amoebae. Thin linear tracks (areas

where amoebae have ingested the bacteria) might also be seen

- *Balamuthia* species cannot be cultured by this method. They can be grown by using tissue culture methods

- **Peptone yeast extract glucose (PYG) liquid culture media:** Useful for cultivation of *Acanthamoeba* species
- **Nelson's liquid culture medium:** Useful for cultivation of *N. fowleri*. Nelson's medium is prepared by addition of fetal calf serum or brain extract to PYG medium
- **Tissue culture techniques:** Various mammalian cell lines such as monkey kidney cell line, HEp<sub>2</sub> and diploid macrophage cell line are used for cultivation of *Acanthamoeba*, *Naegleria* and *Balamuthia* species.

### Culture Media Used for *Giardia lamblia*

*Giardia* can be cultivated in axenic media like Diamond's media used for cultivation of *E. histolytica*.

### Culture Media Used for *Trichomonas vaginalis*

- Lash's cysteine hydrolysate serum media
- Cysteine peptone liver maltose (CPLM) media
- Diamond's trypticase yeast maltose (TYM) media

**Table 15.3:** Culture media used for *Entamoeba histolytica*

Culture medium	Type	Important ingredients
Boeck and Dr bohlay's medium	Polyxenic	Solidified egg or solidified blood, Locke's solution*, Inactivated bovine calf serum
Balamuth's medium	Polyxenic	Egg-yolk-liver concentrate infusion medium
Robinson's medium	Polyxenic	Erythromycin, Bacto peptone, Phthalate solution, bovine serum, <i>E. coli</i> strain 0111 and R-medium**
Jones' medium	Polyxenic	Horse serum and yeast autolysate in phosphate buffered saline
Diamond's (TYM) medium	Axenic	Trypticase-yeast extract-maltose

**\*Locke's solution:** Composed of sodium chloride (8.0 g), 0.2 g calcium chloride, potassium chloride (0.2g), magnesium chloride (0.01 g), sodium phosphate, dibasic (2.0 g), sodium bicarbonate (0.4 g) and potassium phosphate, monobasic (0.3 g)

**\*\*R-medium:** Composed of sodium chloride, citric acid, potassium phosphate buffer, ammonium sulfate, magnesium sulfate and lactic acid.

- Hollander's modification of TYM medium
- Cell lines like McCoy cell line highly sensitive, can detect as low as three trophozoites/mL.

### Culture Media Used for *Leishmania* and *Trypanosoma*

- **NNN medium (described by Novy, McNeal 1903 and Nicolle 1908):** It supports the growth of flagellates causing leishmaniasis and Chagas' disease
  - **Composition:** It is biphasic media composed of two part salt agar and one part defibrinated fresh rabbit blood. The medium (4 mL) is dispensed and allowed to solidify in slanted position
  - **Procedure:** Materials (blood, bone marrow aspirate, splenic pulp) are inoculated in water of condensation of the NNN medium and incubated at 37°C for 1–4 week
  - **Observation:** The culture fluid is examined every day upto 10 days of inoculation for the presence of flagellates. On the solid medium, flagellates grow as thick, grayish white mucoid spreading lawn
- **Liquid medium for hemoflagellates:**
  - *Schneider's Drosophila* medium (30% fetal calf serum) and Grace's insect tissue culture medium
  - Amastigote forms transform to promastigote forms and multiply by binary fission
  - It is found to be more sensitive and rapid than NNN media
- **Other media:**
  - Yaeger's LIT medium for Chagas' disease
  - USAMRU blood agar medium for leishmaniasis.

### Culture Techniques Used for *Malaria* Parasites

- Culture techniques for malaria parasites are mainly used for preparation of malaria antigens

- Trager and Jensen technique using **RPMI 1640 medium** is most widely used method. In detail discussed in Chapter 6.

### Culture Techniques used for Larval-Stage Nematode

- Fecal culture methods (copro-culture) are especially useful for specific identification of hookworm, *Strongyloides stercoralis* and *Trichostrongylus* species
- Eggs hatch out into rhabditiform larvae in the culture medium which can be used to differentiate between hookworm, *Strongyloides stercoralis* and *Trichostrongylus* species
- Further rearing of nematode larvae leads to transformation into filariform larvae which can be used to differentiate *A. duodenale* and *N. americanus*.

### Harada-Mori Filter Paper strip Culture (Fig. 15.4A)

- Smear is made with 0.5 g to 1 g of fresh feces in the center of a narrow strip of filter paper (15 cm × 1.5 cm)
- The filter paper is placed in a conical centrifuge tube with sterile water in such a way that the lower end dips in water
- This preparation is incubated for 7–10 days at room temperature after sealing the mouth of the tube
- Larvae develop on the filter paper migrate and are liberated in water, which can be examined under a microscope.

### Petri Dish/ Slant Culture Method (Little et al.) (Fig. 15.4B)

- Fresh stool material is placed on the microscope slide shaped filter paper
- The filter paper is then placed on the slanted glass slide, kept in a glass petri dish plate containing water
- This technique allows direct examination of the culture system with a dissecting microscope to look for nematode larvae in the fecal mass.

### Charcoal Culture

- 20 g of fresh stool mixed in water to form thick suspension, which is then added to storage dish containing granulated charcoal. Water is added to provide moisture. The dish is covered, and placed in dark for 5–6 days
- The hookworm and *Strongyloides* infective stage larvae can be harvested
- The condition of this culture technique provides an environment that mimics natural condition, efficient to harvest large numbers of infective-stage larvae.

### Baermann Technique (Fig. 15.4C)

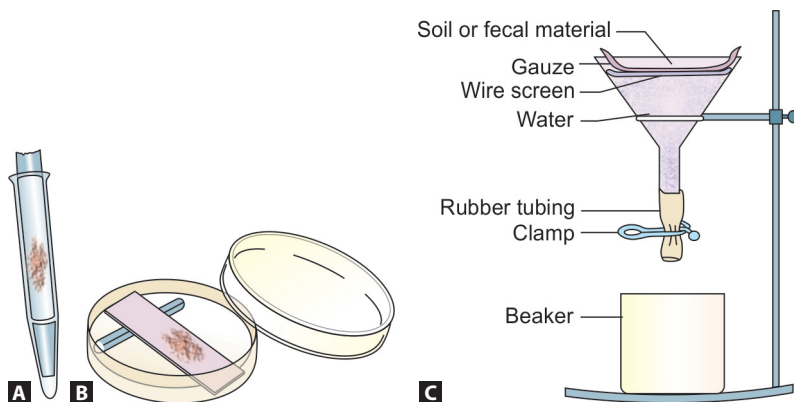
- This technique is useful for examining a stool specimen suspected of containing small numbers of *Strongyloides* larva
- This technique exploits the property of the *Strongyloides* larva to migrate from cooler to warmer area
- **Procedure:**
  - This method uses glass funnel fitted with a rubber tubing and clamp
  - A round wire screen is kept on the surface of the funnel, above which a piece of gauze is placed
  - 5 g of feces is placed on the gauze

- Funnel is filled with warm water, left for 1–2 hours to give time for *Strongyloides* larvae to emerge from the feces
- Clamp of the tubing is opened and 7–10 mL of fluid is collected in a beaker. Larvae in the stool migrate downward to the bottom in the fluid
- After centrifugation, sediment is examined microscopically

- **Modification of Baermann Technique:** Funnel used in the original version is replaced by a test tube with a rubber stopper, which is perforated to allow insertion of a plastic pipette tip. The tube containing the fecal suspension is inverted over another tube containing 6 mL of saline solution and incubated at 37°C for 2 hour. Centrifuged saline solution is screened for larvae.

### Agar Plate Culture for *Strongyloides Stercoralis*

- Agar plates are composed of 1.5% agar, meat extract (0.5%), peptone (1%) and NaCl (0.5%)
- Approximately, 2 g of fresh stool specimen is placed onto agar plates; the plates are sealed and held for 2 days at 26–33°C
- The plates are examined under the microscope for the presence of tracks (bacteria carried over agar by migrating larvae)



**Figs 15.4A to D:** Schematic diagram of techniques (A) Harada-Mori filter paper strip culture; (B) petri dish/slant culture method; (C) Baermann technique

- Then the surface of the agar is washed with 10% formalin, centrifuged and the sediment is screened for the presence of nematode larvae
- Daily search for furrows on agar plates for up to 6 consecutive days results in increased sensitivity for diagnosis of both *S. stercoralis* and hookworm larvae.

## IMMUNODIAGNOSTIC METHODS

This method involves detection of parasite specific antibodies in serum, and detection of circulating parasitic antigen in the serum.

Immunodiagnostic methods are useful when:

- Parasites are detected only during the early stages of the disease
- Parasites occur in very small numbers
- Parasites reside in internal organs and morphological identification is not possible

- When other techniques like culture are time consuming.

## Antibody Detection Tests

Antibodies are detected in various parasitic infections mainly from serum, sometime from other sites like CSF (neurocysticercosis) or pleural fluid (paragonimiasis).

Various antibody detection methods are:

- **Older methods:** Agglutination tests, complement fixation tests (CFT), gel electrophoresis, indirect hemagglutination assay (IHA) and counter-current Immuno-electrophoresis (CIE), less sensitive and specific
- **Recent techniques:** Indirect fluorescent antibody test (IFA), enzyme-linked immunosorbent assay (ELISA) (Table 15.4 and 15.5), rapid Immunochromatographic

**Table 15.4:** ELISA for detection of antibodies

Disease	Antibody against	Comments
Amoebiasis	Lectin antigen of <i>Entamoeba histolytica</i>	Sensitivity 75–85% Specificity > 85%
Visceral Leishmaniasis	Antigen of <i>Leishmania donovani</i>	Sensitivity (90%) Specificity (low)
Chagas' disease	<i>Trypanosoma cruzi</i> specific recombinant and synthetic peptide antigens	Less specific as it cross reacts with <i>T. rangeli</i> infection, leishmaniasis
Toxoplasmosis (double-sandwich IgM-ELISA)	Recombinant <i>Toxoplasma gondii</i> specific antigen and anti IgM capture antibody	Highly specific and sensitive in Diagnosing acute toxoplasmosis
Cryptosporidiosis	<i>Cryptosporidium parvum</i> oocyst antigen	Useful for seroepidemiology
Neurocysticercosis	Crude extract of cysticerci or vesicular fluid of <i>Taenia solium</i> detecting antibodies in serum and CSF	Sensitivity 75–90% Specificity (low)
Hydatid disease	Crude <i>Echinococcus granulosus</i> cyst fluid antigen	Sensitivity—variable (60–90%)
Schistosomiasis HAMA- FAST- ELISA (falcon assay screening test )	Using <i>Schistosoma hematobium</i> adult worm microsomal antigen (HAMA)	Useful for seroepidemiology.
Paragonimiasis	Purified adult excretory-secretory antigen of <i>Paragonimus westermani</i>	High sensitivity especially with pleural fluid than serum
Strongyloidiasis	Crude larval antigens	Sensitivity (95%) Useful when stool microscopy is negative
Lymphatic filariasis	<ul style="list-style-type: none"> <li>• Crude parasitic extract</li> <li>• Recombinant <i>Wuchereria bancrofti</i> antigens</li> </ul>	Useful for seroepidemiology Also detect <i>Brugia</i> infection



**Table 15.5:** ELISA for Detection of antigens

<b>Disease</b>	<b>Antigen detected</b>	<b>Comments</b>
Amoebiasis	170 kDa of lectin antigen of <i>Entamoeba histolytica</i> in stool or serum	Stool <ul style="list-style-type: none"> <li>• Sensitivity &gt; 95%</li> <li>• Specificity &gt; 95%</li> </ul> Serum <ul style="list-style-type: none"> <li>• Sensitivity 65% (early stage)</li> <li>• Specificity &gt; 90%</li> </ul>
Giardiasis	Cyst wall protein antigens in stool	Sensitivity (90–100%) Specificity (99–100%)
Chagas' disease	<i>Trypanosoma cruzi</i> specific antigens from serum and urine	Useful for acute and congenital infection and drug response monitoring
Toxoplasmosis	<i>Toxoplasma gondii</i> specific antigens in blood/body fluid or amniotic fluid	Useful for diagnosis of acute and congenital infection
Cryptosporidiosis	<i>Cryptosporidium parvum</i> oocyst antigen in stool	Sensitivity (66–100%) Specificity (> 90%)
Intestinal taeniasis	<i>Taenia</i> specific antigen in stool by using polyclonal <i>Taenia</i> antibodies	More sensitive than stool examination But cannot differentiate between <i>Taenia saginata</i> and <i>Taenia solium</i>
Schistosomiasis	Circulating cathodic antigen (CCA) in urine Circulating anodic antigen(CAA) in serum Soluble egg antigen in serum	Sensitivity of 90% (serum) and 94 % (urine) Indicates recent infection used for monitoring the treatment
Lymphatic filariasis	Detects filarial antigens by using monoclonal Og4C <sub>3</sub> and AD1 <sub>2</sub> antibodies	Highly sensitive (100%) and specific (99–100%) Can be detected in day time Differentiates between current from past infections- Used for monitoring response to treatment Can be detected in urine

**Table 15.6:** Rapid immunochromatographic tests in parasitic diagnosis (Principle of ICT is discussed in detail in malaria chapter)

<b>Disease</b>	<b>Target</b>	<b>Comments</b>
<b>Antigen detection</b>		
Malaria	Histidine rich protein-2 (Pf. HRP 2) <i>Plasmodium falciparum</i> specific Parasite lactate dehydrogenase (pLDH) common to all species	Sensitivity >90% ( at parasite density >100/μL) pLDH—monitor response to treatment HRP-2—diagnose malaria in pregnancy
Triage parasite panel (for amoebiasis, giardiasis and cryptosporidiosis)	Simultaneous detection of <i>Giardia lamblia</i> , <i>Entamoeba histolytica</i> and <i>Cryptosporidium parvum</i>	Sensitivity (83–96%) Specificity (99–100%)
Lymphatic filariasis	Detects filarial antigens by using monoclonal Og4C3 and AD12 antibodies	Highly sensitive (96–100%) and specific (95–100%) Can be detected in day time Differentiates current from infection—used for monitoring response to treatment. Can be detected in urine
<b>Antibody detection</b>		
Visceral Leishmaniasis	<i>Leishmania infantum</i> recombinant kinesin 39 (rk39)	Sensitivity (98%) Specificity (90%)

tests (ICT) (Table 15.6) and Immunoblot (Western blot) (Table 15.7), more sensitive and specific.

**Antigens used for the antibody detection are obtained:**

- Crude antigen from cultured parasites, by animal inoculation or by natural infections to humans
- Recombinant or synthetic antigens
- From related parasites or related bacteria

**Limitations of antibody detection techniques:**

- Cannot distinguish between acute and chronic infection. [However, immunoglobulin M (IgM) based assay can diagnose recent infection accurately]
- Less specific: Cross reactive antibodies are found in unrelated infections due to heterogeneity of parasitic antigens
- Speciation is not possible.

**Antigen Detection Tests**

Most commonly used antigen detection tests are:

- ELISA (Table 15.5)
- Direct fluorescent antibody assays (DFA)
- ICT (Table 15.6).

**Advantages of antigen detection tests:**

- Detection of circulating parasitic antigen in serum, urine, genital specimen or feces
- Provides information about acute/recent infection
- Used to monitor the response to treatment
- Useful when microscopy is negative
- To diagnose congenital infection
- Assessing the severity of infection.

**MOLECULAR METHODS**

Molecular methods most frequently used in diagnostic parasitology include:

**Table 15.7:** Western blot (Enzyme linked immunotransfer blot/EITB) in parasitic diagnosis

Basic Principle of Western blot		
<b>Step-1:</b> PAGE (Polyacrylamide gel electrophoresis)→ parasitic antigens are mobilized electrophoretically and separated into smaller antigen fragments		
<b>Step-2:</b> Nitrocellulose membrane (NCM) blotting → antigenic fragments are blotted on NCM		
<b>Step-3:</b> Enzyme immunoassay → Detects antibodies against the antigenic fragments		
Disease	Target	Comments
Chagas' disease	Peptide antigenic fragments	Highly specific, confirms the diagnosis
Neurocysticercosis	Lentil lectin purified seven glycoprotein (LL-Gp) antigenic fractions of <i>Taenia solium</i>	Sensitivity—98% (when > 3 cysticerci detected in CNS) Specificity (nearly 100%)
Hydatid disease	Antibody against antigen B fragment of <i>Echinococcus granulosus</i> (produces 8-12kDa band)	Sensitivity (92%) Specificity (100%) Useful for seroepidemiological study
	Em-18 antigenic fragment of <i>E. multilocularis</i>	Sensitivity (97%) Specificity (100%) Doesn't cross react with <i>E. granulosus</i>
Schistosomiasis HAMA-EITB	Using <i>S. hematobium</i> adult worm somal antigen (HAMA).	Confirms the diagnosis Useful for seroepidemiology.
Paragonimiasis	Adult worm homogenate antigen of <i>Paragonimus westermani</i>	Highly sensitive and specific

- DNA probes
- Polymerase chain reaction (PCR).

**DNA Probe**

DNA probe consists of radiolabelled nucleotide sequences that is complementary to a part of the parasitic DNA present in the clinical samples. This is highly specific and reproducible. Currently, DNA probe based methods are available for the detection of *P. falciparum*, *W. bancrofti* etc.

**Polymerase Chain Reaction (PCR)**

Polymerase chain reaction (PCR) is an *in-vitro* procedure for DNA amplification. The procedure involves

- Parasitic DNA extraction
- **Amplification:** This involves repeated cycles of i) Denaturation of ds DNA, ii) Annealing

of primers (oligonucleotide sequences that hybridizes with the complementary regions present in the extracted target DNA), iii) Extension of the primers with the help of Taq DNA polymerase.

- Detection of the amplified products by gel electrophoresis.

**Advantage:** It is more sensitive and specific (can detect even few parasitic DNA), rapid, used for speciation, drug resistance detection and for research purpose.

PCR is now days increasingly used for the diagnosis of various parasitic infections (Table 15.8).

■ **INTRADERMAL SKIN TESTS**

Skin tests are useful when a reliable antibody detection methods are not available. They are employed for research and epidemiological purpose. Positive intradermal skin tests are

**Table 15.8:** Polymerase chain reaction in parasitic diagnosis

Disease	Target	Comments
Amoebiasis	Nested PCR targeting small subunit rRNA genes	Can differentiate the subspecies— <i>E. histolytica/dispar/moshkovskii</i> Sensitivity > 90% Specificity 90–100%.
	Real-time PCR	More sensitive, takes less time with less contamination rates
Visceral Leishmaniasis	<i>Leishmania</i> specific kinetoplast (mitochondrial) DNA	Sensitivity 70–93% Available only in limited laboratories
Malaria	Using PBRK1 primer	Not for routine use Used for speciation, drug resistance detection and for research purpose
Cryptosporidiosis	<i>C. parvum</i> genes from both clinical and environmental samples	More sensitive, can differentiate various genotypes of <i>C. parvum</i> , hence useful in outbreak situations
Hydatid disease	PCR-RFLP targeting mitochondrial DNA of <i>Echinococcus granulosus</i>	Can differentiate genotypes of <i>E. granulosus</i> (G1 to G10)
Clonorchiasis	Multiplex PCR	Can differentiate <i>Clonorchis</i> and <i>Opisthorchis</i>
Strongyloidiasis	Real-time PCR to detect <i>Strongyloides</i> DNA in stool	Nearly 100% specificity and high sensitivity Used for research purpose
Lymphatic filariasis	PCR-RFLP based assays by using ITS 1- rRNA genes as primers	Can differentiate all the filarial species

**Abbreviations:** PCR, polymerse chain reaction; DNA, Deoxyribonucleic acid; RFLP, restriction fragment length polymorphism

**Table 15.9:** Intradermal skin tests in parasitic diagnosis

<b>Skin tests showing immediate hypersensitivity in</b>	<b>Showing delayed hypersensitivity in</b>
Hydatid disease (Casoni's test)	Leishmaniasis (Montenegro test)
Filariasis	Trypanosomiasis
Schistosomiasis	Toxoplasmosis
Ascariasis	
Strongyloidiasis	
Trichinellosis (Bachman test)	

suggestive of past exposure. As they remain positive for longer duration, so they cannot differentiate old and recent infection. More so, non standardized crude antigens are used, hence they lack sensitivity and specificity. There is always a danger of provoking an anaphylactic reaction in the patient (Table 15.9).

## XENODIAGNOSTIC TECHNIQUES

### Principle

Xenodiagnosis uses laboratory reared arthropod vectors to detect low levels of parasites during chronic stages of the disease, when their numbers in the blood will be very low.

- This technique is employed to diagnose Chagas' disease
- This technique may be useful in endemic areas, but not in routine diagnostic laboratories

### Xenodiagnosis in Chagas' Disease

#### Procedure

- Laboratory reared *Triatomine* (reduviid) bugs are starved for 2 weeks and then fed on the patient's blood, suspected to have Chagas' disease

- If Trypanosomes are present in the blood, they will multiply and develop into epimastigotes and trypomastigotes in about 30 days and are passed in the feces of the reduviid bug
- After 1–2 months, feces from the bugs are examined over a 3 month period for the developmental stages of the parasite, in the hind gut of the bug. The bugs may also be dissected and examined microscopically.

## ANIMAL INOCULATION METHODS

Animal Inoculation techniques are not routinely used in diagnosis of parasitic infections; but useful in some parasitic infections (Table 15.10).

## IMAGING TECHNIQUES

Being noninvasive methods, imaging techniques such as the X-ray, ultrasound (USG), computed tomography (CT) and magnetic resonance imaging (MRI) are extensively used various space occupying parasitic infections (Table 15.11).

**Table 15.10:** Animal inoculation methods in parasitic diagnosis

<b>Parasite tested</b>	<b>Animal used</b>	<b>Route of inoculation</b>	<b>Specimen inoculated</b>	<b>Method of demonstration</b>	<b>Observation after inoculation</b>
<i>Toxoplasma gondii</i>	Mice and Rats	0.5 mL of material injected intra-peritoneally	Body fluid, blood, lymph node fluid or cerebrospinal fluid	Peritoneal fluid obtained after 7–10 days, stained with Romanowsky's stain	If animal survives after 6 months, the serum of the animal shows presence of antibodies

Contd...

Contd...

<i>Leishmania donovani</i>	Young hamsters (2–3 months old)	0.5–1 mL of material injected intra-peritoneally	Aspirates or biopsy obtained from cutaneous ulcers, lymphnodes, spleen, liver or bone marrow	Splenic impression smears are prepared after 4–6 weeks, stained with Romanowsky's stain	Positive cases animal dies several days after the inoculation
<i>Trypanosoma</i> species	Mice and Rats, Guinea pigs	Intra-peritoneal or in tail vein	Blood, lymph node aspirate or spinal fluid	Blood sample is collected after 2 weeks, smears are prepared and stained with Romanowsky's stain	Stained smear shows presence of the parasite
<i>Trichinella spiralis</i>	Rats	Feed orally	Infected muscle tissue	Rats are examined for <i>Trichinella spiralis</i> larvae in the muscle of the infected rat	Mainly, <i>Trichinella spiralis</i> larvae can be demonstrated in the diaphragm

**Table 15.11:** Imaging methods in parasitic diagnosis

<b>Disease</b>	<b>Imaging method used</b>	<b>Comments</b>
Amoebic liver abscess	USG	Detects the location of abscess and its extra hepatic extension
Hydatid disease	X-ray, USG, CT scan and MRI	<ul style="list-style-type: none"> <li>• <b>X-rays:</b> It is simple, inexpensive, yet useful technique to detect hepatomegaly and calcified cysts and cysts in lungs</li> <li>• <b>USG:</b> It is the imaging method of choice because of its low cost and high diagnostic accuracy. It detects both single and multiple cystic lesions, floating membrane (Water lily sign) and daughter cysts. It is also useful to monitor the response to treatment and for epidemiological studies</li> <li>• <b>CT scan:</b> It is superior to detect smaller cysts, calcified cysts, extrahepatic cysts and to differentiate from other cystic lesions. Also used as a prognostic marker</li> <li>• <b>MRI:</b> It has a higher contrast resolution, which makes cysts clearer. It can be used as an alternate to CT scan.</li> </ul>
<i>Trichinella spiralis</i>	X-ray	Detects calcified muscle cysts
Neurocysticercosis	CT scan and MRI	<b>Detects:</b> Number, location, size, of the cysts and extension and stage of the disease <b>CT scan:</b> For calcified cysts <b>MRI:</b> It is superior to CT scan, to detect extraparenchymal cysts, vesicular, necrotic lesions and non-cystic lesions
<i>Paragonimus westermani</i> infection	X-ray, MRI and CT scan	<b>X-ray:</b> Pulmonary cysts <b>MRI and CT Scan:</b> locate extrapulmonary cysts (CNS)
<i>Clonorchis</i> and <i>Opisthorchis</i>	Cholangiography	Detects site of the lesion and obstruction of the biliary tract
Filariasis	USG	<ul style="list-style-type: none"> <li>• Serpentine movement within the lymphatic vessels of scrotum (filarial dance sign)</li> <li>• Dilated and tortuous lymphatic vessels</li> </ul>

**Abbreviations:** USG, ultrasonography; CT, computed tomography; MRI, magnetic resonance imaging; CNS, central nervous system

### EXPECTED QUESTIONS

#### I. Write short notes on:

- (a) Culture methods in diagnostic parasitology
- (b) Stool concentration techniques
- (c) Blood concentration methods for microfilariae detection
- (d) Western blot in diagnostic parasitology
- (e) Use of Immunochromatographic tests in parasitic diagnosis
- (f) PCR in diagnostic parasitology
- (g) Use of ELISA in parasitic diagnosis
- (h) Xenodiagnostic techniques in diagnostic parasitology
- (i) Intradermal skin tests in parasitic diagnosis
- (j) Animal inoculation methods used in diagnostic parasitology

#### II. Multiple choice questions (MCQs):

##### 1. Advantages of saline mount are all except:

- (a) Useful in the detection of trophozoites and cysts of protozoa and eggs and larvae of helminths.
- (b) Nuclear details of cysts and helminthic eggs and larvae are better visualized
- (c) Motility of trophozoites and larvae can be seen in acute infection

- (d) Bile staining property can be appreciated

##### 2. Flotation technique is useful for detection of:

- (a) Fertilized eggs of *Ascaris lumbricoides*
- (b) Larva of *Strongyloides*
- (c) *Taenia* eggs
- (d) Operculated eggs of trematodes

##### 3. One of the statement is not correct for PVA (polyvinyl alcohol):

- (a) Difficult to prepare
- (b) Not good to preserve *Giardia* cyst
- (c) Good for fecal immunoassay kits
- (d) Contains mercury compounds

##### 4. Boeck and Drbohlav's medium is used for the cultivation of:

- (a) *Entamoeba histolytica*
- (b) *Leishmania donovani*
- (c) Malaria parasite
- (d) Hookworm

##### 5. Which of the following medium is used for cultivation of malaria parasite:

- (a) Diamond's (TYM) medium
- (b) NNN medium
- (c) Cysteine peptone liver maltose media
- (d) RPMI 1640 medium

### Answer

1. (b)    2. (a)    3. (c)    4. (a)    5. (d)



# 16 Medical Entomology

## Chapter Outline

- Medical entomology
- Vector
- Class insecta
- Class arachnida
- Class crustacea
- Control of arthropods
- Expected questions

## MEDICAL ENTOMOLOGY

A study of the arthropods of medical importance is known as **medical entomology**. Arthropods act as important vectors in disease transmission of many parasitic diseases which are of human concern. Arthropods are invertebrates, consisting of a segmented body, several pairs of jointed legs, rigid exoskeleton, internal organs and body divided into head, thorax, and abdomen.

Phylum Arthropoda is divided into five classes, out of which Class Insecta, Class Arachnida, and Class Crustacea are of medical importance (Table 16.1 and 16.2).

## VECTOR

It is an arthropod that transmits infection. Transmission of infection to the host is by biting or by deposition of the infective material near the bite, on food or other objects.

## Biological Transmission

- **Propagative:** Only multiplication of the parasite takes place inside the vector, e.g., *Yersinia pestis* in rat fleas
- **Cyclodevelopmental:** Only development of the parasite takes place inside the vector, e.g., *Wuchereria bancrofti* in mosquitoes
- **Cyclopropagative:** Multiplication and development (both) takes place inside the vector, e.g., *Plasmodium* species in mosquitoes.

## CLASS INSECTA

### Mosquitoes

#### Identification features

Body of mosquito consists of three parts:

- **Head:** It is semiglobular, bears a pair of compound eyes, a long proboscis, a pair of palpi and a pair of antennae (bushy

**Table 16.1:** Classification of arthropods

Phylum	Class	Common names
Arthropoda	Insecta	Mosquitoes, black flies, sand flies, deerflies, houseflies, tsetse flies, fleas, cockroaches, lice, bugs, wasps, etc
	Arachnida	Hard ticks, soft ticks, itch mites, scorpions, chiggers, etc
	Myriapoda	Centipedes, millipedes, etc
	Pentastomida	Tongue worms, etc
	Crustacea	Cyclops, crabs, crayfish, etc

**Table 16.2:** Arthropods acting as vectors in transmission of medically important human diseases

Arthropods	Diseases transmitted		
	Parasitic	Viral	Bacterial
Mosquito	Malaria Bancroftian filariasis Malayan filariasis	Yellow fever Dengue fever Chikungunya Japanese encephalitis Rift Valley fever, O'Nyong-Nyong, Western and Eastern equine encephalitis	-
Sandfly	Kala-azar Oriental sore	Sandfly fever	Oroya fever
Tsetse fly	Sleeping sickness	-	-
Housefly (mechanical vector)	Amoebiasis Helminthiasis	Poliomyelitis	Typhoid fever Paratyphoid fever Cholera Trachoma Yaws
Blackfly ( <i>Simulium</i> spp.)	Onchocerciasis	-	-
Deerfly	Loiasis	-	-
Rat flea ( <i>Xenopsylla cheopis</i> )	<i>Hymenolepis diminuta</i> and <i>Hymenolepis nana</i>	-	Bubonic plague Endemic typhus
Cockroach (mechanical vector)	Amoebiasis Helminthiasis	Hepatitis Poliomyelitis	Enteric pathogens
Reduviid bug	Chagas' disease	-	-
Louse	Ectoparasitic infection	-	Relapsing fever Epidemic typhus Trench fever
Hard tick	Babesiosis	Viral encephalitis Viral fever Viral hemorrhagic fever	Tularemia Tick typhus
Soft tick	-	-	Q-fever Relapsing fever
Trombiculid Mite	-	-	Scrub typhus Rickettsial pox
Itch mite	Scabies	-	-
<i>Cyclops</i>	Dracunculiasis Diphyllbothriasis Gnathostomiasis	-	-
Crabs and crayfish	Paragonimiasis	-	-

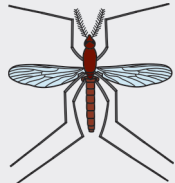





in males). The proboscis is used by the mosquito for biting during the feed

- **Thorax:** It is large and rounded. It bears a pair of wings dorsally and three pairs of legs ventrally
- **Abdomen:** It is long, narrow and has

ten segments. The last two segments are modified to form external genitalia.

General identification features of *Anopheles*, *Culex* and *Aedes mosquitoes* are described in Table 16.3.

**Table 16.3:** Identification features of *Anopheles*, *Culex*, and *Aedes* mosquitoes

Identification features	<i>Anopheles</i> mosquito	<i>Culex</i> mosquito	<i>Aedes</i> mosquito
General Identification features of mosquito	Present	Present	Present
Body	Body is slender and rests with an angle to the surface	Body rests parallel to the surface	Head is slightly bent downward and body shows a hunch back at rest
Wings	Have dark spots	Unspotted	Unspotted and has white markings on legs and abdomen (hence named as tiger mosquito)
Hind legs	Held outstretched	Curled up over the back	Held curled upward
Proboscis and body	Proboscis and body is in same straight line	Proboscis and body at an angle to one another	Proboscis and body at an angle to one another
Maxillary palpi	Maxillary palpi are as long as proboscis (both sexes)	Maxillary palpi are shorter than proboscis (females)	Maxillary palpi are shorter than proboscis (females)
Tip of the abdomen	-	Blunt	Pointed
Biting time	Each species has specific peak biting hours and there are also variations in their preferences for biting indoors or outdoors	Midnight	Day time
Important species	<i>A. culicifacies</i> , <i>A. fluviatilis</i> , <i>A. minimus</i> , <i>A. stephensi</i>	<i>C. fatigans</i> , <i>C. tritaeniorhynchus</i> , <i>C. tarsalis</i>	<i>A.aegypti</i>
Vector of diseases	Malaria Encephalitis	Bancroftian filariasis West Nile fever Japanese encephalitis	Yellow fever Chikungunya fever Dengue Rift Valley fever Encephalitis
Identification features	<i>Anopheles</i> mosquito	<i>Culex</i> mosquito	<i>Aedes</i> mosquito
Schematic diagram and real images of <i>Anopheles</i> , <i>Culex</i> and <i>Aedes</i> mosquitoes (Figs 16.1A and B; Figs 16.2A and B; Figs 16.3A and B) <i>Source:</i> (16.1B; 16.2B; 16.3B) DPDx Image Library, Centre for Disease Control and prevention (CDC), Atlanta ( <i>with permission</i> )	 <b>Fig. 16.1A</b>	 <b>Fig. 16.2A</b>	 <b>Fig. 16.3A</b>
	 <b>Fig. 16.1B</b>	 <b>Fig. 16.2B</b>	 <b>Fig. 16.3B</b>

## Flies

### Housefly (Fig. 16.4)

*Musca domestica* is most common house frequenting fly. It is non-biting. They act as mechanical vector for transmission of many diseases.

#### Identification features

- **Head:** It has a pair of compound eyes, a pair of antennae and a single proboscis on its head
- **Thorax:** Has pair of wings and three pairs of legs
- **Abdomen:** Segmented and shows dark and light markings (Fig. 16.4).


#### Diseases transmitted

- Enteric fever
- Diarrhea
- Intestinal helminthiasis
- Gastroenteritis
- Dysentery
- Poliomyelitis
- Anthrax
- Yaws
- Trachoma
- Enterically transmitted hepatitis.

### Sandfly (Fig. 16.5)

#### Identification features

- Light or dark brown flies, smaller than mosquitoes
- Body and wings covered by dense hair
- Head contains pair of long, slender and hairy antennae, palpi and a proboscis
- Thorax contains pair of wings and three pair of legs



**Fig. 16.4:** Housefly (schematic diagram)

- Abdomen has ten segments
- Though winged, they only hop about and do not fly
- The legs are longer as compared to the size of the body
- They bite during night and only female bite; the males live on fruit juices
- **Important species:** *Phlebotomus argentipes* (vector of kala-azar).

#### Diseases transmitted

- Kala-azar (visceral leishmaniasis)
- Sand-fly fever (Papatasi fever/3 days fever)
- Oriental sore
- Oroya fever (Carrion's disease).

### Tsetse Fly (Fig. 16.6)

- Tsetse flies occur only in tropical Africa
- They are yellowish or dark brown, medium-sized flies
- They can be distinguished from other large biting insects by their forward pointing mouthparts
- They bite only in daytime.

## Flea

### Rat Flea (Fig. 16.7)

#### Identification features

- Fleas are small, bilaterally compressed, wingless insects



**Fig. 16.5:** Sandfly (real image)

Source: Public Health Image Library, ID# 6273/Centre for Disease Control and prevention (CDC), Atlanta (with permission)



**Fig. 16.6:** Tsetse fly (real image)

Source: DPDx Image Library, Centre for Disease Control and prevention (CDC), Atlanta (with permission)



**Fig. 16.7:** Male rat flea mounted specimen

Courtesy: HOD, Dept. of Microbiology, Meenakshi Medical College, Chennai

- Important species of rat fleas are *Xenopsylla cheopis*, *X. astia*
- Contains a hard chitinous exoskeleton and their body is covered by backward pointing spines
- **Head:** Conical and attached to the thorax without neck
- **Thorax:** Contains three segments and three pairs of legs; hind legs are well developed for jumping

- Abdomen is divided into ten segments. The male contains a coiled structure, the penis, and female contains a short, stumpy structure, the spermatheca, in the abdomen. The shape of spermatheca helps in distinguishing the species.

#### **Diseases transmitted**

- Bubonic plague
- Murine typhus/endemic typhus
- Chiggerosis
- Act as intermediate host for *Hymenolepis nana* and *H. diminuta*.

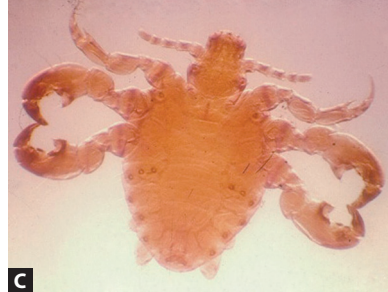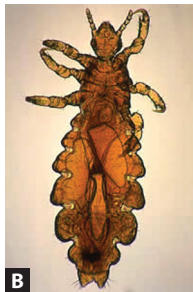#### **Louse (Fig. 16.8)**

##### **Identification features**

- Small wingless human ectoparasite
- Human lice are of three types—(1) head lice (*Pediculus humanus capitis*), (2) body lice (*P. humanus corporis*) and (3) pubic or crab lice (*Phthirus pubis*)
- **Head:** Pointed in front and contains a pair of five jointed antennae. Mouth parts are adapted for blood sucking and they bite severely
- **Thorax:** Square-shaped, with three pairs of legs attached ventrally. The legs are provided with claws
- **Abdomen:** Elongated in shape and has nine segments

#### **Diseases transmitted**

- Epidemic typhus
- Trench fever
- Epidemic relapsing fever



**Figs 16.8A to C:** Louse (mounted specimens) (A) body louse; (B) head louse; (C) pubic Louse (mounted specimen)

Source: DPDx Image Library, Centre for Disease Control and prevention (CDC), Atlanta (with permission)

## ■ CLASS ARACHNIDA

### Mites

#### *Trombiculid Mite (Fig. 16.9)*

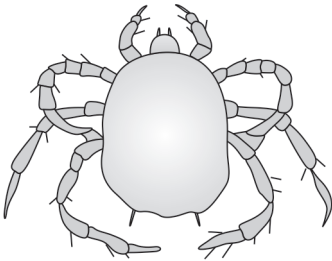
##### **Identification features**

- It contains four pairs of legs (first pair of legs is the largest)
- The body is not well demarcated into three parts (head, thorax and abdomen)
- Disease transmitted—scrub typhus

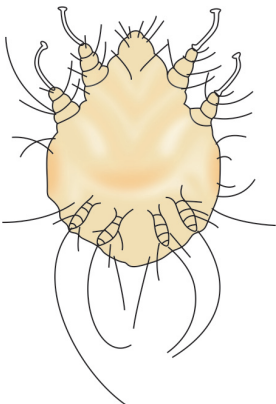
#### *Itch Mite/Sarcoptes scabiei (Fig. 16.10)*

##### **Identification features**

- Very small in size, just visible to naked eyes
- Body is rounded above and flattened below
- The body surface is covered with short bristles
- It has two pairs of legs in front, and two pairs behind



**Fig. 16.9:** Trombiculid mite (schematic diagram)



**Fig. 16.10:** Itch mite (schematic diagram)

- The front legs have suckers at the end and the hind legs have long bristles
- Disease caused—scabies

### Ticks

#### *Hard Tick (Ixodid Tick) (Fig. 16.11)*

##### **Identification features**

- A hard, chitinous shield (scutum) covers the dorsum
- Body cannot be distinctly separated into head, thorax and abdomen
- They have four pairs of legs, no antennae
- When viewed from above its head is visible
- They are dark/bright colored
- Both sexes suck blood and feed both day and night, cannot withstand starvation
- Medically important species:
  - *Haemaphysalis species*
  - *Amblyomma species*.

##### **Diseases transmitted**

- Viral encephalitis
- Kyasanur forest disease
- Tick typhus
- Tularemia
- Q fever
- Human babesiosis

#### *Soft Tick (Argasid Tick) (Fig. 16.12)*

##### **Identification features**

- Medically important species *Ornithodoros species*



**Fig. 16.11:** Female hard tick (*Amblyomma species*)  
real image

Source: DPDx Image Library, Centre for Disease Control and prevention (CDC), Atlanta (with permission)





**Fig. 16.12:** Dorsal and ventral view of soft tick (real image)

Source: DPDx Image Library, Centre for Disease Control and prevention (CDC), Atlanta (with permission)

- Length of adult soft tick 5 mm
- They are oval in shape
- They have four pairs of short legs
- When viewed from above head is not visible
- They can survive without blood meals for long periods
- Both sexes suck blood
- They bite only at night time and their bite is very painful.

#### **Diseases transmitted**

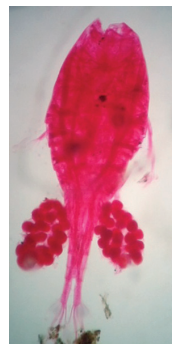- Tick borne relapsing fever/endemic relapsing fever
- **Q fever:** Soft ticks act as reservoir for *Coxiella burnetii* due to trans-ovarial transmission of *Coxiella*.

## ■ CLASS CRUSTACEA

### **Cyclops (Fig.16.13)**

#### **Identification Features**

- Also called as **water fleas**
- They measure less than 1mm in length and pear shaped
- Their tail is forked
- They have two pairs of antennae, five pairs of legs and a pigmented eye
- They swim in water with typical jerky movements.



**Fig. 16.13:** *Cyclops* (mounted specimen)

Source: HOD, Dept. of Microbiology, Meenakshi Medical College, Chennai (with permission)

#### **Diseases Transmitted**

- Dracunculiasis
- Diphyllbothriasis
- Gnathostomiasis.

## ■ CONTROL OF ARTHROPODS

### **Physical Control Methods**

- Proper disposal of sewage, garbage, manure and elimination of stagnant water
- Use of door and window screens and bed nets.

### **Biological Control Methods**

- Use of specific viruses, bacteria, protozoa, fungi which are pathogenic to various morphological forms of arthropods
- Use of Gambusia fish that feed on larvae of mosquitoes.
- Barbell fish and Gambusia fish have been successfully used for control of *Cyclops*.

### **Chemical Control**

Use of insecticides like dichlorophenyl-trichloroethane (DDT), baygon and pyrethrum flowers, and arsenical compounds.

### EXPECTED QUESTIONS

#### I. Differentiate between:

- (a) *Anopheles* mosquito and *Culex* mosquito
- (b) Hard tick and soft tick

#### II. Multiple choice questions (MCQs):

##### 1. Mosquito acts as vector for transmission of all the parasitic infections except:

- (a) Malaria
- (b) Bancroftian filariasis
- (c) Malayan filariasis
- (d) Leishmaniasis

##### 2. House fly acts as mechanical vector for transmission of all the following infections except:

- (a) Amoebiasis
- (b) Typhoid and paratyphoid fever
- (c) Malaria
- (d) Cholera

##### 3. Rat flea acts as vector for transmission for which of the following parasitic infection:

- (a) *Paragonimus westermani*
- (b) *Hymenolepis diminuta*
- (c) *Echinococcus granulosus*
- (d) *Diphyllbothrium latum*

##### 4. Hard tick acts as vector for transmission for which of the following parasitic infection:

- (a) Babesiosis
- (b) Diphyllbothriasis
- (c) Dracunculiasis
- (d) Leishmaniasis

##### 5. *Cyclops* acts as vector for transmission for all the following parasitic infections except:

- (a) Diphyllbothriasis
- (b) Dracunculiasis
- (c) Gnathostomiasis
- (d) Malaria

#### Answer

1. (d)    2. (c)    3. (b)    4. (a)    5. (d)



# Appendices

---

- Appendix I** Clinical syndromes in parasitology
- Appendix II** Common tropical parasitic diseases
- Appendix III** Romanowsky stains, composition and staining procedures
- Appendix IV** Laboratory-acquired parasitic infections
- Appendix V** Biomedical waste management in parasitology
- Appendix VI** Morphological forms of parasites seen in the fecal sample



## CLINICAL SYNDROMES IN PARASITOLOGY

### Symptomatology

Symptoms	Protozoa	Helminths		
		Cestodes	Trematodes	Nematodes
Diarrhea	<i>Entamoeba histolytica</i>	<i>Taenia solium</i>	<i>Fasciolopsis buski</i>	<i>Trichinella spiralis</i>
	<i>Giardia lamblia</i> (frothy stool)	<i>Taenia saginata</i>	<i>Clonorchis sinensis</i>	<i>Trichuris trichiura</i>
	<i>Cryptosporidium parvum</i>	<i>Taenia saginata asiatica</i>	<i>Paragonimus westermani</i>	<i>Strongyloides stercoralis</i>
	<i>Cyclospora cayentanensis</i>		<i>Heterophyes heterophyes</i>	<i>Ancylostoma duodenale</i>
	<i>Isospora belli</i>		<i>Metagonimus yokogawai</i>	<i>Necator americanus</i>
Dysentery	<i>Entamoeba histolytica</i> <i>Balantidium coli</i>		<i>Schistosoma japonicum</i> <i>Schistosoma mansoni</i>	<i>Capillaria philippinensis</i> <i>Trichostrongylus</i> spp.
Anemia	<i>Plasmodium</i> spp. <i>Babesia microti</i> <i>Leishmania donovani</i>	<i>Diphylobothrium latum</i>	<i>Schistosoma haematobium</i>	<i>Trichuris trichiura</i>
Eye infection	<i>Acanthamoeba</i> spp. <i>Trypanosoma cruzi</i> <i>Toxoplasma gondii</i> <i>Nosema</i> spp. <i>Encephalitozoon</i> spp. <i>Vittaforma corneae</i>	<i>Taenia solium</i> <i>Echinococcus granulosus</i>		<i>Ancylostoma duodenale</i> <i>Necator americanus</i> <i>Trichuris trichiura</i>
CNS infection	<i>Entamoeba histolytica</i> <i>Naegleria fowleri</i> <i>Acanthamoeba</i> spp. <i>Balamuthia mandrillaris</i> <i>Plasmodium falciparum</i> <i>Toxoplasma gondii</i> <i>Trypanosoma brucei gambiense</i> <i>Trypanosoma brucei rhodesiense</i> <i>Trypanosoma cruzi</i> <i>Microsporidia</i>	<i>Taenia solium</i> <i>Spirometra</i> spp. <i>Taenia multiceps</i> <i>Echinococcus granulosus</i> <i>Echinococcus multilocularis</i> <i>Echinococcus vogeli</i>	<i>Schistosoma japonicum</i> <i>Paragonimus westermani</i>	<i>Onchocerca volvulus</i> <i>Toxocara</i> spp. <i>Dirofilaria conjunctivae</i> <i>Loa loa</i>
				<i>Trichinella spiralis</i> <i>Angiostrongylus cantonensis</i> <i>Gnathostoma spinigerum</i> <i>Strongyloides stercoralis</i> <i>Toxocara canis</i> <i>Toxocara cati</i> <i>Loa loa</i>



Contd...

Symptoms		Protozoa	Helminths		
			Cestodes	Trematodes	Nematodes
Malignancy				<i>Schistosoma haematobium</i> <i>Clonorchis sinensis</i> <i>Opisthorchis viverrini</i>	
skin and sub-cutaneous infections		<i>Entamoeba histolytica</i> (amoebiasis cutis) <i>Leishmania</i> spp.(dermal leishmaniasis and PKDL) <i>Trypanosoma brucei</i> <i>Trypanosoma cruzi</i>	<i>Taenia solium</i> (sc nodules) <i>Multiceps multiceps</i> (sc nodules)	<i>Schistosoma</i> spp.(Cercarial dermatitis)	Agents of cutaneous larva migrans (creeping eruption) Hook worm (ground itch) <i>Strongyloides stercoralis</i> (larva currens) <i>Onchocerca volvulus</i> (Onchocercoma) <i>Loa loa</i> (Calabar swelling) <i>Dracunculus medinensis</i> (blisters) <i>Mansonella streptocerca</i> <i>Mansonella ozzardi</i>
Opportunistic infections in AIDS patients		<i>Toxoplasma gondii</i> <i>Cryptosporidium parvum</i> <i>Isospora belli</i> <i>Microsporidia</i> <i>Entamoeba histolytica</i> <i>Giardia lamblia</i> Free- living amoebae <i>Cyclospora cayentanensis</i> <i>Leishmania</i> spp.(co-infection)			<i>Strongyloides stercoralis</i> (co-infection)

Abbreviations: CNS, central nervous system; SC, sub cutaneous; PKDL, Post Kala azar dermal leishmaniasis; AIDS, acquired immuno deficiency syndrome

## APPENDIX II

### COMMON TROPICAL PARASITIC DISEASES

Food and water borne	Soil transmitted	Vector borne
<i>Entamoeba histolytica</i>	<i>Ascaris lumbricoides</i>	<i>Plasmodium</i> spp.
<i>Giardia lamblia</i>	<i>Ancylostoma duodenale</i>	<i>Leishmania donovani</i>
<i>Cryptosporidium parvum</i>	<i>Ancylostoma braziliense</i>	<i>Wuchereria bancrofti</i>
<i>Isospora belli</i>	<i>Ancylostoma caninum</i>	<i>Brugia malayi</i>
<i>Cyclospora cayetanensis</i>	<i>Trichuris trichiura</i>	<i>Onchocerca volvulus</i>
	<i>Strongyloides stercoralis</i>	<i>Trypanosoma brucei</i>
		<i>Trypanosoma cruzi</i>

### OPPORTUNISTIC PARASITIC DISEASES

Immunocompromised hosts [e.g. human immunodeficiency virus (HIV) infected patients] are more prone to get a number of opportunistic parasitic infections. Both HIV and opportunistic parasites affect each other's pathogenesis.

## APPENDIX III

### ROMANOWSKY STAINS, COMPOSITION AND STAINING PROCEDURES

#### Geimsa Stain

##### Composition

- Giemsa stain powder 0.75 g
- Methanol (pure) 75 mL
- Glycerol 25 mL

##### Staining Procedure

##### For thin blood smears

- Fix the smear in methyl alcohol for 2 minutes
- Allow slides to dry in air

- Stain with Geimsa working solution (dilute the Geimsa stain in 1:10 buffered distilled water) for 30 minutes
- Wash in phosphate buffer or tap water and air dry.

##### For thick blood smears

- Slide is not fixed with methanol
- Other steps are same as that for staining a thin smear.

#### Jaswant-Singh-Bhattacharya (JSB) Stain

Jaswant-Singh-Bhattacharya stain is a rapid Romanowsky's staining method for malarial parasites. This is the standard method used by the laboratories under the National Malaria Eradication Programme in India.

##### Composition of JSB stain

##### Solution I

Methylene blue	0.5 g
Potassium dichromate	0.5 g
Sulphuric acid (1% by volume)	3 mL
Potassium hydroxide (1%)	10 mL
Water	500 mL

##### Solution II

Eosin	1 g
Water	500 mL

### Staining procedure

#### For thin blood smears

- Immerse the slide in methanol for 2 minutes to fix the smear
- Air-dry the smear
- Immerse the slide in solution I for 30 sec
- Wash the slide in a jar containing water (pH 6.2–6.6)
- Immerse the slide in solution II for 1 second
- Wash the slide in a jar containing water (pH 6.2–6.6) for 4 seconds
- Immerse the slide in solution I again for 30 seconds
- Wash as above till smear gives a pink background
- Dry and examine

#### For thick blood smears

- Smear is not fixed with methanol
- Other steps are same as that for staining a thin smear.

### Field's Stain

This is a quick method of staining of malarial parasite in thick films (without fixation).

#### Composition of the Field's Stain

##### Solution A:

Methylene blue	0.4 g
Azure 1	0.25 g
Buffered water	it is solution B (250 mL)

##### Solution B:

$\text{Na}_2\text{HPO}_4 \cdot 12\text{H}_2\text{O}$	25.2 g
$\text{KH}_2\text{PO}_4$	12.5 g
Distilled water	1000 mL

##### Solution C:

Eosin	0.5 g
Buffered water	it is solution B (250 mL)

### Staining Method

#### For thin blood smear

- Immerse the slide in methanol for 2 minutes to fix the smear

- Dry the slide
- Immerse the slide in solution A for 1–3 seconds
- Rinse in solution B for 2–3 seconds
- Dip the slide in solution C for 1–3 seconds
- Air dry the slide.

#### For thick blood smear

- Smear is not fixed with methanol
- Other steps are same as that for staining a thin smear.

### Leishman's Stain

#### Composition

Leishman's stain (powder)	150 mg
Methanol (pure)	100 ml

Dissolve; keep the stain in glass-stoppered brown bottle. Keep the stain in sunlight or in an incubator (37°C) for 1 hour for 3 days for maturation of the stain.

### Staining Procedure

#### For thin blood smear

- Cover the thin smear with the stain for 2 minutes; about 10 drops of stain
- Add double the volume (20 drops) of distilled water and mix by gently rocking the slide
- Allow to act for 15 minutes
- Wash with buffered distilled water
- Dry in air.

#### For thick blood smear

- Thick blood smear should be dehemoglobinized before staining, by immersing slide in the water until red color disappears
- Other steps are same as that for staining a thin smear.

### Wright's Stain

#### Composition

Wright's stain (powder)	0.2 g
Methanol (pure)	100 mL

Dissolve; allow maturing for a few days.

### Staining Procedure (For Thin and Thick Smear)

- Cover the slide with the stain for 2 minutes
- Now dilute the stain with buffer water, keep for 4–8 minutes
- Flood of with tap water, keep for 1 minutes
- Wipe the bottom of slide to remove excess stain
- Allow the slide to drain and air dry.

## APPENDIX IV

### LABORATORY-ACQUIRED PARASITIC INFECTIONS

Persons working in research and clinical laboratories are at risk of becoming infected with parasites through accidental exposures, which may or may not be recognized when they occur.

- Even persons who realize that they have had a laboratory accident often do not know whether they truly were exposed to organisms and what the inoculum size was
- Even persons who are experts on parasitic diseases often do not know what clinical manifestations to expect when natural modes of transmission are bypassed, how to monitor for infection after accidental exposures, and whether to begin presumptive antimicrobial therapy before infection is documented
- Because of such uncertainties and the potential severity of some parasitic diseases even in immunocompetent persons, the first reactions to laboratory accidents often are confusion and anxiety.

### Protozoan Parasites to which Laboratory Workers could be Exposed

Parasite	Routes of exposure	Infective stage
<i>Acanthamoeba</i> spp.	Wound and eye	Trophozoite and cyst
<i>Babesia</i> spp.	Needle, wound and vector	Intraerythrocytic stages and sporozoite
<i>Leishmania</i> spp.	Needle, wound, transmucosal and vector	Amastigote and promastigote
<i>Naegleria fowleri</i>	Transmucosal and aerosol	Trophozoite
<i>Plasmodium</i> spp.	Needle, wound, vector	Intraerythrocytic stages and sporozoite
<i>Toxoplasma gondii</i>	Oral, needle, wound and transmucosal	Oocyst, tachyzoite and bradyzoite
<i>Trypanosoma cruzi</i> and <i>T. brucei</i>	Needle, wound, transmucosal and vector	Trypomastigote
<i>Cryptosporidium</i> , <i>Isospora belli</i> and <i>Cyclospora</i>	Oral and transmucosal	Oocyst
<i>Entamoeba histolytica</i> and <i>Giardia lamblia</i>	Oral	Cyst

Helminthic Parasites to which Laboratory Workers could be Exposed

Parasite	Routes of exposure	Infective stage
<i>Ascaris</i> , <i>Enterobius</i> , <i>Trichuris</i> & <i>H. nana</i>	Oral	Egg
<i>Fasciola hepatica</i>	Oral	Metacercaria
Hookworm & <i>Strongyloides</i>	Percutaneous	Larva
<i>Schistosoma</i> spp.	Percutaneous	Cercaria
<i>Taenia solium</i> (Cysticercosis)	Oral	Egg
<i>Trichinella spiralis</i>	Oral	Larva

Factors that affect whether Infection and Disease Result from Accidental Exposures to Parasites

- Factors related to the accident:
  - Route and characteristics of exposure
  - Inoculum size
- Factors related to the parasite:
  - Pathogenicity, virulence, and viability of the species and isolate
  - Infective dose
- Factors related to the workers:
  - Immune status in general and with respect to the parasite
- Actions taken after accident:
  - Wound care
  - Presumptive antimicrobial therapy.

Measures taken Following Exposure

- After accidental exposures to parasites, the exposed persons should be monitored for clinical and laboratory evidence of infection
- Whether clinical manifestations or positive laboratory tests are noted first depends on such factors as the virulence of the parasite, which may have diminished during repeated passage in laboratory animals; the person's degree of self-awareness; the frequency of physical examination; and the type of laboratory testing
- Although parasitic infections usually are diagnosed by conventional microbiological methods, laboratorians in research settings often have access to investigational molecular methods, such as polymerase

chain reaction (PCR), which may facilitate early diagnosis

- Appropriate antiparasitic drugs should be given.

APPENDIX V

BIOMEDICAL WASTE MANAGEMENT IN PARASITOLOGY

Hospitals generate waste which is chemically hazardous, infectious and often radioactive. Such waste because of inappropriate disposal/treatment strategies contributes to serious health hazards in the community. The Ministry of Environment and Forests has also issued rules on the categorization of biomedical waste in 1997-98. The implementation of the above could mitigate the ill effects of the exponentially increasing problem of bio-medical waste in India.

World health organization (WHO) has recommended that hospitals in developing countries use a simplified classification for practical purposes:

- General non-hazardous waste
- Non-infectious waste
- Chemical and pharmaceutical waste
- Infectious waste
- Other hazardous medical waste.

Biomedical Waste Management Requires

- Segregation of the hospital wastes according to the available disposal technology
- Employment of cost-effective and available relevant technology

- Possibilities of recycling to be explored in a scientific and hygienic manner for permissible items
- Setting up of common medical waste treatment facilities by different hospitals such as transportation of the hazardous waste to the common disposal system to reduce expenditure
- Safety of medical staffs by the use of gloves and masks and housekeeping aspects (drinking water, sewage system of the hospitals, etc)
- Implementation of recycling etiquette by medical and paramedical personnel.

The management of biomedical wastes poses a great challenge to the policy planners, city administrators, medical personnel and workers in the recycling industry. There is a need for adopting a cost-effective system for providing better medical waste treatment facilities and reduce the amount of waste generation by awareness and education of all concerned.

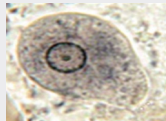

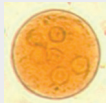

### Parasites that can be Present in Hospital Generated Biomedical Waste

Organism	Disease caused	Related waste item
<i>Giardia lamblia</i>	Giardiasis	Human excreta, blood and body fluids in poorly managed sewage system of hospitals
<i>Leishmania</i>	Cutaneous leishmaniasis and Kala Azar	
<i>Wucheraria bancrofti</i>	Filaria	
<i>Plasmodium</i>	Malaria	

## APPENDIX VI

### MORPHOLOGICAL FORMS OF PARASITES SEEN IN THE FECAL SAMPLE

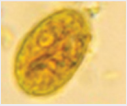
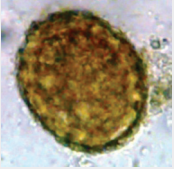

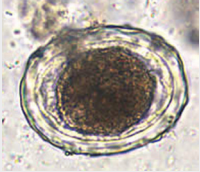
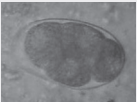

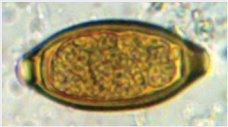
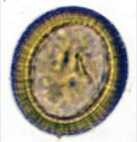

#### Salient features of Common Trophozoites, Cysts and Eggs of Parasites

Cyst/egg/trophozoite	Features	
<i>Entamoeba histolytica</i> trophozoite	15–20 µm, motile, single spherical nucleus, central karyosome, delicate and evenly distributed chromatin	
<i>Entamoeba histolytica</i> cyst	Spherical, 12–15 µm, mature cyst has four nuclei with compact centrally located karyosome; peripheral chromatin is fine and thin. Immature cysts have chromatid bars and glycogen vacuole	
<i>Entamoeba coli</i> cyst	15–25 µm, spherical, mature cyst may contain eight nuclei. Peripheral chromatin is coarse and granular; unevenly distributed in clumps; karyosome is usually eccentric	
<i>Giardia lamblia</i> trophozoite	10–20 µm in length and 5–15 µm in width, pear shaped with tapering ends, with falling leaf like motility, two centrally placed nuclei, two adhesive disks and four pairs of flagella	

Contd...

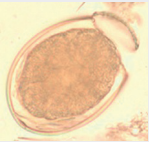

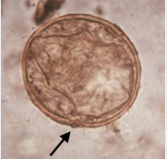



Contd...

Cyst/egg/trophozoite	Features	
<i>Giardia lamblia</i> cyst	Oval, 11–14 $\mu\text{m}$ in length and 7–10 $\mu\text{m}$ in width, four nuclei and remnants of axonemes present	
Fertilized egg of <i>Ascaris lumbricoides</i>	Round or ovoid, 50–70 $\mu\text{m}$ $\times$ 40–50 $\mu\text{m}$ Thick shell-covered by a thick aluminous coat, crescentic space at poles, bile stained (brown in color)	
Unfertilized egg of <i>Ascaris lumbricoides</i>	90 $\mu\text{m}$ $\times$ 45 $\mu\text{m}$ , elongated, shell is often thin, internal material is a mass of refractile globules	
Decorticated egg of <i>Ascaris lumbricoides</i>	Albuminous coat is lost. All other features are same as in fertilized egg	
Hookworm egg	Oval, 60 $\times$ 40 $\mu\text{m}$ . Non bile stained (colorless), segmented ovum (four blastomeres), empty space is present between shell and blastomeres	
<i>Enterobius vermicularis</i> egg	Planoconvex, elongated, 50–60 $\mu\text{m}$ long $\times$ 20–30 $\mu\text{m}$ wide, contains fully developed larva, non bile stained.	
<i>Trichuris trichiura</i> egg	Elongate, barrel shaped, size 50–54 $\mu\text{m}$ $\times$ 22–23 $\mu\text{m}$ mucus plug present at poles, contains unembryonated egg	
<i>Taenia</i> egg	Spherical, 30–40 $\mu\text{m}$ size with thick shell lined by prominent radial striations. Embryonated oncosphere possesses three pairs of hooklets	
<i>Hymenolepis nana</i> egg	Round to slightly oval, 30–47 $\mu\text{m}$ size, lined by two membranes, polar filaments present, non bile stained	

Contd...

Contd...

<b>Cyst/egg/trophozoite</b>	<b>Features</b>	
<i>Diphyllbothrium latum</i> egg	Oval, size 70 $\mu\text{m}$ length and 50 $\mu\text{m}$ width and operculated	
<i>Schistosoma mansoni</i> egg	Non-operculated measures 110–175 $\mu\text{m}$ $\times$ 45–70 $\mu\text{m}$ has characteristic lateral spine	
<i>Schistosoma japonicum</i> egg	Smaller (70–100 $\mu\text{m}$ length $\times$ 50–70 $\mu\text{m}$ width) more spherical has rudimentary lateral spine	
<i>Fasciolopsis buski</i> egg	Large (130–140 $\mu\text{m}$ $\times$ 80–85 $\mu\text{m}$ size), operculated bile stained eggs	
Note: All the figures in the tables are acknowledged in the respective chapters.		



# INDEX

---

## A

Aberrant  
    parasite 4  
    sparganosis 164  
Acanthopodia 44  
Accidental parasite 4  
Acid fast  
    stain, modified 144, 297  
    staining 130  
Acquired immunity 9  
Acute schistosomiasis 196  
Adaptive immunity 9  
Aedes 267  
Agar plate  
    culture 306  
    technique 236, 241  
Albendazole 14, 175, 183, 236, 246, 273  
Algid malaria 100  
Allergic manifestations of parasitic diseases 7  
Amastigote form 63  
Amoebapore 29  
Amoebic  
    dysentery 31  
    keratitis 44  
    liver abscess 30  
    ulcer 28  
Amoeboma 29, 31  
Amoebostome 42  
Amplifier host 4  
Anchovy sauce pus 30  
Ancylostoma duodenale 230, 232  
Angiostrongylus 252  
Animal inoculation methods in parasitic diagnosis 311  
Anisakiasis 253  
Anisakis simplex 253  
Anopheles 267, 316  
Antibody detection for parasitic diagnosis by  
    ELISA 307  
Antigenic

    mimicry 11  
    shedding 11  
Antigen detection for parasitic diagnosis by  
    ELISA 308  
Antimalarial drug resistance 112  
Antiparasitic drugs 11  
Armed tapeworm 166  
Ascaris  
    lumbricoides 242  
    suum 246  
Autofluorescence 132  
Autoinfection 5, 127, 169, 185, 239  
Axenic cultures 33, 303  
Axoneme 49, 63  
Axostyle 49, 63

## B

Babesia 114, 116  
    divergens 115  
    microti 115  
Bachman intradermal test 288  
Bacillary dysentery 31  
Baermannfunnel technique 236, 241, 306  
Balamuth's medium 33, 304  
Balamuthia mandrillaris 46  
Balantidium coli 146  
Bay sore 77  
Baylisascaris procyonis 253  
Benign malaria 96  
Benzimidazole 12, 36  
Black water fever 100  
Blastocystis hominis 149  
Blood Concentration techniques 297, 302  
Blood flukes 193  
Boeck and Dr Bohlav medium 33, 304  
Bradyzoites 119  
Brown-Brenn modification of Gram stain 144  
Brugia  
    malayi 274  
    timori 275

## ■ C

Calabar swelling 276  
 Canal cells 158  
*Capillaria* 255  
   *aerophila* 257  
   *hepatica* 256  
   *philippinensis* 255  
 Card agglutination test for trypanosomes 88  
 Casoni test 182  
 Cellophane tape method 229, 295  
 Cercaria 194  
 Cercarial dermatitis 199  
 Cerebral malaria 99  
 Cestodes 153  
   morphology of 157  
 Chagas' disease 82  
 Chagoma 82  
 Chandler's index 230  
 Charcoal culture 306, 236, 241  
 Charcot Leyden crystals 35, 296  
 Chiclero ulcer 77  
*Chilomastix mesnili* 58  
 Chinese liver fluke 206  
 Chloroquine 11, 13, 36, 111  
 Cholangio carcinoma 209  
 Chopra's antimony test 73  
 Chromatoid bodies 26  
 Chronic schistosomiasis 196  
 Cilia 146  
 Cirrus 158  
 Clinical syndromes in parasitology 325  
*Clonorchis sinensis* 206  
 Coccidian parasites 118  
 Coenurus 176  
 Colpitis macularis 56  
 Commensalism 4  
 Blood concentration techniques 297, 302  
 Conjugation 147  
 Contraecum species 254  
 Coproantigen 33, 563  
 Coracidium 162  
 Costa 56  
 Cryptosporidiosis 129  
*Cryptosporidium parvum* 126  
*Culex* 316  
   *quinquefasciatus* 267

Culture techniques in parasitology 303

Cutaneous

  Larva migrans 248  
   leishmaniasis 74

Cyclophyllidean cestodes 160, 165

Cyclops 282, 320

*Cyclospora cayetanensis* 131

Cysticercosis 171

*Cysticercus*

*bovis* 168  
   *cellulosae* 170

Cyotocentrifugation 302

## ■ D

D'Antoni's iodine 297

DEC patch test 280

DEC provocation test 271

Del Brutto's diagnostic criteria 174

Delhi boil, Aleppo boil and Baghdad button 75

Diamond's medium 33

*Dientamoeba fragilis* 60

Diethylcarbamazine (DEC) 14, 273, 277

Diffuse cutaneous leishmaniasis 75

Dilution egg counting method 301

*Diocotophyme renale* 258

*Diphyllbothrium* 160

*Dipylidium caninum* 187

*Dirofilaria* species 282

Disseminated strongyloidiasis 240

Dobeil's iodine 297

Dog tapeworm 176

Double pored tapeworm 187

*Dracunculus medinensis* 282

## ■ E

East African sleeping sickness 86

*Echinococcus* 176

*granulosus* 176

*multilocularis* 183

*oligarthrus* 184

*vogeli* 184

*Echinostoma ilocanum* 215

Egg counting techniques 236, 301

Encephalitozoon 140

*Endolimax nana* 39

Endoparasite 3  
 Enflagellation test 43  
*Entamoeba*  
   *coli* 36, 37  
   *dispar* 35  
   *gingivalis* 38  
   *hartmanni* 38  
   *histolytica* 24, 37  
     minuta form of 26  
   *moshkovskii* 36  
   *polecki* 39  
*Enterobius vermicularis* 227  
 Enterocytozoon 140  
*Enteromonas hominis* 59  
 Entero-test 53  
 Enzyme linked immuno transfer blot 309  
 Eosinophilic meningitis 252  
 Epimastigote form 63  
 Espundia 77  
 Exflagellation 95

## F

Facultative parasite 4  
 Falciparum malaria 97, 116  
*Fasciola*  
   *gigantica* 206  
   *hepatica* 202  
*Fasciolopsis buski* 210  
 Fecal specimen, preservation of 300  
 Feces, examination of 293  
 Field's stain 328  
 Filarial dance sign 272  
 Filarial nematode 262, 263  
 Filariasis control programme 274  
 Filariasis  
   classical/lymphatic 265, 271  
   occult 271  
 Fish tapeworm 160  
 Flame cells 158  
 Flea 317  
 Flies 317  
 Flotation techniques 299  
 Flukes 190  
 Forest yaws and uta 78  
 Formalin fixative method 300  
 Formol-ether sedimentation technique 298

Free-living amoeba 40  
 Fulminant amoebic colitis 28

## G

Gametocytes 94  
 Gametogony 94  
*Gastrodiscoides hominis* 213  
 Geimsa stain 327  
 Giant  
   intestinal fluke 210  
   kidney worm 258  
*Giardia lamblia* 50  
 Glossina 85  
 Glycogen mass 26  
*Gnathostoma* species 254  
 Granuloma cutis 30  
 Granulomatous amoebic encephalitis 44  
 Ground itch 235

## H

Hama-EITB 197  
 Hama-fast-ELISA 197  
 Hanging groin 279  
 Harada Mori filter paper method 305, 236, 241  
 Hatching test 200  
 Hemoflagellates 63  
 Hemozoin pigment 94  
*Heterophyes heterophyes* 214  
 Histidine rich protein 99  
 Hookworm 230  
 Host 4  
 Housefly 317  
 Human broad tapeworm 160  
 Hydatid cyst 177, 178  
 Hydrogenosome 56  
*Hymenolepis*  
   *diminuta* 186, 187  
   *nana* 184, 187  
 Hyperactive malarial splenomegaly 100  
 Hyperinfection syndrome 240  
*Hysterothylacium* species 254

## I

Imaging methods in parasitic diagnosis 312



Immune evasion mechanisms of parasites 11  
 Immunology of parasitic diseases 8  
 Incubation period 94  
 Innate immunity 8  
 Intermediate host 4  
 Intestinal  
     flukes 210  
     nematodes 220  
     sarcocystosis 137  
     taeniasis 170  
 Intradermal skin tests in parasitic diagnosis 311  
*Iodamoeba butschlii* 39  
 Iodine mount 296  
 Iron-hematoxylin stain 297  
 Isoenzyme analysis 34, 43  
*Isopora belli* 133  
 Itch mite 319  
 Ivermectin 14, 15, 226, 246, 273, 280

## J

James's dots 98  
 Jaswant-Singh-Bhattacharya (JSB) stain 327  
 Jones' medium 304

## K

Katayama fever 199  
 Kato's cellophane tape 301  
 Kawamoto technique 107  
 Kerandel's sign 87  
 Kinetoplast 63  
 Kinyon's cold method 297  
 Knott's concentration 302

## L

Laboratory-acquired parasitic infections 329  
*Lagochilascaris minor* 253  
 Large intestinal nematodes 224  
 Larva  
     *currens* 240  
     *migrans* 248  
 Lectin antigen 29  
 Leishman donovan (LD) bodies 71  
 Leishman's stain 328  
*Leishmania* 64

classification of 65  
*donovani* 64  
*chagasi* 78  
*mexicana* complex 77  
*braziliensis* complex 77  
*tropica* 74

Leishmaniasis  
     recidivans 75  
     with HIV co-infection 70  
 Leishmanin test 73  
 Leishmanoma 69  
 Leopard skin 278  
 Liver flukes 202  
*Loa loa* 276  
 Lobopodia 41  
 Loeffler's syndrome 245  
 Louse 318  
 Lugol's iodine 296  
 Lung fluke 215  
 Lutzomyia 77

## M

Malabsorption 52  
 Malignant tertian malaria 97  
 Maltese cross form 114  
*Mansonella*  
     *ozzardi* 281  
     *perstans* 281  
     *streptocerca* 281  
 Maurer's cleft 98  
 Mazzotti skin test 280  
 Megaloblastic anemia 163  
 Meglumine antimoniate 12, 76  
 Mehlis' gland 158  
 Melarsoprol 88  
 Membrane filtration 302  
 Meningoencephalitis 42  
 Merthiolate-iodine formalin 300  
*Metagonimus yokogawai* 214  
 Metronidazole 11, 35, 36, 55, 58, 62, 122  
 Meyers Kouwenaar syndrome 271  
 Microfilaria 266  
 Microfilariae of various filarial worms, comparison of 264  
 Microfilarial periodicity 265  
 Microsporidium 140

Mites 319  
 Monoxenic culture 303  
 Montenegro test 73, 75, 79  
 Mosquito 316  
 Mott cells 88  
 Mucocutaneous leishmaniasis 77  
*Multiceps multiceps* 175  
 Muscular sarcocystosis 137

## N

*Naegleria fowleri* 40  
 Napier's aldehyde test 73  
 National Institute of Health media 33  
*Necator americanus* 230, 232, 233  
 Nelson's medium 33  
 Nematodes 153  
     general properties of 220  
 Neoplasia 7  
 Neurocysticercosis 171  
 NIH swab 229, 295  
 NNN medium 72, 75, 305  
 Non-nutrient agar 43  
 Nosema 140  
 Nurse cells 286

## O

Obligiate parasite 4  
 Oesophagostomum 259  
*Onchocerca volvulus* 277  
 Onchocercoma 279  
 Oocyst 119, 127  
*Opisthorchis*  
     *felineus* 210  
     *viverrini* 208  
 Oriental lung fluke 215  
 Oriental sore 74  
 Oviparous 221  
 Ovoviviparous 221

## P

*Plasmodium* 91  
 Paddy field dermatitis 202  
 Page's saline 43  
*Paragonimus westermani* 215

Parasite 3  
 Parasitism 4  
 Paratenic host 4, 163  
*Pentatrichomonas hominis* 58  
 Pentavalent antimonial 76  
 Pernicious malaria 100  
 Petridish/ slant culture  
     technique 236, 241, 305  
*Phlebotomus* 66, 76  
 Pin worm 227  
*Plasmodium knowlesi* 91, 101  
 Pleistophora 140  
 Plerocercoid larva 163  
 PCR (polymerase chain reaction) in parasitic diagnosis 310  
 Polyvinyl alcohol fixative method 301  
 Polyxenic culture 33, 303  
*Porrocaecum* species 254  
 PKDL (post-kala azar dermal leishmaniasis) 69  
 Premunition or infection immunity or concomitant immunity or incomplete immunity 102  
 Prepatent period 93  
 Proceroid larva 163  
 Promastigote form 63  
 Protozoa, classification of 19  
 Pseudo hookworm 257  
 Pseudoapoptosis 161  
 Pseudophyllidean cestodes 160  
*Pseudoterranova* species 254  
 PAIR (puncture, aspiration, injection and re-aspiration) 182

## Q

Quantitative buffy coat (QBC)  
     examination 107, 271, 302  
 Quartan malarial nephropathy 100  
 Quinine 13, 111, 116

## R

Rapid diagnostic tests in malaria 108  
 Rat fleas 186, 317  
 Reduviid bugs 80  
 Reservoir host 4  
*Retortamonas intestinalis* 60  
 Ring form 93

River blindness 277  
 Robinson's medium 33, 304  
 Roll back malaria 104  
 Romana's sign 82  
 Romanowsky stains 327  
 Rostellum 166  
 RPMI 1640 medium 109,305

## ■ S

Sabin-Feldman dye test 124  
 Saline mount 296  
 Sandfly 66, 317  
 Sarcocyst 136  
 Sarcocystis 135  
 Sarcoptes scabiei 319  
 Saturated salt flotation technique 299  
 Schaudinn's fluid 300  
*Schistosoma* 193  
     *haematobium* 194  
     *intercalatum* 202  
     *japonicum* 201  
     *mansoni* 198  
     *mekongi* 202  
 Schistosomula 195  
 Schizogony 92, 94  
 Schneider's  
     drosophila medium 72,305  
 Schuffner's dots 98  
 Sedimentation technique 298, 302  
 Septicemic malaria 100  
 Serine rich *E. histolytica* protein (SREHP) 33  
 Serpiginous tracks 235  
 Sheep liver fluke 202  
 Skin snips technique 279  
 Small intestinal nematodes 230  
 Somatic nematodes 262  
 Sowda 278  
 Sparganosis 164  
 Sparganum 164  
 Spirometra 163  
 Stallion's disease 79  
 Steatorrhea 52  
 Stichosome 224  
 Stoll's method 301  
 Strobila 166

*Strongyloides*  
     *fuelleborni* 242  
     *stercoralis* 236, 237, 241  
 Subcutaneous cysticercosis 171  
 Sulfadiazine 111  
 Swimmer's itch 199  
 Swollen belly syndrome 242  
 Symbiosis 4  
 Syngamy 147

## ■ T

Tachyzoite 119  
*Taenia* 165  
     *multiceps* 175  
     *saginata* 167  
         *asiatica* 175  
     *solium* 167  
 Tapir nose 78  
*Ternidens deminutus* 259  
 Thelazia species 260  
 Thick smear 104  
 Thin smear 105  
 Thread worm 227  
 Ticks 319  
 Tissue cyst 119  
 TORCH infection 123  
 Toxocariasis 250  
*Toxoplasma*  
     *encephalitis* 122  
     *gondii* 118  
 Trachipleistophora 140  
 Trail sign 43  
 Transfusion malaria 101  
 Trematodes 153, 190  
     classification of 190  
 Triage parasite panel 33, 54  
*Triatoma infestans* 80  
*Trichinella* 285  
 Trichinellosis 285  
*Trichomonas* 55  
     *tenax* 58  
     *vaginalis* 55  
*Trichostrongylus* species 257  
 Trichrome stain 297  
     modified 144

*Trichuris trichiura* 224

Tropical

pulmonary eosinophilia 270

splenomegaly syndrome 100

Tropical parasitic disease 327

*Trypanosoma* 79

*equiperdum* 79

*evansi* 79

*lewisi* 79

*brucei gambiense* 86

*brucei rhodesiense* 86

*cruzi* 79

Trypanosomal chancre 87

Trypomastigote form 64, 80

Tsetse fly 85, 317

## ■ U

Urogenital specimen, examination of 303

## ■ V

Vaccine strategies against malaria 113

Variant

antigenic types 86

surface protein 52

Visceral

larva migrans 250

leishmaniasis 68

Vitamin B<sub>12</sub> deficiency 163

Vitelline gland 158

Vittaforma 140

Viviparous 221

## ■ W

Wakana disease 235

Wandering parasite 4

Water lily sign 181

*Watsonius watsoni* 213

Weingarten's syndrome 270

West African sleeping sickness 86

Western blot 309

Whiff test 58

Whipworm 224

Winter bottom's sign 87

WKK antigen 73

Wright's stain 328

*Wuchereria bancrofti* 265

## ■ X

Xenodiagnosis 84, 273, 311

## ■ Y

Yager's liver infusion tryptose medium 83

## ■ Z

Ziemann's dots 98

Zinc sulphate flotation concentration

technique 299

Zymodeme analysis 34